

**DATE PRESENTING CLINICAL SIGNS**

12/8/21

PATIENT

Flower Boehlert

SPECIES

Feline

BREED

DSH

SEX

Spayed Female

AGE

6/22/19

WEIGHT

6.4 Lbs.

INTERPRETED BY

Andrea Nicastro, DMV,
 Diplomate DACVIM
 (Small Animal
 Internal Medicine)

IMAGING PERFORMED BY

Andi Parkinson RDMS

HOSPITAL NAME

Paradise AH

REFERRING VET

Dr. Twardzik

INVOICE

12856

History: Owner adopted in the spring. Since then, has had waxing and waning diarrhea. Diarrhea initially improved on hydrolyzed diet, but restarted, along with inappetence, following a dentistry in the fall. On multiple exams, patient has demonstrated severe gingivitis

Current Medications: Gabapentin

Lab Results: 8/11: CBC/Chem/T4: mildly elevated phosphorus, 8/24: U/A: > 50 RBC/hpf, 10/4: > 50 RBC/hpf.

Date of Previous IntraPet Ultrasound: No previous IntraPet scans.

Sedation: Not required to complete full diagnostic ultrasound.

Stat Report: Not requested.

ULTRASONOGRAPHIC EXAMINATION OF THE ABDOMEN**Urinary System**

The urinary bladder, trigone, and pelvic urethra are normal in thickness and the mucosal surface is smooth. The bladder lumen is mildly distended with anechoic urine. No masses, inflammatory changes or calculi are observed. Ureteral papillae and visualized portion of the proximal urethra, visible to a depth of 2 cm, are normal.

The left kidney is borderline small (2.87 cm in length); with a slightly irregular shape. There is a normal 1:3 cortex to medulla ratio with minimal to mild loss of corticomedullary distinction. There is no evidence of pyelectasia, nephroliths, infarcts or hydroureter.

The right kidney is borderline small in size (2.95 cm in length); with a slightly irregular shape. There is a normal 1:3 cortex to medulla ratio with minimal to mild loss of corticomedullary distinction. There is no evidence of pyelectasia, nephroliths, infarcts or hydroureter.

Adrenal Glands

The left adrenal gland is normal size (0.29 cm width). Normal shape and glandular echogenicity. The phrenicoabdominal vein and surrounding vasculature are normal.

The region of the right adrenal gland is evaluated. No obvious pathology is observed.

Spleen

The spleen is normal in size (0.74 cm in width at the level of the hilus) with a normal capsular contour. There is appropriate echogenicity and echotexture. No focal lesions are observed. Splenic vasculature is normal.

Liver

The liver is subjectively normal in size with normal contours and structure. There is appropriate echogenicity and echotexture. No overt structural evidence of inflammatory, infiltrative, or regenerative pathology is evident. Vascular and biliary tracts are of normal volume with no evidence of congestion. No pathological hepatic lymphadenopathy observed.

The gall bladder lumen is overdistended. The conformation is bi-lobed. The wall is normal in thickness. A small amount of gravity dependent echogenic debris is observed within the lumen. The cystic and

common bile ducts are visible/tortuous but not overtly dilated. The common bile duct measures 0.25 cm in diameter. There is no obvious evidence of an intraluminal obstruction.

Gastrointestinal

The stomach and intestine are free of stasis and exhibit normal peristaltic activity. The gastric lumen is not distended. The gastric wall and pylorus are normal in thickness with a normal layering pattern. The pyloric outflow tract is patent. The small intestinal lumen is not dilated. The small intestinal wall thickness is normal with a normal layering pattern and appropriate mural detail. There is disruption in the normal 1:3 muscularis: mucosal ratio in most segments. Discreet masses are not identified. The colonic wall is normal. There is no evidence of an obstructive pattern.

Pancreas

The pancreas is visible/prominent with minimal deviation from the normal peripheral contours. The parenchyma is slightly hypoechoic relative to surrounding omental fat. No focal lesions are observed. The pancreatic duct is dilated (0.34 cm in diameter). There is evidence of peripancreatic effusion.

Free Abdomen

There is no evidence of free fluid. A few prominent mesenteric lymph nodes are visualized, the largest measuring 1.34 cm in length.

Other

A small (0.30 cm) slightly fluid filled, tubular structure is observed dorsal to the urinary bladder and is thought to represent a uterus or uterine stump.

ULTRASONOGRAPHIC FINDINGS

Primary Findings

- Bowel pattern consistent with inflammatory bowel disease with potential for emerging lymphoma.
- The pancreatic changes are suggestive of chronic pancreatitis
- The prominent abdominal lymph nodes are most consistent with reactive lymphadenitis or lymphoid hyperplasia. Neoplastic infiltration is considered less likely.

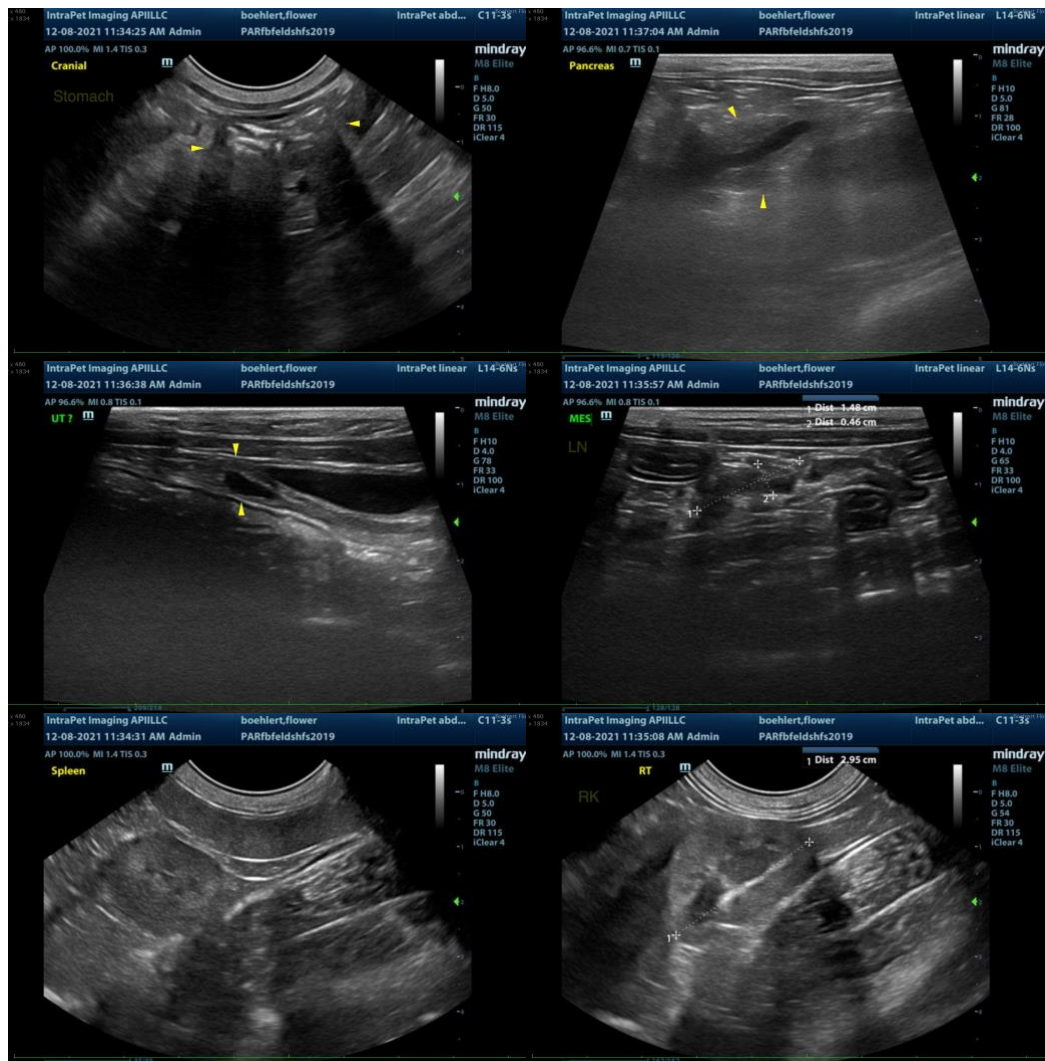
Secondary Findings

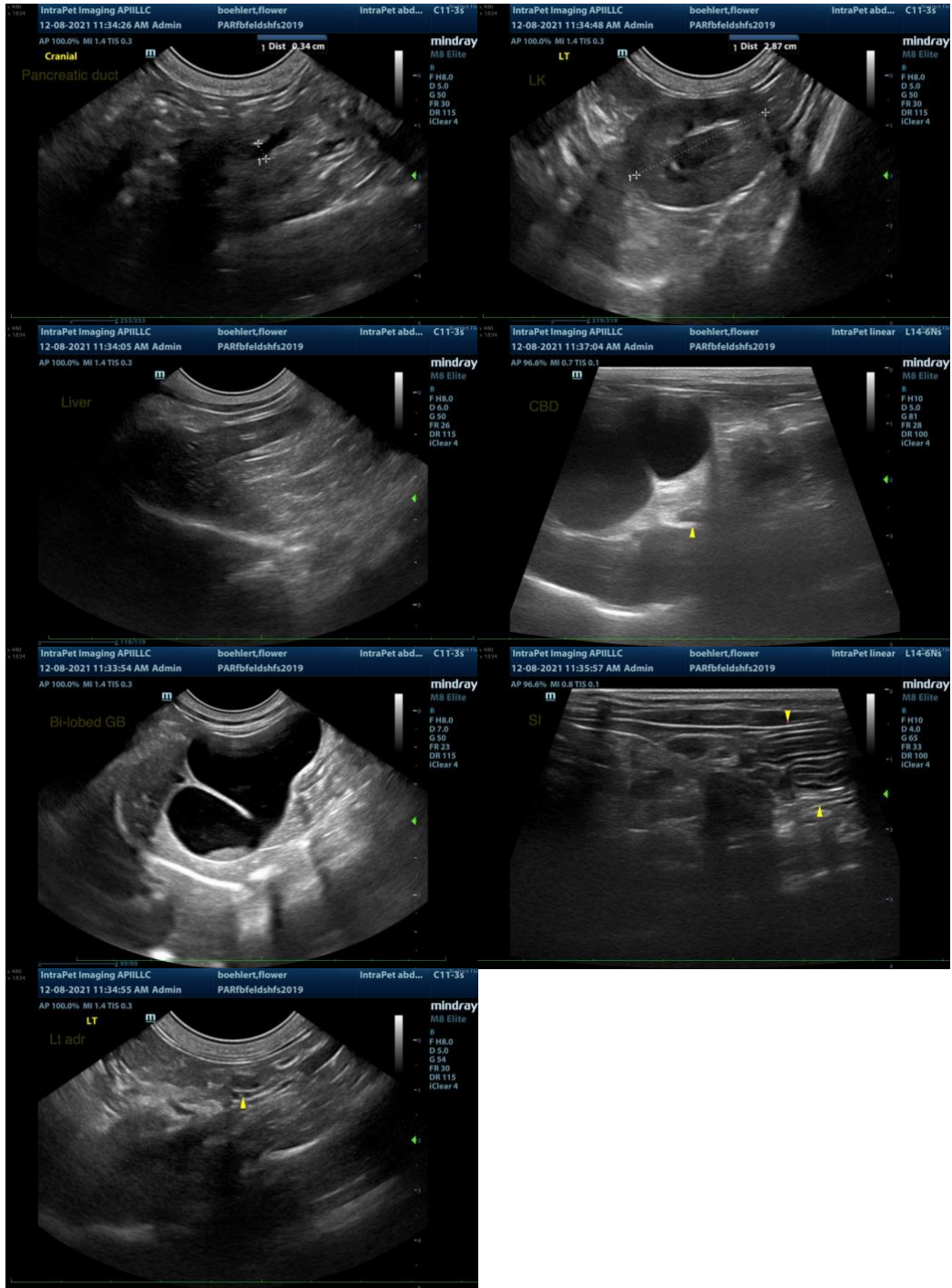
- Bilobed gallbladder- incidental
- Mild chronic non-specific renal changes
- The questionable uterine stump or uterus

INTERPRETATION OF THE FINDINGS & FURTHER RECOMMENDATIONS

- Malabsorption panel, including serum cobalamin, folate, TLI and PLI (send to Texas A & M)
- A fecal evaluation for ova/Giardia

- Prophylactic deworming with Fenbendazole at 50 mg/kg once a day for 5 days is recommended. Repeat above protocol in 3 weeks.
- Ultimately, endoscopic or surgical gastrointestinal biopsies may be necessary to get a definitive diagnosis.
- Regarding the questionable presence of a uterus, consider obtaining further history from the owners regarding ovariohysterectomy status.
- Regarding the renal changes, serial monitoring (i.e., every 4-6 months) of the patients' renal values and urine specific gravity is recommended to assess for progression. Given the recent hematuria, a urine culture and sensitivity should also be considered at this time.





The information and recommendations provided are based on the images presented by the referring veterinarian. No evaluation can be communicated regarding pathology that was not visible in the image/video clips provided.

Thank you for this referral. If the clinical or image interpretation does not parallel your findings or if I can be of any further assistance please contact me.

Andrea Nicastro, DVM, Diplomate DACVIM (Small Animal Internal Medicine)
info@SonoPath.com