

**DATE**

12/7/2021

PATIENT

Tucker Samson

SPECIES

Canine

BREED

Chihuahua mix

SEX

Male, neutered

AGE

8/10/2016

WEIGHT

15.4 lbs.

INTERPRETED BY

Andrea Nicastro, DVM,
Diplomate ACVIM
(Small Animal Internal
Medicine)

IMAGING PERFORMED BY

Rachel Brillhart RDMS

HOSPITAL NAME

Animal Emergency
Hospital

REFERRING VET

Dr. Ruby

INVOICE

12683

PRESENTING CLINICAL SIGNS

History: 12-07-2021 Presenting Complaint: Pain - On Being Handled; Crying; Diarrhea; Vomiting. Notes: Had a previous bout of Pancreatitis 10/6/2021. Owners have not been giving any table food and feeding only low-fat food and treats. Last night vomited and seemed very painful. Had some diarrhea, no blood or mucous. Hx of seizures, gets Phenobarbital 15mg bid. Vomited after meds last night. Plan: Recommend to Owner BW, Hospitalization, IV catheter, fluid therapy, US, GI meds and further treatment as needed.

Current Medications: Buprenex.

Date of Previous IntraPet Ultrasound: No previous IntraPet scans.

Sedation: Not required to complete full diagnostic ultrasound.

Stat Report: Not requested.

ULTRASONOGRAPHIC EXAMINATION OF THE ABDOMEN**Urinary System**

The urinary bladder, trigone, and pelvic urethra are normal in thickness and the mucosal surface is smooth. The bladder lumen is moderately distended with mostly anechoic urine. No masses, inflammatory changes or calculi are observed. Ureteral papillae and visualized portion of the proximal urethra, visible to a depth of 2 cm, are normal.

The prostate is normal in size (0.55 cm in width) and shape. Parenchyma is homogenous. The prostatic urethra appears normal without evidence of dilation or obstruction.

The left kidney is normal size (4.45 cm in length); normal shape and architecture with smooth peripheral margins. There is a normal 1:3 cortex to medulla ratio with normal corticomedullary distinction. There is no evidence of pyelectasia, nephroliths, infarcts or hydroureter. Renal vasculature is normal.

The right kidney is normal size (4.67 cm in length); normal shape and architecture with smooth peripheral margins. There is a normal 1:3 cortex to medulla ratio with normal corticomedullary distinction. There is no evidence of pyelectasia, nephroliths, infarcts or hydroureter. Renal vasculature is normal.

Adrenal Glands

The left adrenal gland is normal size (0.46 cm at cranial pole) (0.56 cm at caudal pole) (1.87 cm in length); normal shape; homogenous parenchyma. The glandular echogenicity and detail are unremarkable. Capsule, cortex, and medullary definition are normal. The phrenicoabdominal vein and surrounding vasculature are normal.

The right adrenal gland is normal size (0.51 cm at cranial pole) (0.46 cm at caudal pole) (2.61 cm in length); normal shape; homogenous parenchyma. The glandular echogenicity and detail are unremarkable. Capsule, cortex, and medullary definition are normal. The phrenicoabdominal vein and surrounding vasculature are normal.

Spleen

The spleen is normal in size with a normal capsular contour. There is appropriate echogenicity and echotexture. No focal lesions are observed. Splenic vasculature is normal.

Liver

The liver is subjectively prominent in size with slightly swollen peripheral contours. The parenchyma is isoechoic relative to the spleen and subtly heterogeneous in appearance. No distinct focal lesions are

observed. Vascular and biliary tracts are of normal volume with no evidence of congestion. The gall bladder lumen is moderately distended. The wall is thin and smooth. A small amount of aggregated echogenic partially dependent debris is observed within the lumen. The cystic and common bile ducts are normal/not seen.

Gastrointestinal

The gastric lumen is moderately fluid distended and hypomotile. In the region of the fundus, the gastric wall is mildly thickened (up to 0.63 cm) with prominent muscularis layer. The pyloric outflow tract is patent. The small intestinal lumen is not dilated. The small intestinal wall thickness is normal with a normal layering pattern and appropriate mural detail. Discreet masses are not identified. The wall of the proximal colon is mildly to moderately thickened (up to 0.48 cm) with questionable retention of the normal layering pattern. The wall of the descending colon is normal in thickness with a normal layering pattern and appropriate mural detail. No obstructive disease is noted.

Pancreas

The pancreas is diffusely and severely enlarged with irregular peripheral contours. The parenchyma is hypoechoic and mottled in appearance. No distinct focal lesions are observed. The pancreatic duct is not overtly dilated. Peripancreatic effusion is present. Surrounding mesentery is hyperechoic.

Free Abdomen

A small amount of free fluid is observed. The abdominal lymph nodes are normal/not visible.

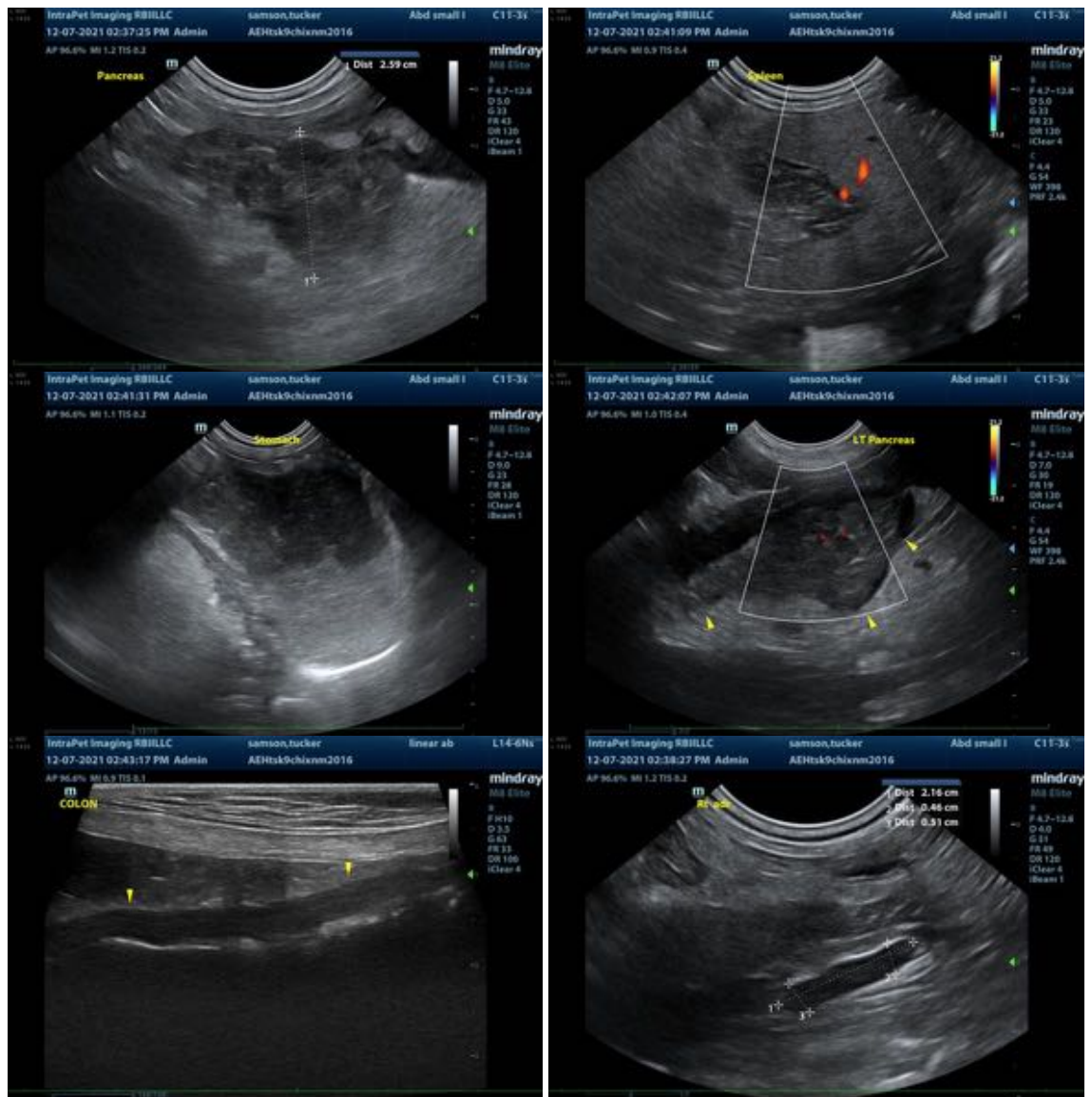
ULTRASONOGRAPHIC FINDINGS

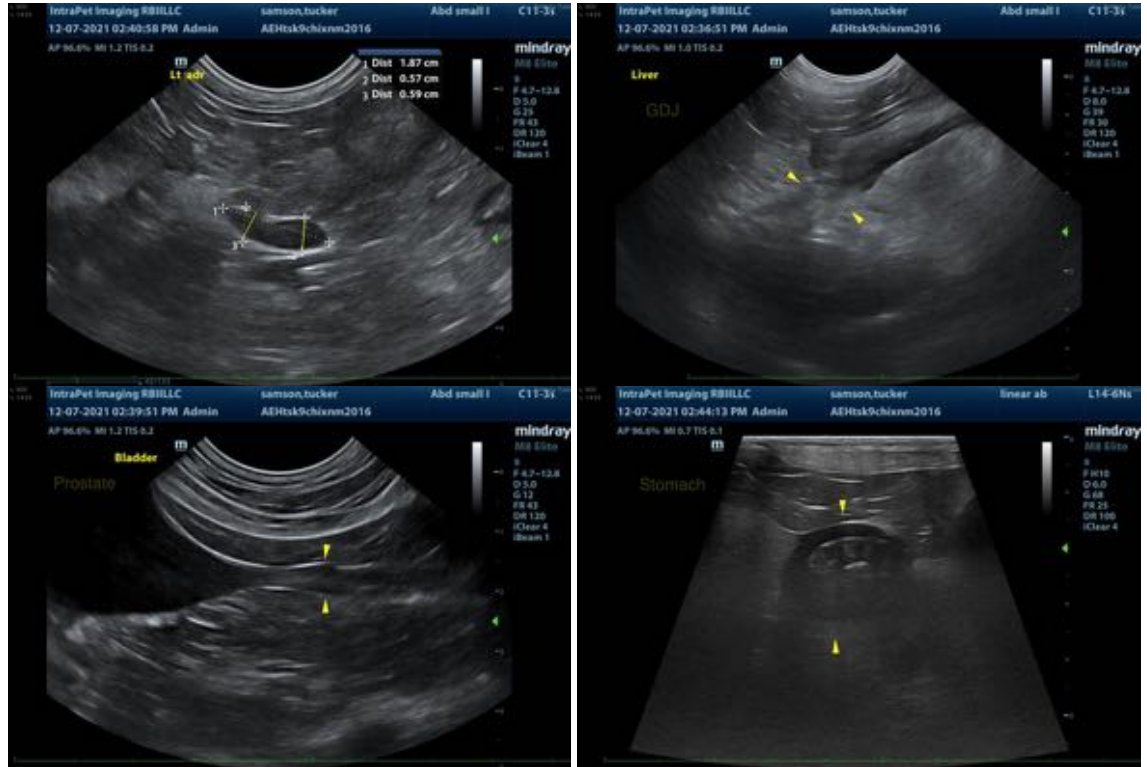
- Severe pancreatitis with regional peritonitis. There is no obvious evidence of abscessation at this time.
- The gastric and colonic wall changes are likely inflammatory and suspected to be secondary to pancreatitis. Emerging neoplasia is possible but considered less likely.
- Gastric ileus.
- The hepatic parenchymal changes are non-specific and could be secondary to inflammation, vacuolar hepatopathy, other hepatopathy or may be normal variant for this patient.

INTERPRETATION OF THE FINDINGS & FURTHER RECOMMENDATIONS

- Supportive care for pancreatitis is recommended including IV fluid therapy, gastric protectants, antiemetics, pain medication as needed, +/- fresh frozen plasma. If available, hyperbaric oxygen therapy may be beneficial in reducing pancreatic inflammation. Trickle feeding is recommended as soon as the patient will tolerate it as it can help to maintain enterocyte health.
- Three-view thoracic radiographs are recommended to assess cardiopulmonary status, as severe pancreatitis can result in pulmonary/pleural changes.

- Serial sonographic monitoring of the pancreas (i.e., every 24-48 hours) is recommended to assess for progression.
- Baseline labwork should also be monitored every 24-48 hours to assess organ function which can decline in severe cases of pancreatitis.





The information and recommendations provided are based on the images presented by the referring veterinarian. No evaluation can be communicated regarding pathology that was not visible in the image/video clips provided.

Thank you for this referral. If the clinical or image interpretation does not parallel your findings or if I can be of any further assistance please contact me.

Andrea Nicastro, DVM, Diplomate ACVIM (*Small Animal Internal Medicine*)
Andrea.nicastro@sonopath.com