



PATIENT

Spencer Shapiro

PRESENTING CLINICAL SIGNS

History: uncontrolled diabetic - check adrenals and pancreas. On insulin 7 u bid and midazolam 5 mg x 1/2 bid

SPECIES

Canine

ULTRASONOGRAPHIC EXAMINATION OF THE ABDOMEN

Urinary System

BREED

Shih Poo

The urinary bladder, trigone, and pelvic urethra are normal in thickness and the mucosal surface is smooth. The bladder lumen is moderately distended. A small amount of suspended echogenic debris is observed within the lumen. No masses, inflammatory changes or calculi are observed. Ureteral papillae and visualized portion of the proximal urethra, visible to a depth of 2 cm, are normal.

SEX

Male, neutered

The prostate is normal in size (0.76 cm in width) with a normal shape and smooth peripheral contours. The parenchyma is homogeneous. A 0.26 cm linear focus of mineralization is observed in the region of the prostatic urethra. The prostatic urethral lumen is not overtly dilated.

AGE

13 Yrs.

The left kidney is normal size (4.67 cm in length); normal shape and architecture with smooth peripheral margins. There is a normal 1:3 cortex to medulla ratio with minimal loss of corticomedullary distinction. Several non-obstructive nephroliths are visualized. A thin hyperechoic band is observed at the corticomedullary junction. There is no evidence of pyelectasia, infarcts or hydronephrosis. Renal vasculature is normal.

WEIGHT

The right kidney is normal in size (5.88 cm in length) with a normal shape, smooth peripheral margins and normal internal architecture. There is minimal loss of corticomedullary distinction. Several hyperechoic shadowing diverticular foci are observed. A hyperechoic band is observed at the corticomedullary junction. A few tiny nephroliths are visualized. There is no evidence of pyelectasia, infarcts or hydronephrosis. Renal vasculature is normal.

INTERPRETED BY

Andrea Nicastro, DVM,
Diplomate ACVIM
(Small Animal Internal
Medicine)

Adrenal Glands

The left adrenal gland is normal size (0.32 cm at cranial pole) (0.46 cm at caudal pole) (1.72 cm in length); normal shape; homogenous parenchyma. The glandular echogenicity and detail are unremarkable. Capsule, cortex, and medullary definition are normal. The phrenicoabdominal vein and surrounding vasculature are normal.

IMAGING PERFORMED BY

Diane McFadden,
RVT

The right adrenal gland is normal size (1.10 cm at cranial pole) (0.53 cm at caudal pole) (1.86 cm in length) with a slightly irregular shape. A 0.99 x 0.93 cm hyperechoic nodule is observed at the cranial aspect. The lesion causes slight expansion of the peripheral contours. Glandular echogenicity and detail at the caudal aspect are normal. The phrenicoabdominal vein and surrounding vasculature appear normal.

HOSPITAL NAME

North Warren AH

Spleen

The spleen is normal in size with a normal capsular contour. There is appropriate echogenicity and echotexture. A few myelolipomas are observed in the region of the hilus. Splenic vasculature is normal.

REFERRING VET

Dr. Corrado

Liver

The liver is subjectively normal in size with normal contours and structure. There is appropriate echogenicity and echotexture. No overt structural evidence of inflammatory, infiltrative or regenerative pathology is evident. Vascular and biliary tracts are of normal volume with no evidence of congestion. No pathological hepatic lymphadenopathy observed. The gall bladder lumen is moderately

INVOICE
12667

DATE

12/7/21



PATIENT

Spencer Shapiro

distended. The wall is normal in thickness. A moderate amount of aggregated echogenic partially dependent to suspended sludge in a slight stellate pattern is observed within the lumen. The cystic and common bile ducts are normal/not seen.

SPECIES

Canine

Gastrointestinal

The stomach and intestine are free of stasis and exhibit normal peristaltic activity. The gastric lumen is not distended. The gastric wall and pylorus are normal in thickness with a normal layering pattern. The pyloric outflow tract is patent. The small intestinal lumen is not dilated. The small intestinal wall thickness is normal with a normal layering pattern and appropriate mural detail. Discreet masses are not identified. The colonic wall is normal. No obstructive disease is noted.

BREED

Shih Poo

Pancreas

The right limb of the pancreas is visible with normal curvilinear peripheral contours. The parenchyma is largely isoechoic relative to surrounding omental fat and slightly mottled in appearance. The pancreatic duct is visible but not overtly dilated. There is no evidence of peripancreatic inflammation or effusion.

SEX

Male, neutered

AGE

13 Yrs.

Free Abdomen

The peritoneal cavity is normal. There is no evidence of inflammation or effusion. The abdominal lymph nodes are normal/not visible.

WEIGHT

ULTRASONOGRAPHIC FINDINGS

INTERPRETED BY

Andrea Nicastro, DVM,
Diplomate ACVIM
(Small Animal Internal
Medicine)

Primary Findings:

- The gallbladder changes could be consistent with a developing mucocele, cholestasis or less likely, fasting.
- The pancreatic changes are most consistent with age-related parenchymal remodeling, potentially secondary to a prior inflammatory episode, early fibrosis or chronic pancreatitis.
- The right adrenal nodule trends toward the benign (i.e., benign nodular hyperplasia) with lower potential for emerging neoplasia.

IMAGING PERFORMED BY

Diane McFadden,
RVT

Secondary Findings:

- The bilateral renal changes are consistent with a diabetic nephropathy with non-obstructive nephrolithiasis.
- Mineralization within the prostatic urethra, non-obstructive.

HOSPITAL NAME

North Warren AH

INTERPRETATION OF THE FINDINGS & FURTHER RECOMMENDATIONS

- To further investigate for causes of unregulated diabetes, consider the following:
 1. Urine culture and sensitivity.
 2. cPLI to assess for pancreatitis.
 3. Three-view thoracic radiographs to assess for occult disease in the chest.

REFERRING VET

Dr. Corrado

INVOICE

12667

DATE

12/7/21



PATIENT

Spencer Shapiro

4. Consider further testing for Cushing's disease (i.e., low dose Dexamethasone suppression test or ACTH stimulation test).

SPECIES

Canine

- Regarding the gallbladder changes, consider initiation of Ursodiol therapy. Alternatively, a repeat ultrasound can be considered in 2-3 weeks, preferably 2 hours post-meal. If gallbladder changes are similar, Ursodiol therapy can be considered at that time.

BREED

Shih Poo

SEX

Male, neutered

AGE

13 Yrs.

WEIGHT

INTERPRETED BY

Andrea Nicastro, DVM,
Diplomate ACVIM
(Small Animal Internal
Medicine)

IMAGING PERFORMED BY

Diane McFadden,
RVT

HOSPITAL NAME

North Warren AH

REFERRING VET

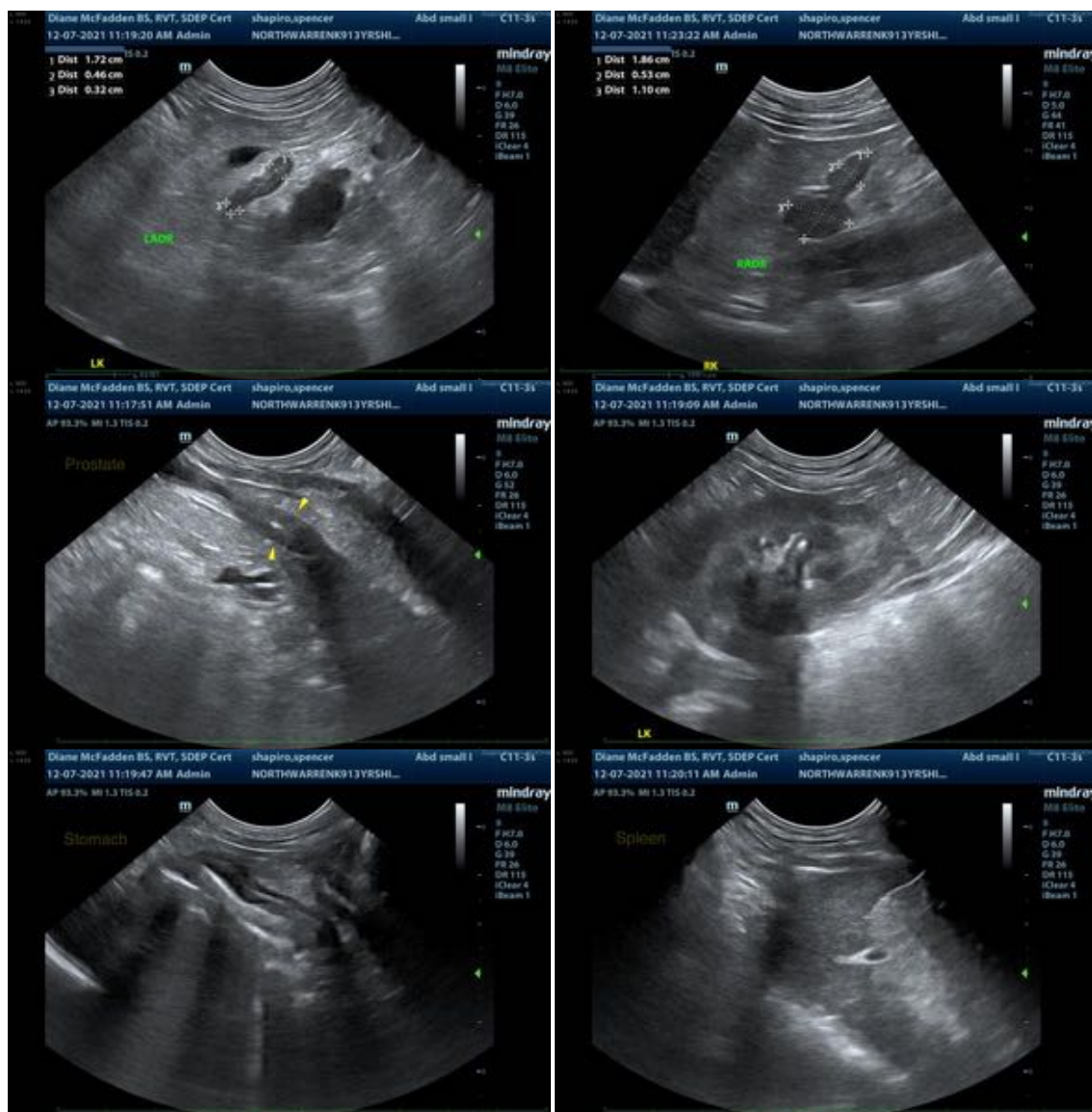
Dr. Corrado

INVOICE

12667

DATE

12/7/21





PATIENT

Spencer Shapiro

SPECIES

Canine

BREED

Shih Poo

SEX

Male, neutered

AGE

13 Yrs.

WEIGHT

INTERPRETED BY

Andrea Nicastro, DVM,
Diplomate ACVIM
(Small Animal Internal
Medicine)

**IMAGING
PERFORMED BY**

Diane McFadden,
RVT

HOSPITAL NAME

North Warren AH

REFERRING VET

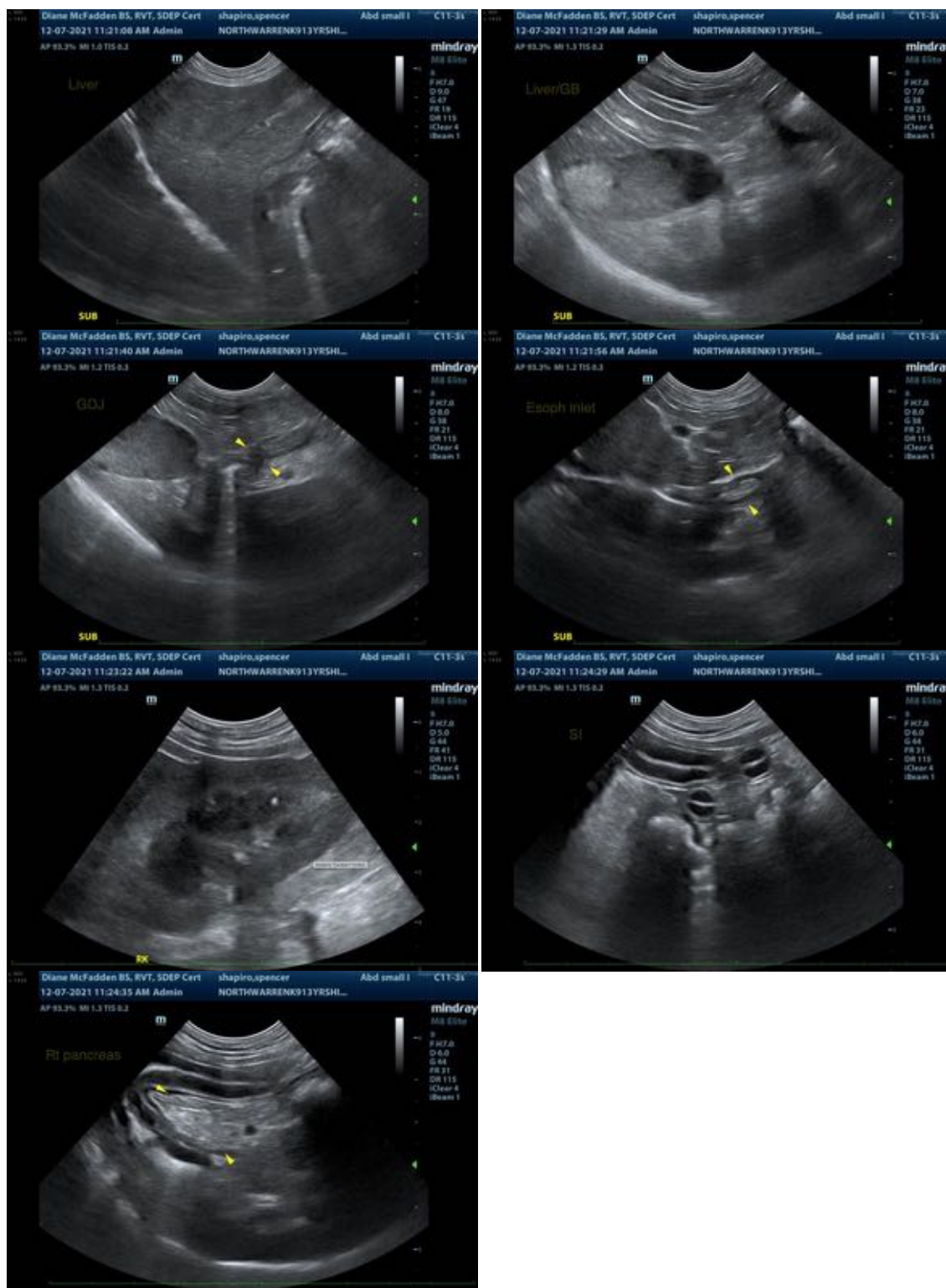
Dr. Corrado

INVOICE

12667

DATE

12/7/21



The information and recommendations provided are based on the images presented by the referring veterinarian. No evaluation can be communicated regarding pathology that was not visible in the



PATIENT

Spencer Shapiro

image/video clips provided.

Thank you for this referral. If the clinical or image interpretation does not parallel your findings or if I can be of any further assistance please contact me.

SPECIES

Canine

Andrea Nicastro, DVM, Diplomate ACVIM (*Small Animal Internal Medicine*)

andrea_nicastro2@hotmail.com

BREED

Shih Poo

SEX

Male, neutered

AGE

13 Yrs.

WEIGHT

INTERPRETED BY

Andrea Nicastro, DVM,
Diplomate ACVIM
(*Small Animal Internal
Medicine*)

**IMAGING
PERFORMED BY**

Diane McFadden,
RVT

HOSPITAL NAME

North Warren AH

REFERRING VET

Dr. Corrado

INVOICE

12667

DATE

12/7/21