

**DATE**

12/7/2021

PRESENTING CLINICAL SIGNS

History: Presenting Complaint: Gums Pale/White. Date: 12-01-2021 Notes: Acutely noted lethargy and pale no ingestions/toxins (got some turkey no onions /garlic). Assessment: IMHA vs other; discussed IMHA, discussed underlying possible causes discussed treatment with immunosuppressive medications. Plan: Start with workup full labs, pt, 4dx, x-rays, IVF, add Pred, Doxy pending workup.

PATIENT

Creed Anderson

Current Medications: Prednisone 20mg 2 tab PO BID, Doxycycline 100mg 3 caps PO SID, Cerenia 60mg 1 tab PO SID, Melatonin 3mg 2 tab PO BID, Mycophenolate Mofetil 500mg 1 tab PO BID, Famotidine 20mg 1 tab PO BID, Azathioprine 50mg 1 tab PO SID.

SPECIES

Canine

Lab Results: severe anemia, hematocrit 13% regenerative, white count 39,000 with a neutrophilia and possible left shift. Mild thrombocytopenia, T-bili 1.4, 4DX negative.

BREED

Pitbull terrier

Radiographs: Ultrasound Scan – Fluid Check (Abdominal/Thoracic/Pericardia) no free fluid in chest or abdomen found

Date of Previous IntraPet Ultrasound: No previous IntraPet scans.

Sedation: Not required to complete full diagnostic ultrasound.

Stat Report: Not requested.

SEX

Male, intact

ULTRASONOGRAPHIC EXAMINATION OF THE ABDOMEN**Urinary System**

The urinary bladder, trigone, and pelvic urethra are normal in thickness and the mucosal surface is smooth. The bladder lumen is moderately distended with anechoic urine. No masses, inflammatory changes or calculi are observed. Ureteral papillae and visualized portion of the proximal urethra, visible to a depth of 2 cm, are normal.

AGE

11/30/2017

WEIGHT

65.1 lbs.

The prostate is enlarged (3.69 cm in width) with a normal shape and smooth peripheral contours. The parenchyma is hyperechoic to slightly heterogeneous in appearance with a few tiny cystic areas. The prostatic urethra is not overtly dilated.

INTERPRETED BY

Andrea Nicastro, DVM,
Diplomate ACVIM
(Small Animal Internal
Medicine)

The left kidney is normal size (6.99 cm in length); normal shape and architecture with smooth peripheral margins. There is a normal 1:3 cortex to medulla ratio with normal corticomedullary distinction. Trace pyelectasia is present (0.21 cm in the longitudinal plane). There is no evidence of nephroliths, infarcts or hydronephrosis. Renal vasculature is normal.

IMAGING PERFORMED BY

Rachel Brillhart RDMS

The right kidney is normal size (7.84 cm in length); normal shape and architecture with smooth peripheral margins. There is a normal 1:3 cortex to medulla ratio with normal corticomedullary distinction. Trace pyelectasia is present (0.29 cm in the longitudinal plane). There is no evidence of nephroliths, infarcts or hydronephrosis. Renal vasculature is normal.

HOSPITAL NAME

Animal Emergency
Hospital

Adrenal Glands

The left adrenal gland is normal size (0.50 cm at cranial pole) (0.60 cm at caudal pole) (2.71 cm in length); normal shape; homogenous parenchyma. The glandular echogenicity and detail are unremarkable. Capsule, cortex, and medullary definition are normal. The phrenicoabdominal vein and surrounding vasculature are normal.

REFERRING VET

Dr. King

The right adrenal gland is normal size (0.62 cm at cranial pole) (0.66 cm at caudal pole) (2.59 cm in length); normal shape; homogenous parenchyma. The glandular echogenicity and detail are unremarkable. Capsule, cortex, and medullary definition are normal. The phrenicoabdominal vein and surrounding vasculature are normal.

INVOICE

12679

Spleen

The spleen is normal in size (1.69 cm in width at the level of the hilus) with a normal capsular contour. There is appropriate echogenicity and echotexture. No focal lesions are observed. Splenic vasculature is normal.

Liver

The liver is subjectively prominent in size with normal curvilinear peripheral contours. The parenchyma is hypoechoic relative to the spleen and subtly heterogeneous in appearance. No distinct focal lesions are observed. Vascular and biliary tracts are of normal volume with no evidence of congestion. The gall bladder lumen is moderately distended. The wall is thin and smooth. Luminal contents are mostly anechoic. The cystic and common bile ducts are normal/not seen.

Gastrointestinal

The gastric lumen is moderately distended with ingesta and hard shadowing material. The gastric wall and pylorus are normal in thickness with a normal layering pattern. The pyloric outflow tract is patent. The small intestinal lumen is not dilated. The small intestinal wall thickness is normal with a normal layering pattern and appropriate mural detail. Discreet masses are not identified. The colonic wall is normal. No obstructive disease is noted.

Pancreas

The right limb of the pancreas is visible with normal curvilinear peripheral contours. The parenchyma is largely isoechoic relative to surrounding omental fat and slightly mottled in appearance. The pancreatic duct is visible but not overtly dilated. There is no evidence of peripancreatic inflammation or effusion.

Free Abdomen

The peritoneal cavity is normal. There is no evidence of inflammation or effusion. A few prominent lymph nodes are observed near the aortic trifurcation, the largest measuring 1.40 cm in length.

Other

The testicles are subjectively normal in size (left testicle 3.17 x 1.75 cm; right testicle 3.54 x 2.09 cm) and symmetrical with homogeneous parenchyma. No focal lesions are observed.

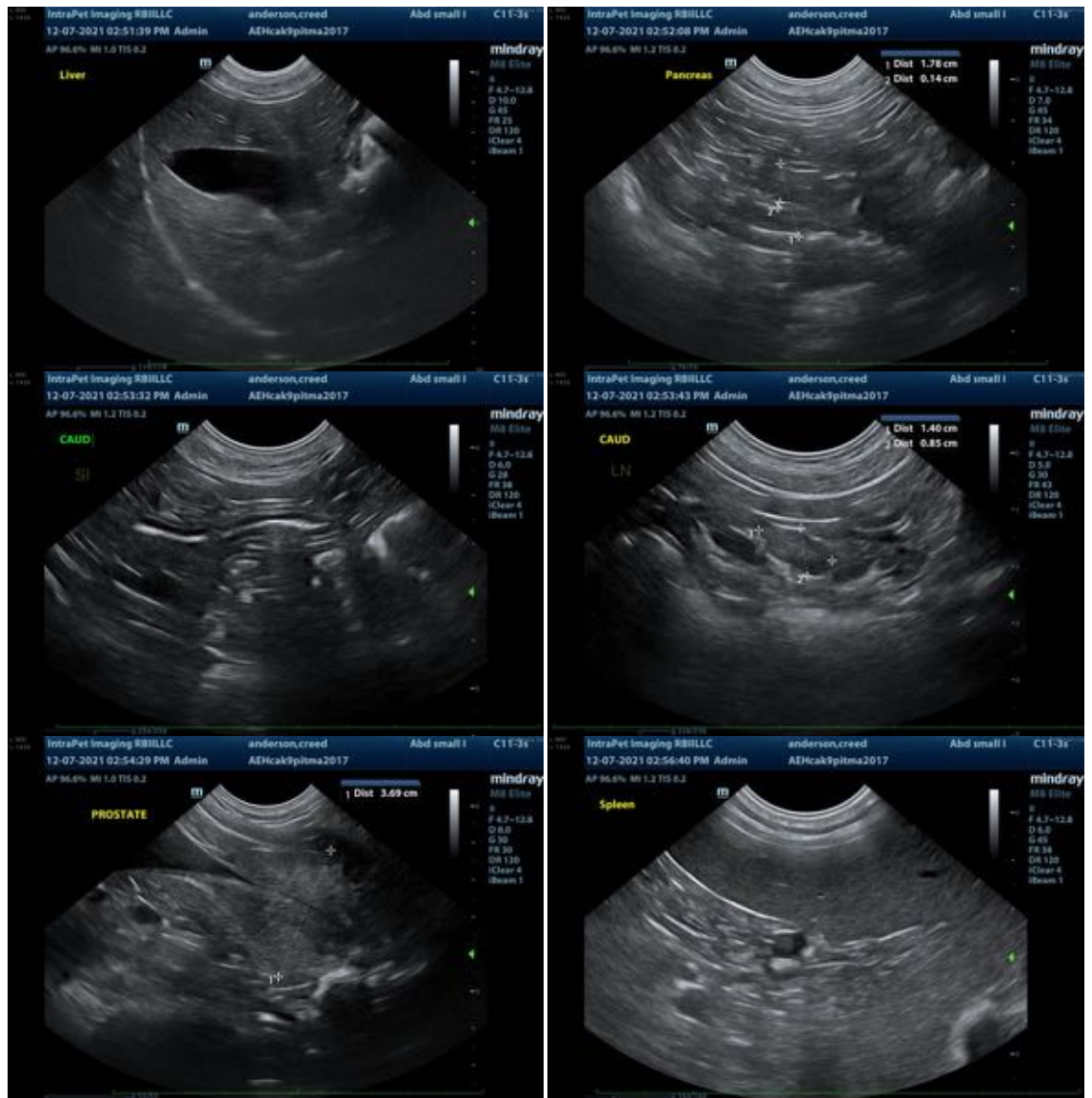
ULTRASONOGRAPHIC FINDINGS

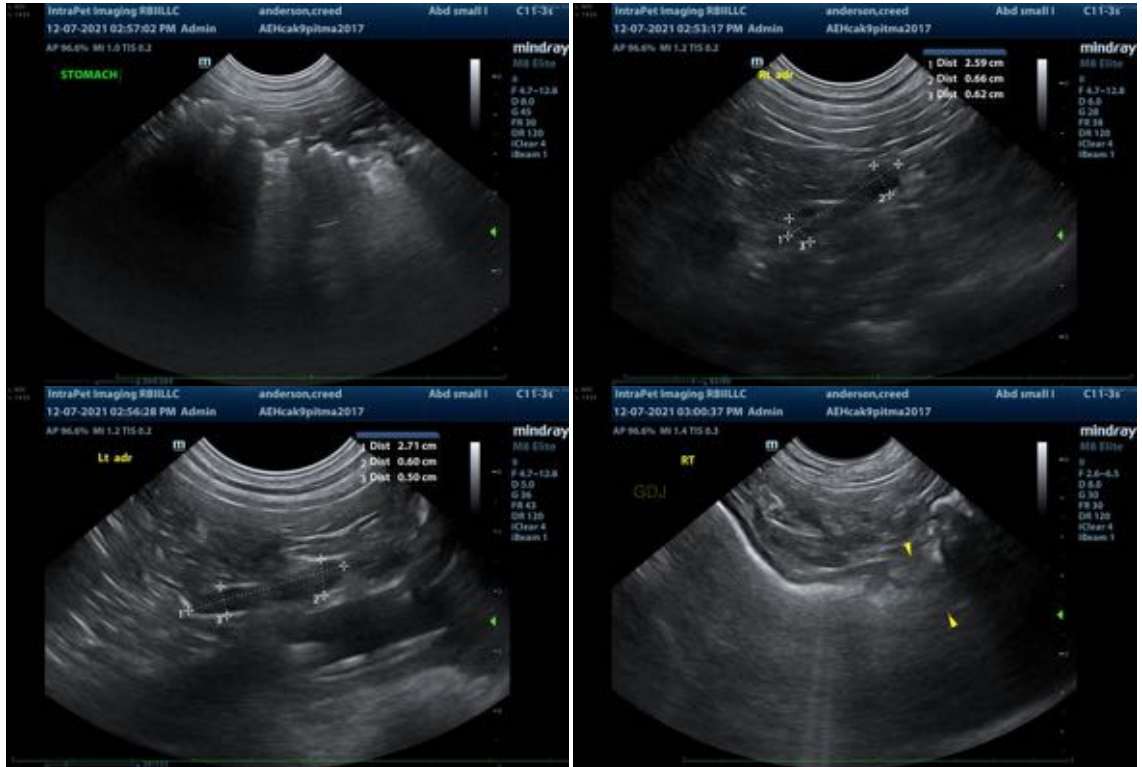
- The gastric contents may represent ingesta and/or foreign material. The presence of ingesta within the gastric lumen despite fasting suggests delayed gastric emptying.
- The lymph node changes are most consistent with reactive lymphadenitis or lymphoid hyperplasia.
- The pancreatic changes are suggestive of remodeling +/- low-grade inflammation. However, correlation with clinical findings is recommended.
- The prostate changes are most consistent with benign prostatic hyperplasia. Bacterial prostatitis is also a differential but considered unlikely in the absence of lower urinary tract signs.
- The bilateral trace pyelectasia may be secondary to IV fluid therapy, PU/PD (if applicable) or pyelonephritis.
- The hepatic parenchymal changes are non-specific and may be secondary to corticosteroid use, inflammatory disease, hypoxic change, infiltrative neoplasia (unlikely), other hepatopathy.

*There is no obvious evidence of neoplasia in the abdomen.

INTERPRETATION OF THE FINDINGS & FURTHER RECOMMENDATIONS

- Three-view thoracic radiographs are recommended to assess for occult disease in the chest, if not already performed.
- Consider a comprehensive tick panel (sent to NC State).
- Continued supportive care for immune mediated hemolytic anemia is recommended.





The information and recommendations provided are based on the images presented by the referring veterinarian. No evaluation can be communicated regarding pathology that was not visible in the image/video clips provided.

Thank you for this referral. If the clinical or image interpretation does not parallel your findings or if I can be of any further assistance please contact me.

Andrea Nicastro, DVM, Diplomate ACVIM (*Small Animal Internal Medicine*)
 Andrea.nicastro@sonopath.com