

**DATE**

12/6/22

PATIENT

Berlin Buonomo

SPECIES

Canine

BREED

Pomeranian

SEX

Female, intact

AGE

3/4/2012

WEIGHT

8.1 lbs.

INTERPRETED BY

Andrea Nicastro, DVM,
 Diplomate ACVIM
 (Small Animal Internal
 Medicine)

HOSPITAL NAME

Animal Emergency
 Hospital

REFERRING VET

Dr. Hicks

INVOICE

14311

PRESENTING CLINICAL SIGNS

Referral from rDVM - Vomiting since Friday, wt loss. Hx of Lepto Vax in 2020. Collapsing Trachea work up early 2022. Elevations in: BUN >140, Creat 3.4, ALT (too high to read), ALP >993, T.bil 16.7, Phos 13.4 (H), TP 7.8(H), Glob 3.9 (H) Na 130 (L), Cl 76 (L) Neutrophilia, monocytosis HCT 57 (H), HGB 19.4(H). Per O - heat cycle about 2 months ago, has only seen P have a couple in her life, no regular - Friday P threw-up food, since then has been throwing up liquid 3-5 times per day - Not eating - O reports that P didn't urinate for more than 12 hour, seems to not need to go; did urinated what O thinks is a normal amount today - No know ingestion of toxin, foreign substance - P has a fences in yard or goes out on a leash ALT 3,041, ALP 3658, BUN 155.

Current Medications: None listed.

Date of Previous IntraPet Ultrasound: No previous.

Sedation: Not required to complete full diagnostic ultrasound.

Stat Report: Not requested.

Imaging Performed By: Rachel Brillhart, RDMS.

ULTRASONOGRAPHIC EXAMINATION OF THE ABDOMEN**Urinary System**

The urinary bladder wall is normal in thickness and the mucosal surface is smooth. The bladder lumen is moderately distended with anechoic urine. No masses, inflammatory changes or calculi are observed. The region of the trigone is normal.

The left kidney is normal size (3.74 cm in length); normal shape and architecture with smooth peripheral margins. There is a normal 1:3 cortex to medulla ratio with poor corticomedullary distinction. Mild pyelectasia (in the transverse plane) is present. There is no evidence of nephroliths, infarcts or hydroureter. Renal vasculature is normal. A 0.44 cm cortical cyst is observed at the caudal aspect.

The right kidney is normal size (3.68 cm in length); normal shape and architecture with smooth peripheral margins. There is a normal 1:3 cortex to medulla ratio with poor corticomedullary distinction. Trace pyelectasia is present. There is no evidence of nephroliths, infarcts or hydroureter. Renal vasculature is normal. A 0.44 cm cortical cyst is observed at the caudal aspect.

Adrenal Glands

The left adrenal gland is normal size (0.48 cm at cranial pole) (0.44 cm at caudal pole) (1.42 cm in length); normal shape; homogenous parenchyma. The glandular echogenicity and detail are unremarkable. Capsule, cortex, and medullary definition are normal. The phrenicoabdominal vein and surrounding vasculature are normal.

The right adrenal gland is normal size (0.67 cm at cranial pole) (0.43 cm at caudal pole) (1.68 cm in length); normal shape; homogenous parenchyma. The glandular echogenicity and detail are unremarkable. Capsule, cortex, and medullary definition are normal. The phrenicoabdominal vein and surrounding vasculature are normal.

Spleen

The spleen is normal in size (0.76 cm in width at the level of the hilus) with a normal capsular contour. There is appropriate echogenicity and echotexture. No focal lesions are observed. Splenic vasculature is normal.

Liver

The liver is subjectively prominent in size with slightly swollen peripheral contours. The parenchyma is hypoechoic relative to the spleen and homogeneous in appearance. No focal lesions are observed. Vascular and biliary tracts are of normal volume with no evidence of congestion. The gall bladder is distended. The wall is normal thickness. A moderate to large amount of aggregated, echogenic suspended sludge is observed

within the lumen. The mesentery effacing the serosal surface is hyperechoic. Trace free fluid is observed adjacent to the gallbladder. The cystic duct wall appears mildly thickened but is not overtly dilated.

Gastrointestinal

The stomach and intestine are free of stasis and exhibit normal peristaltic activity. The gastric lumen is mildly fluid distended. The gastric wall and pylorus are normal in thickness with a normal layering pattern. The pyloric outflow tract is patent. The small intestinal lumen is not dilated. The small intestinal wall thickness is normal with a normal layering pattern and appropriate mural detail. Discreet masses are not identified. The colonic wall is normal. No obstructive disease is noted.

Pancreas

The right limb of the pancreas is visible with normal curvilinear peripheral contours. The parenchyma is largely isoechoic relative to surrounding omental fat and slightly mottled in appearance. The pancreatic duct is visible but not overtly dilated. There is no evidence of peripancreatic inflammation or effusion.

Free Abdomen

Trace free fluid is observed adjacent to the gallbladder. The abdominal lymph nodes are normal/not visible.

Other

The uterine body is visible and is normal in size (0.80 cm in width). No obvious pathology is seen.

The left ovary is visible. A 2.28 x 1.81 cm anechoic cyst is arising from the parenchyma. The remainder of the parenchyma is homogeneous.

The right ovary is subjectively normal in size (1.38 x 0.98 cm). No obvious abnormalities are seen.

ULTRASONOGRAPHIC FINDINGS

Primary Findings:

- The gallbladder changes are most consistent with a fully formed mucocele with suspected cholecystitis and adjacent peritonitis.
- The mild hepatomegaly may be secondary to inflammatory disease, emerging vacuolar hepatopathy, infiltrative neoplasia (less likely), other hepatopathy.

Secondary Findings:

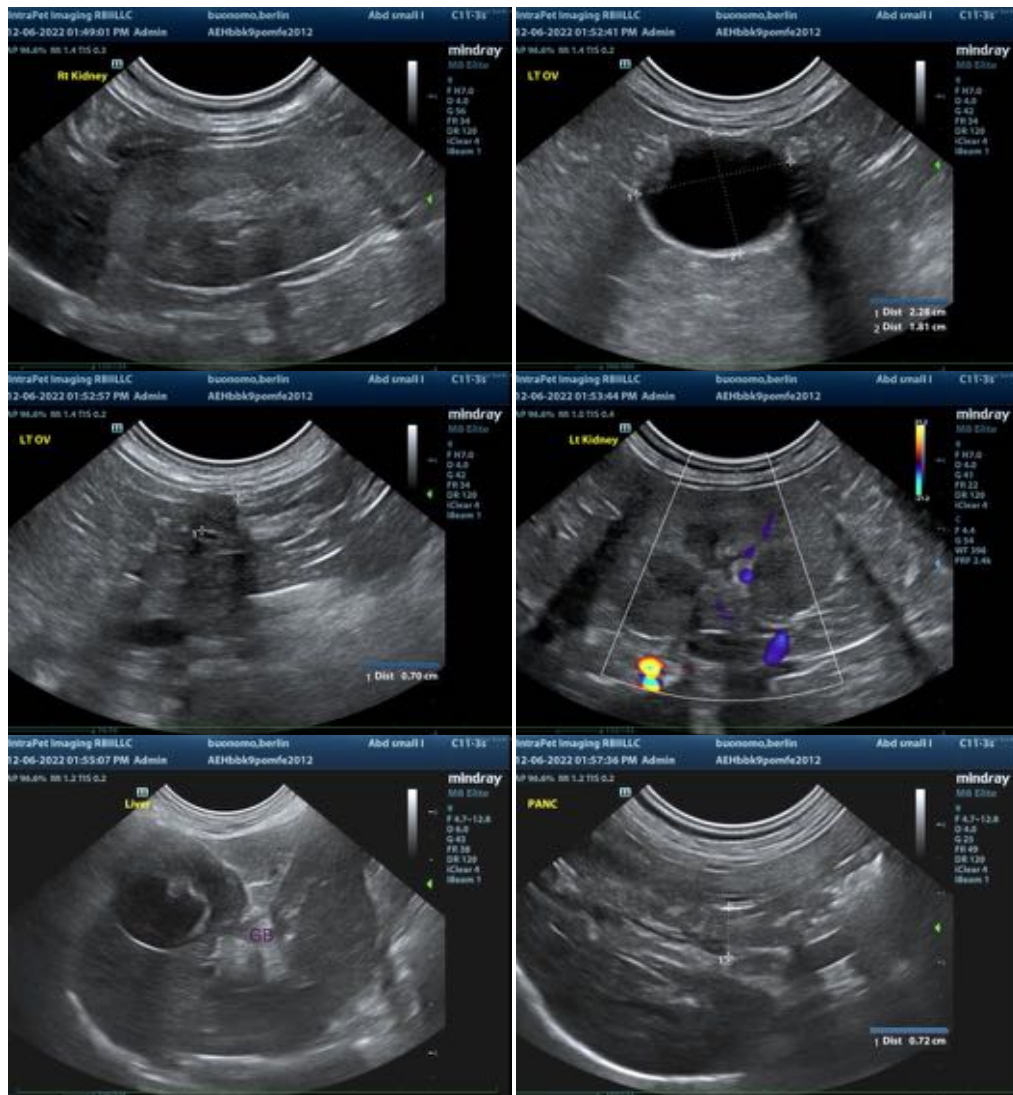
- The pancreatic changes are most consistent with age-related parenchymal remodeling, potentially secondary to a prior inflammatory episode, early fibrosis or chronic pancreatitis.
- Bilateral degenerative renal changes with trace pyelectasia.

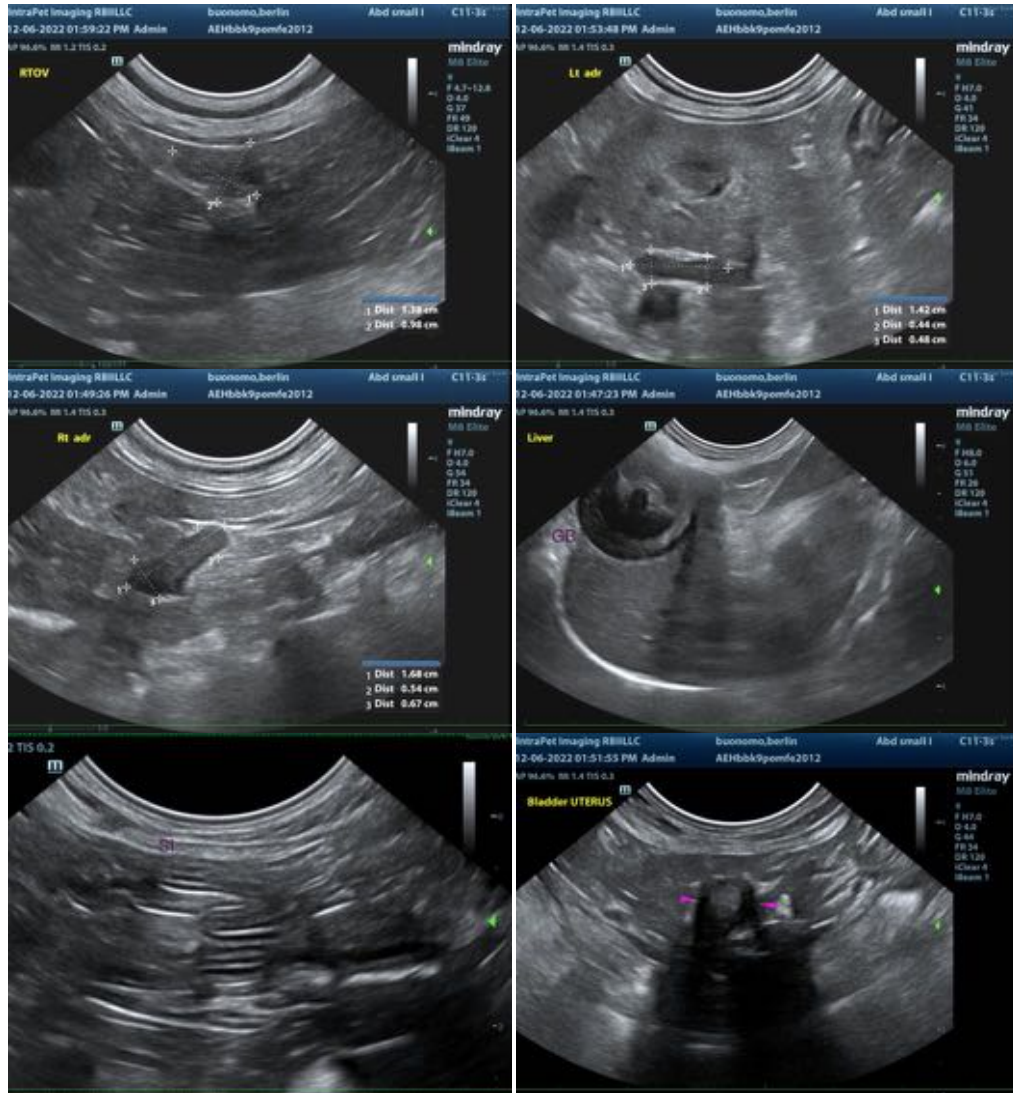
INTERPRETATION OF THE FINDINGS & FURTHER RECOMMENDATIONS

- A cholecystectomy and liver biopsy is recommended due to the risk of possible gallbladder rupture. If the patient is stable under anesthesia, also consider performing an ovariohysterectomy. Prior to surgery, clotting times (PT/PTT) and thoracic radiographs should be performed. If surgery is not performed at this time, empirical treatment for cholecystitis/bacterial cholangiohepatitis is recommended including fluid therapy, broad spectrum antibiotics, pain medication, Ursodiol and

symptomatic care as needed. If this approach is taken, close sonographic monitoring of the gall bladder is recommended.

- Given the azotemia and sonographic renal changes, consider the following:
 1. Urine culture and sensitivity
 2. UPC (if proteinuria is present in the absence of infection)
 3. Baseline blood pressure measurement
 4. IV fluid diuresis and supportive care





The information and recommendations provided are based on the images presented by the referring veterinarian. No evaluation can be communicated regarding pathology that was not visible in the image/video clips provided.

Thank you for this referral. If the clinical or image interpretation does not parallel your findings or if I can be of any further assistance please contact me.

Andrea Nicastro, MPH, DVM, Diplomate DACVIM (Small Animal Internal Medicine)
info@SonoPath.com