

**DATE**

12/6/2021

PRESENTING CLINICAL SIGNS

History: No clinical signs other than allergic skin disease with secondary yeast infection. Intermittently on ketoconazole but has not been on it for a few weeks. Just restarted after the most recent bloodwork was taken. Had diarrhea in late October, resolved on Metronidazole and Provioline. Bloodwork from Long Green Animal Dermatology found increased ALP. Will have that forwarded over.

PATIENT

Jax Petty

Current Medications: Ketoconazole 200mg 1 1/2 tablets once daily
Hills I/D food.

SPECIES

Canine

Lab Results: ALP increased at 657

Date of Previous IntraPet Ultrasound: No previous IntraPet scans.

Sedation: IV sedative.

BREED

Stat Report: Not requested.

Labrador Retriever

SEX

Male, neutered

ULTRASONOGRAPHIC EXAMINATION OF THE ABDOMEN**Urinary System**

The urinary bladder, trigone, and pelvic urethra are normal in thickness and the mucosal surface is smooth. The bladder lumen is moderately distended with anechoic urine. No masses, inflammatory changes or calculi are observed. Ureteral papillae and visualized portion of the proximal urethra, visible to a depth of 2 cm, are normal.

AGE

9/11/2018

The prostate is not definitively visualized due to its pelvic location.

WEIGHT

93.5 lbs.

The left kidney is normal size (7.11 cm in length); normal shape and architecture with smooth peripheral margins. There is a normal 1:3 cortex to medulla ratio with normal corticomedullary distinction. There is no evidence of pyelectasia, nephroliths, infarcts or hydronephrosis. Renal vasculature is normal.

INTERPRETED BY

The right kidney is normal size (6.89 cm in length); normal shape and architecture with smooth peripheral margins. There is a normal 1:3 cortex to medulla ratio with normal corticomedullary distinction. There is no evidence of pyelectasia, nephroliths, infarcts or hydronephrosis. Renal vasculature is normal.

Adrenal Glands

The left adrenal gland is normal size (0.59 cm at cranial pole) (0.73 cm at caudal pole) (2.45 cm in length); normal shape; homogenous parenchyma. The glandular echogenicity and detail are unremarkable. Capsule, cortex, and medullary definition are normal. The phrenicoabdominal vein and surrounding vasculature are normal.

The right adrenal gland is normal size (0.67 cm at cranial pole) (0.75 cm at caudal pole) (2.74 cm in length); normal shape; homogenous parenchyma. The glandular echogenicity and detail are unremarkable. Capsule, cortex, and medullary definition are normal. The phrenicoabdominal vein and surrounding vasculature are normal.

Spleen

The spleen is normal in size (2.00 cm in width at the level of the hilus) with a normal capsular contour. There is appropriate echogenicity and echotexture. No focal lesions are observed. Splenic vasculature is normal.

Liver**IMAGING PERFORMED BY**

Rachel Brillhart RDMS

HOSPITAL NAME

Abbey AH

REFERRING VET

Dr. Kluttz

INVOICE

12642

The liver is subjectively normal in size with normal curvilinear peripheral contours. The parenchyma is hypoechoic relative to the spleen and subtly mottled in appearance. No distinct focal lesions are observed. Vascular and biliary tracts are of normal volume with no evidence of congestion. The gall bladder lumen is moderately distended. The wall is thin and smooth. A scant amount of gravity-dependent echogenic debris is observed within the lumen. The cystic and common bile ducts are normal/not seen.

Gastrointestinal

The stomach and intestine are free of stasis and exhibit normal peristaltic activity. The gastric lumen is not distended. The gastric wall and pylorus are normal in thickness with a normal layering pattern. The pyloric outflow tract is patent. The small intestinal lumen is not dilated. The small intestinal wall thickness is normal with a normal layering pattern and appropriate mural detail. Discreet masses are not identified. The colonic wall is normal. No obstructive disease is noted.

Pancreas

The right limb of the pancreas is prominent in size with minimal deviation from the normal peripheral contours. The parenchyma is isoechoic relative to surrounding omental fat and slightly mottled in appearance. No distinct focal lesions are observed. the pancreatic duct is not overtly dilated.

Free Abdomen

The peritoneal cavity is normal. There is no evidence of inflammation or effusion. The abdominal lymph nodes are normal/not visible.

ULTRASONOGRAPHIC FINDINGS

Primary Findings:

- Non-specific diffuse hepatic mottling. Differentials include vacuolar hepatopathy (i.e., secondary to iatrogenic steroid use, if applicable), mild cholestasis, hepatotoxicity (i.e., drug induced, less likely), other hepatopathy.

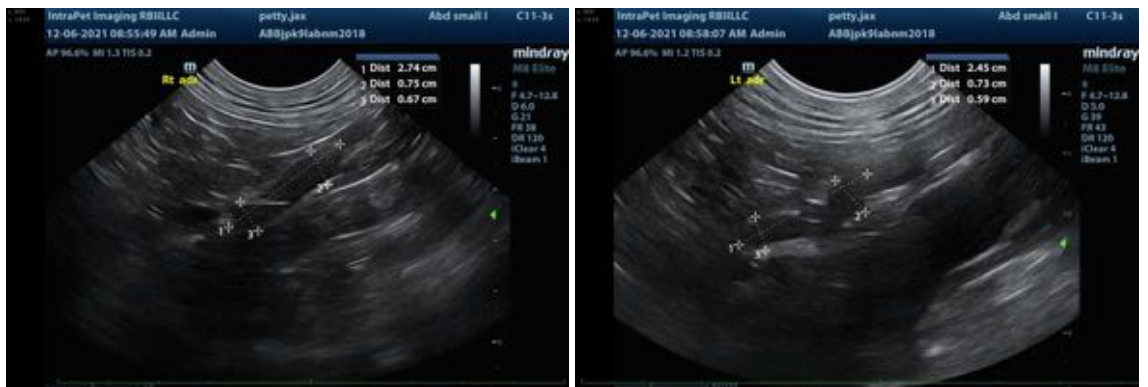
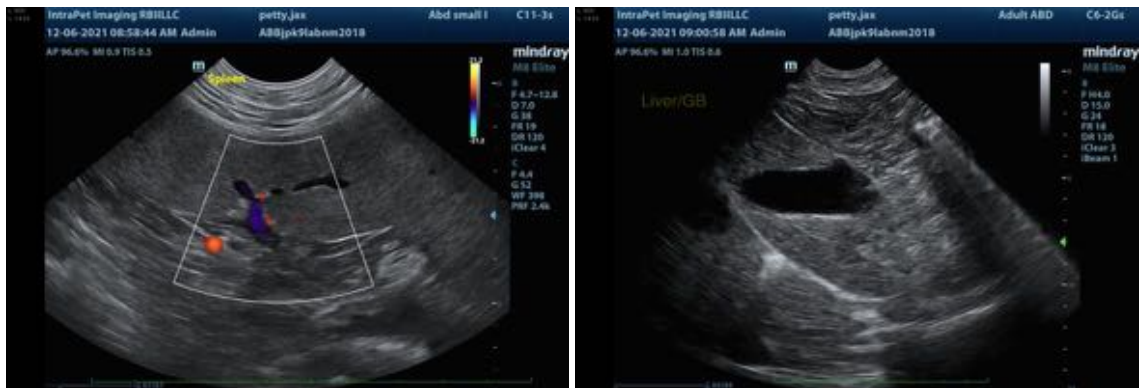
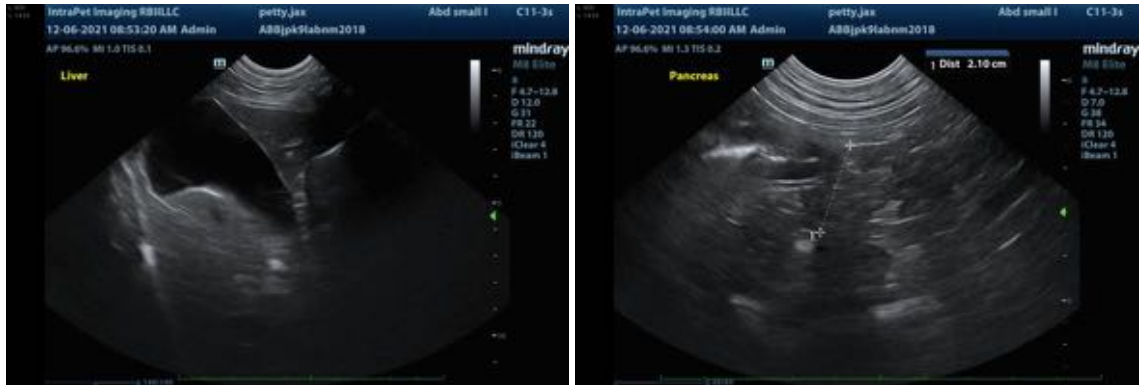Secondary Findings:

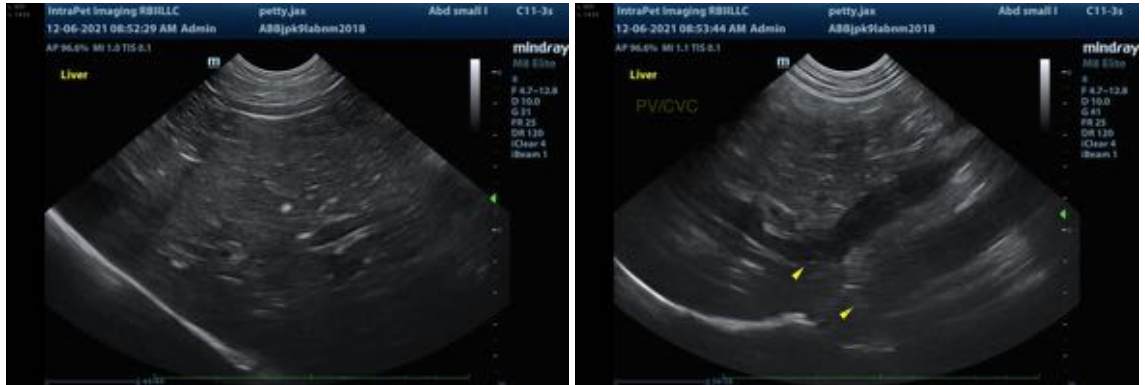
- The pancreatic changes may represent low-grade inflammation and/or remodeling or may be a normal variant for this patient. Correlation with clinical findings is recommended.

INTERPRETATION OF THE FINDINGS & FURTHER RECOMMENDATIONS

- Consider pre- and post-prandial serum bile acids to assess hepatic function.
- A fine needle aspirate of the liver can be considered (if clotting status is appropriate). However, the results may be of low yield. Another option would be to repeat bloodwork in 2-3 weeks. If the ALP is similarly elevated, hepatic tissue sampling may be warranted at that time.

- Given the history of allergic skin disease, further history should be obtained regarding any potential oral or topical corticosteroid use that might be resulting in the ALP elevation.





The information and recommendations provided are based on the images presented by the referring veterinarian. No evaluation can be communicated regarding pathology that was not visible in the image/video clips provided.

Thank you for this referral. If the clinical or image interpretation does not parallel your findings or if I can be of any further assistance please contact me.

Andrea Nicastro, DVM, Diplomate ACVIM (*Small Animal Internal Medicine*)
Andrea.nicastro@sonopath.com