

**DATE**

12/6/21

PRESENTING CLINICAL SIGNS

History: Hx of Cushing's dz. Unable to tolerate Trilostane so dz currently controlled with diet and herbs. Dog overall doing well. U/S on 8/21- revealed bilateral adrenal masses (this was before the ACTH stim test was done) and some poorly defined hypoechoic liver masses. Owner wants to recheck status of the liver masses.

PATIENT

Buddy Tishna

Current Medications: Herbals- four marvels to control Cushing's dz.

Lab Results: ALKP 134.

SPECIES

Canine

Date of Previous IntraPet Ultrasound: No previous IntraPet scans. Previous elsewhere, DVM unsure.

Sedation: Not required for a full diagnostic ultrasound.

Stat Report: Not requested.

BREED

Shih Tzu

ULTRASONOGRAPHIC EXAMINATION OF THE ABDOMEN**Urinary System****SEX**

Male, neutered

The urinary bladder, trigone, and pelvic urethra are normal in thickness and the mucosal surface is smooth. The bladder lumen is moderately distended with anechoic urine. No masses, inflammatory changes or calculi are observed. Ureteral papillae and visualized portion of the proximal urethra, visible to a depth of 2 cm, are normal.

AGE

10/16/2012

The prostate is normal in size (0.72 cm in width) and shape. Parenchyma is homogenous. The prostatic urethra appears normal without evidence of dilation or obstruction.

WEIGHT

21.42 lbs.

The left kidney is normal size (4.40 cm in length); normal shape and architecture with smooth peripheral margins. There is a normal 1:3 cortex to medulla ratio with moderate loss of corticomedullary distinction. There is no evidence of pyelectasia, nephroliths, infarcts or hydroureter. Renal vasculature is normal.

INTERPRETED BY

Andrea Nicastrò, DVM,
Diplomate ACVIM
(Small Animal Internal
Medicine)

The right kidney is normal size (4.34 cm in length); normal shape and architecture with smooth peripheral margins. There is a normal 1:3 cortex to medulla ratio with moderate loss of corticomedullary distinction. There is no evidence of pyelectasia, nephroliths, infarcts or hydroureter. Renal vasculature is normal.

Adrenal Glands**IMAGING PERFORMED BY**

Stephanie Pearce
RDCS, RVT

The left adrenal gland is enlarged (2.18 cm at cranial pole) (1.12 cm at caudal pole) (4.00 cm in length) with an irregular shape. A 2.30 x 2.07 cm hyperechoic to slightly heterogeneous nodule/mass is observed at the cranial pole. The caudal pole is slightly heterogeneous with some loss of glandular detail. The phrenicoabdominal vein and surrounding vasculature are normal.

HOSPITAL NAME

Healing Paws
Veterinary Wellness
Center

The right adrenal gland is enlarged at the cranial pole and normal in size at the caudal pole (1.28 cm at cranial pole) (0.48 cm at caudal pole) (2.18 cm in length) with an irregular shape. A 1.75 x 1.28 cm hyperechoic to heterogeneous nodule with hyperechoic foci is observed at the cranial aspect. The glandular echogenicity and detail at the caudal aspect are unremarkable. The phrenicoabdominal vein and surrounding vasculature are normal.

Spleen**REFERRING VET**

Dr. Levitsky

The spleen is normal in size (1.55 cm in width at the level of the hilus) with a normal capsular contour. There is appropriate echogenicity and echotexture. A 0.65 x 0.46 cm hypoechoic nodule is visualized. Splenic vasculature is normal.

INVOICE

Liver

The liver is subjectively prominent in size with swollen curvilinear peripheral contours. The parenchyma is isoechoic relative to the spleen and exhibits mild heterogeneity. No distinct focal lesions are observed. Hepatic vasculature and biliary tracts are of normal volume with no evidence of congestion. The gall bladder lumen is moderately distended. The wall is thin and smooth. A moderate amount of aggregated echogenic partially dependent debris/sludge is observed within the lumen. The cystic and common bile ducts are normal/not seen.

Gastrointestinal

The stomach and intestine are free of stasis and exhibit normal peristaltic activity. The gastric lumen is not distended. The gastric wall and pylorus are normal in thickness with a normal layering pattern. The pyloric outflow tract is patent. The small intestinal lumen is not dilated. The small intestinal wall thickness is normal with a normal layering pattern and appropriate mural detail. Discreet masses are not identified. The colonic wall is normal. No obstructive disease is noted.

Pancreas

The pancreas is visible with normal curvilinear peripheral contours. The parenchyma is largely hypoechoic relative to surrounding omental fat and slightly mottled in appearance. The pancreatic duct is visible but not overtly dilated. There is no evidence of peripancreatic inflammation or effusion.

Free Abdomen

The peritoneal cavity is normal. There is no evidence of inflammation or effusion. The abdominal lymph nodes are normal/not visible.

ULTRASONOGRAPHIC FINDINGS

Primary Findings:

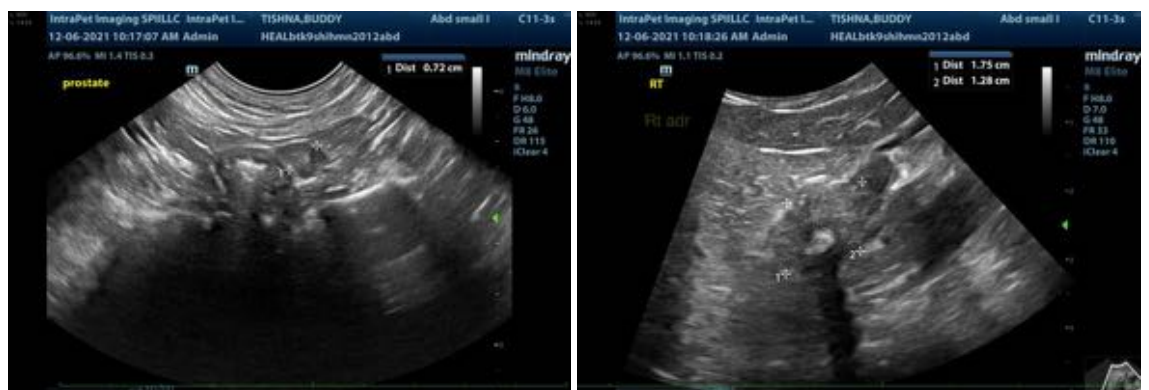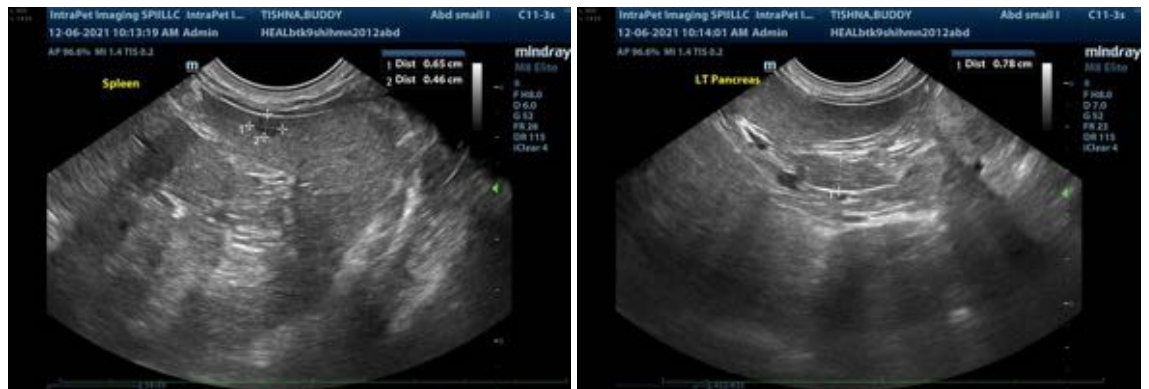
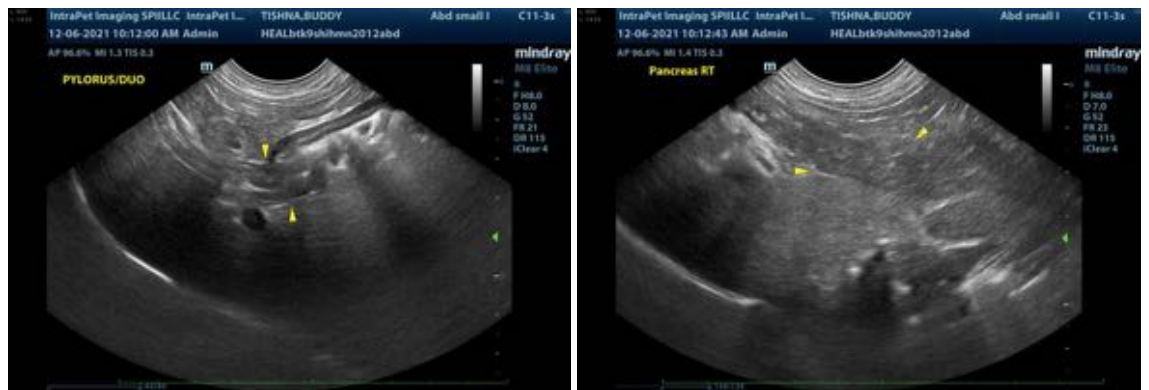
- Bilateral adrenal nodules (larger on the left side). Differentials include benign nodular hyperplasia, bilateral tumors, unilateral tumor with nodular hyperplasia in the contralateral gland.
- The diffuse hepatic changes are non-specific and could be consistent with vacuolar hepatopathy, regenerative nodular hyperplasia, and/or age-related remodeling. Inflammatory and infiltrative disease are considered less likely.
- Gallbladder debris, non-mucocele.

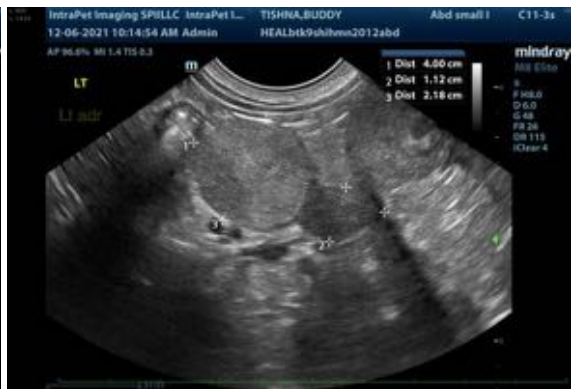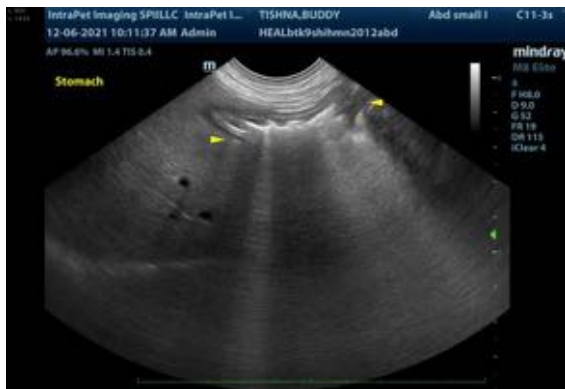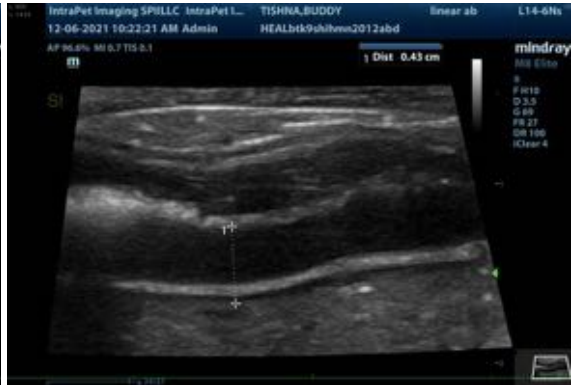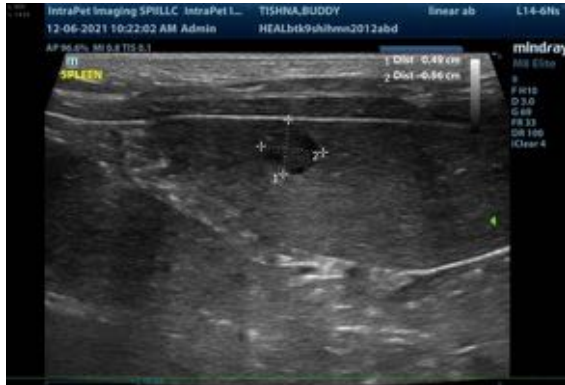Secondary Findings:

- Bilateral age-related renal changes.
- The pancreatic changes are most consistent with age-related parenchymal remodeling, potentially secondary to a prior inflammatory episode, early fibrosis or chronic pancreatitis.
- The hypoechoic splenic nodule trends toward the benign (i.e., a focus of lymphoid hyperplasia or extramedullary hematopoiesis) with a lower possibility of emerging neoplasia.

INTERPRETATION OF THE FINDINGS & FURTHER RECOMMENDATIONS

- To determine if the adrenal changes are similar to the previous scan, the report from August 2021 would be necessary for comparison.
- Given the patient's Cushing's status, a baseline blood pressure measurement, a UPC and three-view thoracic radiographs are recommended.





The information and recommendations provided are based on the images presented by the referring veterinarian. No evaluation can be communicated regarding pathology that was not visible in the image/video clips provided.

Thank you for this referral. If the clinical or image interpretation does not parallel your findings or if I can be of any further assistance please contact me.

Andrea Nicastro, DVM, Diplomate ACVIM (*Small Animal Internal Medicine*)
Andrea.nicastro@sonopath.com