



PATIENT

Toto Welch

SPECIES

Canine

BREED

Shih Tzu

SEX

Male Neutered

AGE

11/1/2018

WEIGHT

7.3kg

INTERPRETED BY

Andrea Nicastro DVM
Diplomate ACVIM
(Sm Animal Internal Med)

**IMAGING
PERFORMED BY**

Andrea Nicastro DVM
Diplomate ACVIM
(Sm Animal Internal Med)

HOSPITAL NAME

VCA Palmetto AH

REFERRING VET

Amber Leavis
Shawna Buerkle

INVOICE

22219

DATE

12-5-25

PRESENTING CLINICAL SIGNS

Clinical Exam Findings: Elevated liver values with a diabetic, AUS performed 11/5, LDDST negative. Trial of antibiotics + Denamarin did not improve liver values. Here for liver aspirate. PT/PTT will be performed same day. Clotting times today were normal.

Abnormal lab-work values: Previously emailed but will email again

Current Medications: None

Radiographic Findings: None being emailed

**This study was limited to the liver and gallbladder. There is a potential for pathology in organs that were not visualized

ULTRASONOGRAPHIC EXAMINATION OF THE ABDOMEN

Liver

The liver is subjectively enlarged, with smooth peripheral contours. The parenchyma is subjectively hyperechoic and subtly mottled in appearance. No focal lesions are observed. Hepatic vasculature and intrahepatic biliary tracts are of normal volume with no evidence of congestion. The portal vein to caudal vena cava ratio is approximately 1: 1.

The gallbladder lumen is moderately distended. The wall is thin and smooth. A small amount of mobile echogenic debris is observed within the lumen. The cystic and common bile ducts are normal/not seen.

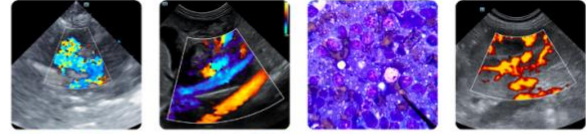
ULTRASONOGRAPHIC FINDINGS

- Hepatic changes are similar to the sonogram from last month.

*An ultrasound-guided fine-needle aspirate was performed at the end of this study. A scant amount of post-aspirate hemorrhage was observed, which remained unchanged after 10 minutes of sonograph monitoring.

INTERPRETATION OF THE FINDINGS & FURTHER RECOMMENDATIONS

- If the hepatic cytology results are inconclusive, liver biopsies with aerobic and anaerobic bile cultures, and hepatic copper quantitation may be warranted.



PATIENT

Toto Welch

SPECIES

Canine

BREED

Shih Tzu

SEX

Male Neutered

AGE

11/1/2018

WEIGHT

7.3kg

INTERPRETED BY

Andrea Nicastro DVM
 Diplomate ACVIM
 (Sm Animal Internal Med)

IMAGING PERFORMED BY

Andrea Nicastro DVM
 Diplomate ACVIM
 (Sm Animal Internal Med)

HOSPITAL NAME

VCA Palmetto AH

REFERRING VET

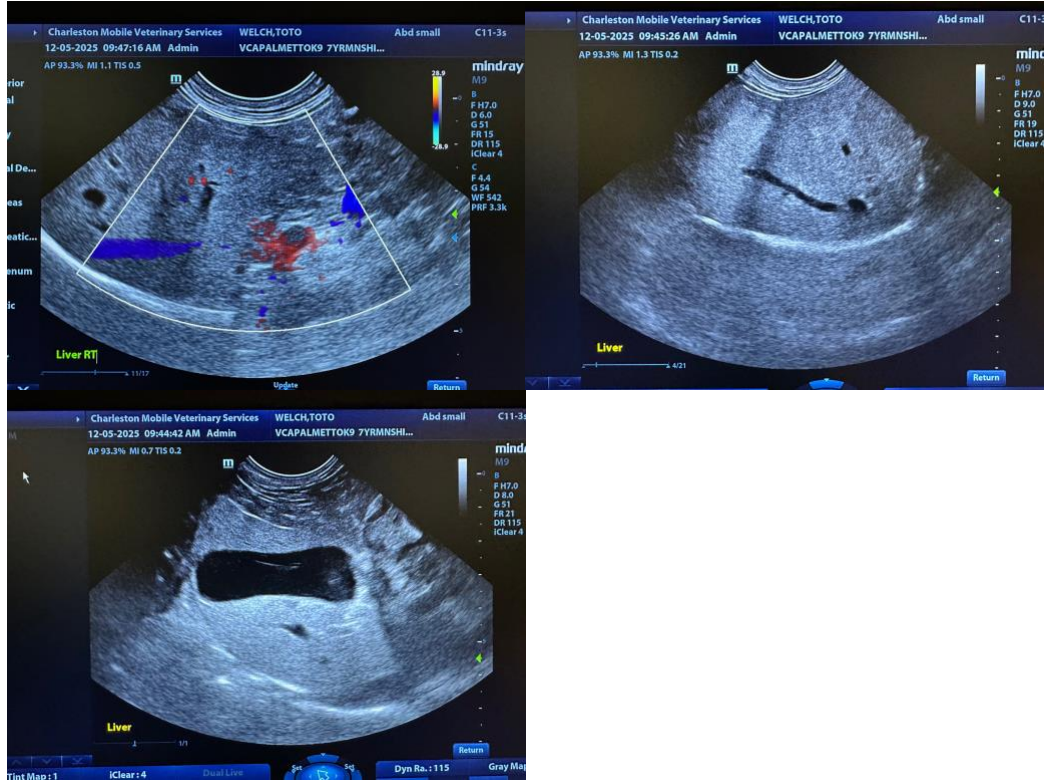
Amber Leavis
 Shawna Buerkle

INVOICE

22219

DATE

12-5-25



The information and recommendations provided are based on the images presented by the referring veterinarian/sonographer. No evaluation can be communicated regarding pathology that was not visible in the image/video clips provided.

Thank you for this referral. If the clinical or image interpretation does not parallel your findings or if I can be of any further assistance, please contact me.

Andrea Nicastro, MPH, DVM, Diplomate DACVIM (Small Animal Internal Medicine)
info@SonoPath.com