



PATIENT PRESENTING CLINICAL SIGNS

Jett Hunt Abnormal lab-work values: Elevated liver values

SPECIES Current Medications: Trilostane 16mg - 1/2 T PO BID, Simparica Trio q30 days

Canine **ULTRASONOGRAPHIC EXAMINATION OF THE ABDOMEN**

BREED *Urinary System*

Chihuahua The urinary bladder wall is normal in thickness and the mucosal surface is smooth. The bladder lumen is moderately distended with anechoic urine. No masses, inflammatory changes or calculi are observed. Ureteral papillae and visualized portion of the proximal urethra, visible to a depth of 3-4 cm, are normal.

SEX

Neutered Male The prostate is normal in size (0.71 cm in width) and shape. Parenchyma is homogenous. The prostatic urethra appears normal without evidence of dilation or obstruction.

AGE

08/16/2011 The left kidney is normal size (3.82 cm in length); with a normal shape, smooth peripheral margins, and normal internal architecture. There is moderate loss of corticomedullary distinction. Several hyperechoic shadowing diverticular foci are observed. Pinpoint hyperechoic foci are observed within the cortex. A few nonobstructive nephroliths are visualized. There is no evidence of pyelectasia, infarcts or hydronephrosis. Renal vasculature is normal.

WEIGHT

19.02 lbs The right kidney is normal size (6.03 cm in length); with a normal shape, smooth peripheral margins, and normal internal architecture. There is moderate loss of corticomedullary distinction. Several hyperechoic shadowing diverticular foci are observed. Pinpoint hyperechoic foci are observed within the cortex. A few nonobstructive nephroliths are visualized. There is no evidence of pyelectasia, infarcts or hydronephrosis. Renal vasculature is normal.

INTERPRETED BY

Andrea Nicastro,
DVM, Diplomate ACVIM
(Small Animal Internal
Medicine)

Adrenal Glands

The left adrenal gland is enlarged (0.87 cm at cranial pole) (1.06 cm at caudal pole); with a slightly irregular shape. The parenchyma is mildly heterogenous with some loss of glandular detail. The phrenicoabdominal vein and surrounding vasculature are normal.

IMAGING PERFORMED BY

Andrea Nicastro,
DVM, Diplomate ACVIM
(Small Animal Internal
Medicine)

The right adrenal gland is enlarged (1.08 cm at cranial pole) (0.85 cm at caudal pole); with a slightly irregular shape. The parenchyma is mildly heterogenous with some loss of glandular detail. The phrenicoabdominal vein and surrounding vasculature are normal.

Spleen

The spleen is normal in size (1.01 cm in width at the level of the hilus) with a normal capsular contour. There is appropriate echogenicity and echotexture. No focal lesions are observed. Splenic vasculature is normal.

HOSPITAL NAME

Flowertown AH

Liver

The liver is enlarged with swollen peripheral contours. The parenchyma is isoechoic to slightly hyperechoic relative to the spleen and subtly mottled in appearance. No distinct focal lesions are observed. Numerous intrahepatic biliary stones are present. Hepatic vasculature and intrahepatic biliary tracts are of normal volume with no evidence of congestion. The portal vein to caudal vena cava ratio is approximately 1: 1.

REFERRING VET

Dr. McLaughlin

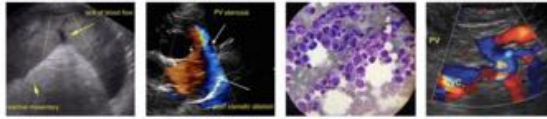
INVOICE

11956

The gall bladder is distended. The wall is mildly thickened (up to 0.44 cm), irregular and hyperechoic to mineralized. A moderate amount of echogenic to mineralized suspended debris/sludge is suspended within the lumen. The cystic and common bile ducts are normal/not seen. The duodenal papilla is normal.

DATE

12.5.2022



PATIENT

Jett Hunt

SPECIES

Canine

BREED

Chihuahua

SEX

Neutered Male

AGE

08/16/2011

WEIGHT

19.02 lbs

INTERPRETED BY

Andrea Nicastro,
DVM, Diplomate ACVIM
(Small Animal Internal
Medicine)

**IMAGING
PERFORMED BY**

Andrea Nicastro,
DVM, Diplomate ACVIM
(Small Animal Internal
Medicine)

HOSPITAL NAME

Flowertown AH

REFERRING VET

Dr. McLaughlin

INVOICE

11956

DATE

12.5.2022

Gastrointestinal

The gastric lumen is not distended. The gastric wall and pylorus are normal in thickness with a normal layering pattern. The pyloric outflow tract is patent. The small intestinal lumen is not dilated. The small intestinal wall is normal mildly thickened (up to 0.53 cm) with retention of the normal layering pattern. There is evidence of mucosal speckling +/- striations in a few segments. Discreet masses are not identified. The colonic wall is normal. There is no obvious evidence of an obstructive pattern.

Pancreas

The pancreas is normal in size with normal peripheral contours. The pancreatic duct is normal. The base and limbs of the pancreas are isoechoic to surrounding omental fat. No focal lesions are observed. There is no evidence of peripancreatic inflammation or effusion.

Free Abdomen

The peritoneal cavity is normal. There is no evidence of inflammation or effusion. The abdominal lymph nodes are normal/not visible.

Other

A brief echocardiogram reveals no evidence of pericardial effusion or obvious right atrial/auricular mass.

ULTRASONOGRAPHIC FINDINGS

Primary Findings

- The gall bladder changes are most consistent with cholecystitis with a possible emerging mucocele.
- The diffuse hepatic parenchymal changes are nonspecific and could be associated with inflammatory disease (i.e., chronic hepatitis, bacterial cholangiohepatitis), Leptospirosis, hepatotoxicosis, or other hepatopathy, +/- concurrent age-related change (i.e., vacuolar hepatopathy, regenerative nodular hyperplasia). The intrahepatic biliary stones are likely an incidental finding.

Secondary Findings

- Bilateral age-related renal changes with dystrophic mineralization.
- The bilateral adrenomegaly is most consistent with the previous diagnostics of pituitary-dependent hyperadrenocorticism.
- The small intestinal wall changes are suggestive of a chronic enteropathy (i.e., lymphangiectasia, inflammatory bowel disease, other). However, correlation with the patient's clinical history is recommended.

INTERPRETATION OF THE FINDINGS & FURTHER RECOMMENDATIONS

- Regarding the elevated liver enzymes and sonographic liver/gall bladder changes, consider the following:
 1. Pre-and postprandial serum bile acids to assess hepatic function
 2. Leptospirosis testing (i.e., blood and urine PCR, serology)
 3. Hepatic tissue sampling (i.e., fine-needle aspirate or biopsy (i.e., laparoscopic or surgical)), if clotting status is appropriate. In the meantime, empirical treatment for cholecystitis/bacterial cholangiohepatitis/emerging mucocele, is recommended, including broad-spectrum antibiotic therapy, hepatic antioxidants and Ursodiol. If liver values are



PATIENT

Jett Hunt

not improving within 7-10 days of initiating therapy, hepatic tissue sampling should be revisited.

- Serial sonographic monitoring (i.e., every 4-6 weeks) of the gall bladder is recommended to assess for progression to a fully-formed mucocele.

SPECIES

Canine

BREED

Chihuahua

SEX

Neutered Male

AGE

08/16/2011

WEIGHT

19.02 lbs

INTERPRETED BY

Andrea Nicastro,
DVM, Diplomate ACVIM
(Small Animal Internal
Medicine)

IMAGING PERFORMED BY

Andrea Nicastro,
DVM, Diplomate ACVIM
(Small Animal Internal
Medicine)

HOSPITAL NAME

Flowertown AH

REFERRING VET

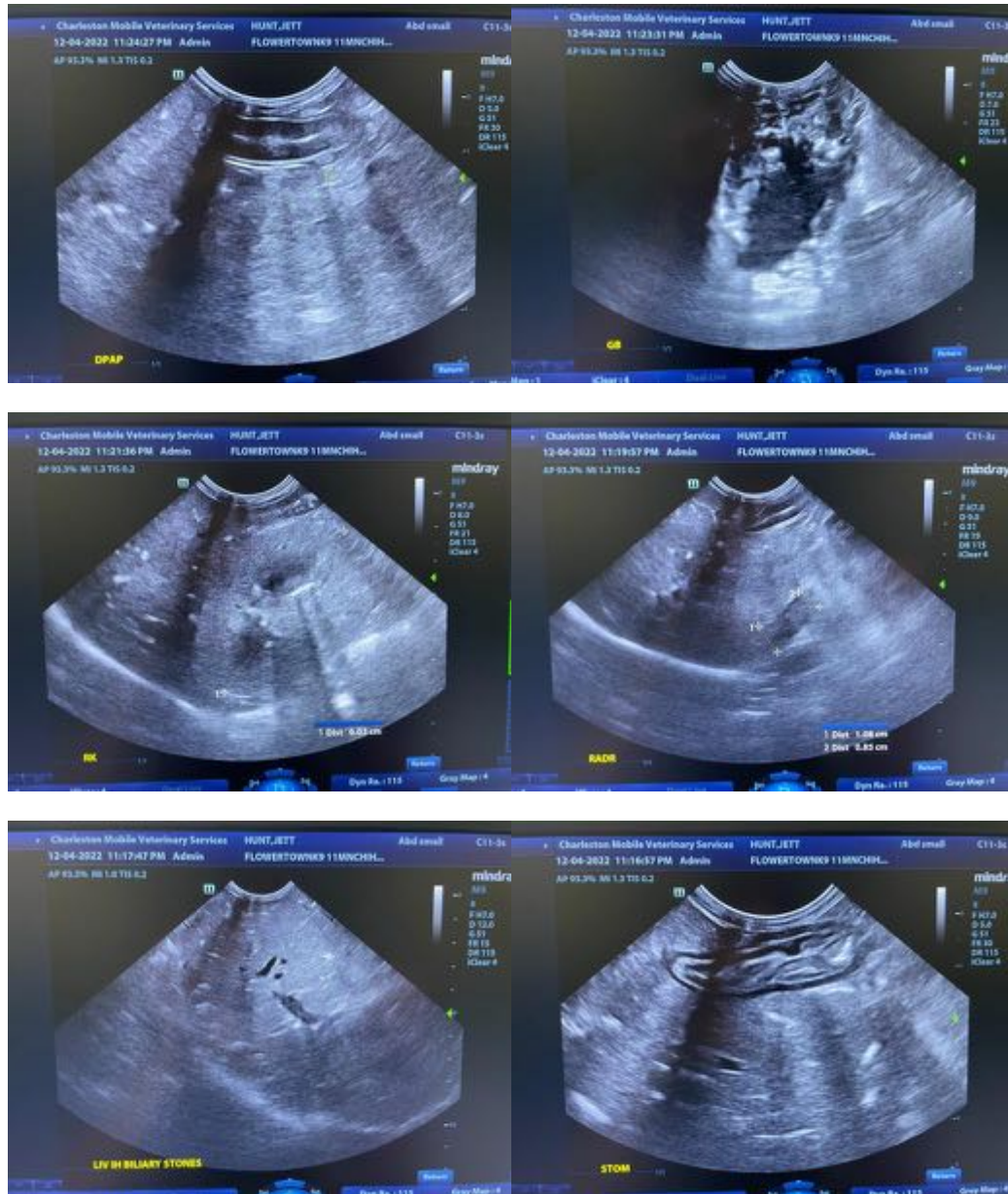
Dr. McLaughlin

INVOICE

11956

DATE

12.5.2022





PATIENT

Jett Hunt

SPECIES

Canine

BREED

Chihuahua

SEX

Neutered Male

AGE

08/16/2011

WEIGHT

19.02 lbs

INTERPRETED BY

Andrea Nicastro,
DVM, Diplomate ACVIM
(Small Animal Internal
Medicine)

**IMAGING
PERFORMED BY**

Andrea Nicastro,
DVM, Diplomate ACVIM
(Small Animal Internal
Medicine)

HOSPITAL NAME

Flowertown AH

REFERRING VET

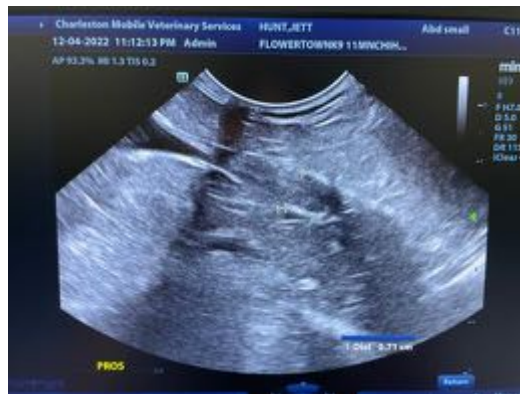
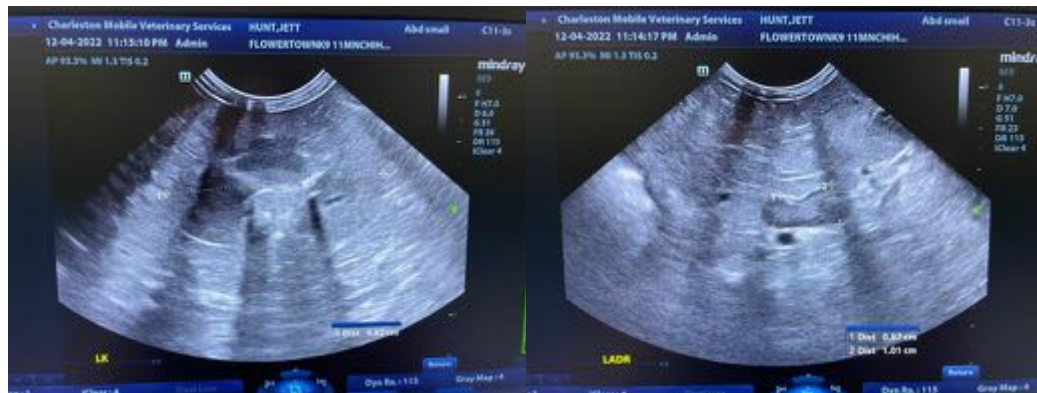
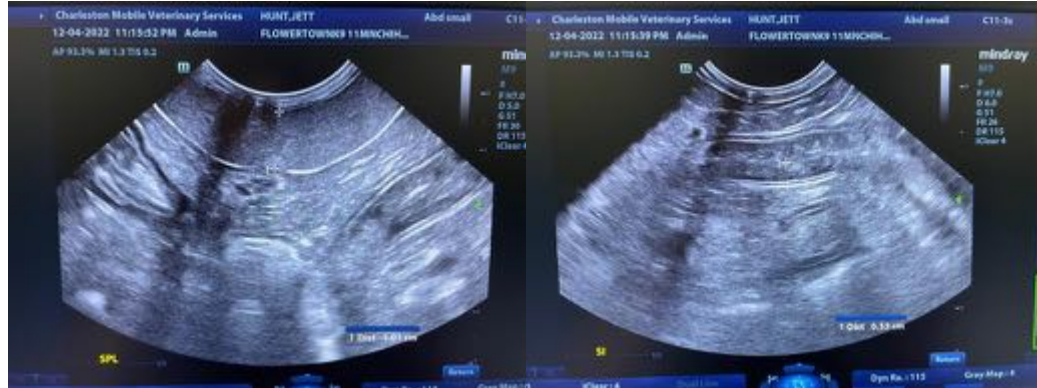Dr. McLaughlin

INVOICE

11956

DATE

12.5.2022



The information and recommendations provided are based on the images presented by the referring veterinarian/sonographer. No evaluation can be communicated regarding pathology that was not visible in the image/video clips provided.

Thank you for this referral. If the clinical or image interpretation does not parallel your findings or if I can be of any further assistance, please contact me.

Andrea Nicastro, MPH, DVM, Diplomate DACVIM (Small Animal Internal Medicine)
info@SonoPath.com