

PATIENT

Molly Indie

SPECIES

Canine

BREED

Bichon Frise

SEX

Spayed Female

AGE

12 Years

WEIGHT

15 lbs

INTERPRETED BY

Andrea Nicastro, DMV,
Diplomate DACVIM
(Small Animal
Internal Medicine)

IMAGING PERFORMED BY

Judy Schroeder

HOSPITAL NAME

Animal Health
Associates

REFERRING VET

Judy Schroeder

INVOICE

10101

DATE

12/31/21

PRESENTING CLINICAL SIGNS

History: Hx of Cushing's disease, untreated. Recent onset of lethargy and inappetence. Blood testing in October showed normal ALT (109 U/l) and moderate ALP (646 U/l) elevations. Blood testing last week showed extreme elevations in ALT, ALP, GGT, and Amylase, lipase.
Abnormal PE/Chem/CBC/UA Results: Distended abdomen, diarrheic feces. ALT 959 U/l ALP 1896 U/l GGT 56 U/l Albumin 2.4 g/dl Amylase >2400 U/l, Lipase 3816 U/l, spec cPL abnormal (inhouse)

ULTRASONOGRAPHIC EXAMINATION OF THE ABDOMEN

Urinary System

The urinary bladder is moderately distended. The wall is normal in thickness with a smooth mucosal surface. A large amount of aggregated echogenic suspended debris is observed within the lumen. The region of the trigone is normal.

The left kidney is normal in size (4.42 cm in length) with a normal shape, smooth peripheral margins, and normal internal architecture. There is mild to moderate loss of corticomedullary distinction. Several hyperechoic shadowing diverticular foci are observed. There is no evidence of pyelectasia, infarcts or hydronephrosis. Renal vasculature is normal.

The right kidney is normal in size (4.90 cm in length) with a normal shape, smooth peripheral margins, and normal internal architecture. There is mild to moderate loss of corticomedullary distinction. Several hyperechoic shadowing diverticular foci are observed. Trace pyelectasia is present. There is no evidence of infarcts or hydroureter. Renal vasculature is normal.

Adrenal Glands

The left adrenal gland is mildly enlarged (0.45 cm at cranial pole) (0.62 cm at caudal pole) (1.587 cm in length); normal shape; homogenous parenchyma. The glandular echogenicity and detail are unremarkable. Capsule, cortex, and medullary definition are normal. The phrenicoabdominal vein and surrounding vasculature are normal.

The right adrenal gland is normal size (0.77 cm at cranial pole) (0.46 cm at caudal pole) (1.57 cm in length); normal shape; homogenous parenchyma. The glandular echogenicity and detail are unremarkable. Capsule, cortex, and medullary definition are normal. The phrenicoabdominal vein and surrounding vasculature are normal.

Spleen

The spleen is normal in size (0.81 cm in width at the level of the hilus) with a normal capsular contour. There is appropriate echogenicity and echotexture. A few ill-defined myelolipomas are observed in the region of the hilus. Splenic vasculature is normal.

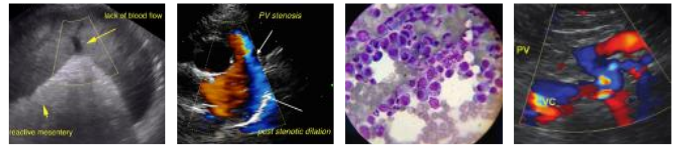
Liver

The liver is subjectively enlarged with irregular peripheral contours. Numerous varying-sized, coalescing, heterogenous nodules/masses are observed throughout the organ. There is no visibly normal hepatic tissue. Hepatic vasculature is of normal volume with no evidence of congestion.

The gall bladder lumen is moderately distended. The wall is thin and smooth. A moderate amount of aggregated gravity dependent echogenic to hyperechoic debris/sludge is observed within the lumen. The cystic and common bile ducts are normal.

Gastrointestinal

The stomach and intestine are free of stasis and exhibit normal peristaltic activity. The gastric lumen is minimally distended with ingesta. The gastric wall and pylorus are normal in thickness with a normal layering pattern. The small intestinal lumen is not dilated. The small intestinal wall thickness is normal.



PATIENT

with a normal layering pattern and appropriate mural detail. Discreet masses are not identified. The colonic wall is normal. No obstructive or overt infiltrative disease is noted.

Molly Indie

Pancreas

A portion of the pancreas is obscured by the hepatomegaly. In the visualized portions no obvious pathology is observed

SPECIES

Free Abdomen

Canine

A small to moderate amount of anechoic free fluid is visualized. The mesentery throughout the abdomen, particularly surrounding the liver, is hyperechoic. The abdominal lymph nodes are normal/not visible.

BREED

Bichon Frise

ULTRASONOGRAPHIC FINDINGS

SEX

Primary Findings

Spayed Female

- The hepatic changes are most concerning for diffuse infiltrative neoplasia (i.e., round cell tumor, carcinoma) with a low possibility of a benign hepatopathy (i.e., diffuse inflammatory disease).

AGE

- Diffuse peritonitis is likely secondary to hepatic pathology.

12 Years

Secondary Findings

WEIGHT

- Bilateral age-related renal changes with dystrophic mineralization
- The urinary bladder debris could be consistent with cells, crystals and/or exfoliated material.
- Mild left adrenomegaly

15 lbs

INTERPRETED BY

Andrea Nicastro, DMV,
Diplomate DACVIM
(Small Animal
Internal Medicine)

INTERPRETATION OF THE FINDINGS & FURTHER RECOMMENDATIONS

IMAGING PERFORMED BY

Judy Schroeder

- Three-view thoracic radiographs are recommended to assess for pulmonary metastases.
- A fine-needle aspirate of the liver can be considered, if clotting status is appropriate. A 25-gauge needle should be used. However, given the diffuse hepatic pathology and the high suspicion of neoplasia, the prognosis for this patient is considered guarded.

HOSPITAL NAME

Animal Health
Associates

REFERRING VET

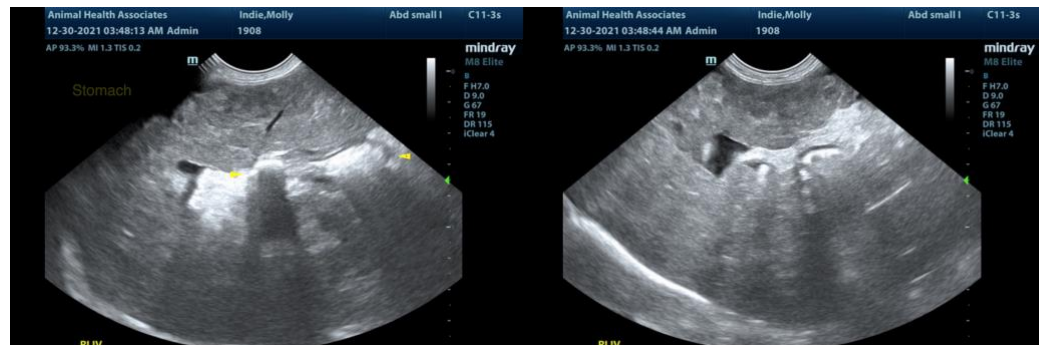
Judy Schroeder

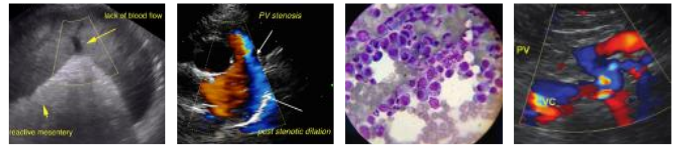
INVOICE

10101

DATE

12/31/21





PATIENT

Molly Indie

SPECIES

Canine

BREED

Bichon Frise

SEX

Spayed Female

AGE

12 Years

WEIGHT

15 lbs

INTERPRETED BY

Andrea Nicastro, DMV,
Diplomate DACVIM
(Small Animal
Internal Medicine)

**IMAGING
PERFORMED BY**

Judy Schroeder

HOSPITAL NAME

Animal Health
Associates

REFERRING VET

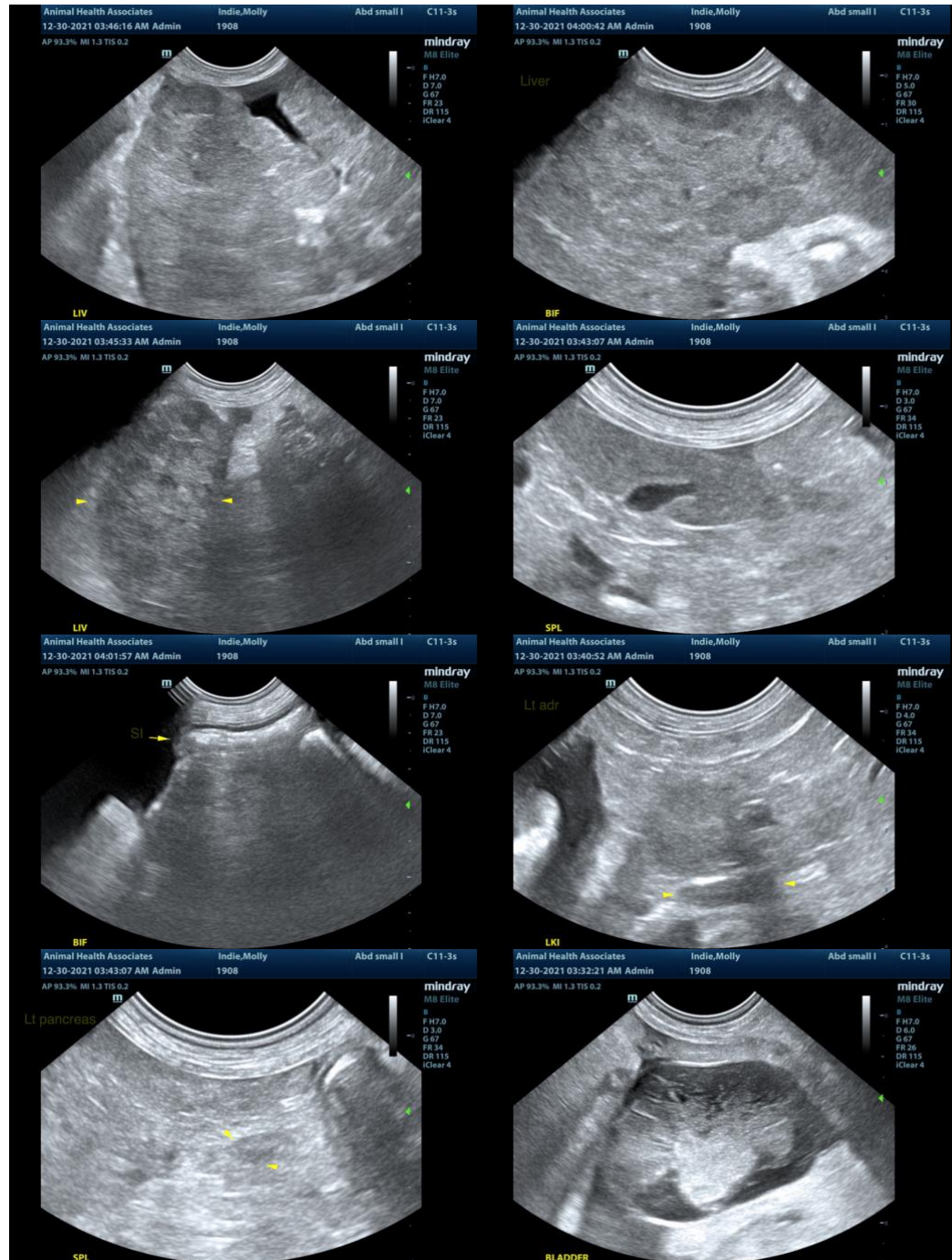
Judy Schroeder

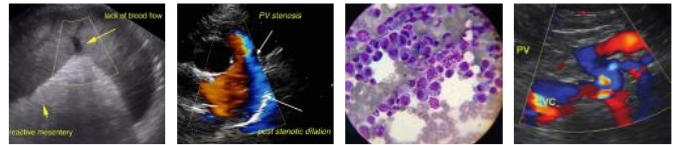
INVOICE

10101

DATE

12/31/21





PATIENT

Molly Indie

SPECIES

Canine

BREED

Bichon Frise

SEX

Spayed Female

AGE

12 Years

WEIGHT

15 lbs

INTERPRETED BY

Andrea Nicastro, DMV,
Diplomate DACVIM
(Small Animal
Internal Medicine)

**IMAGING
PERFORMED BY**

Judy Schroeder

HOSPITAL NAME

Animal Health
Associates

REFERRING VET

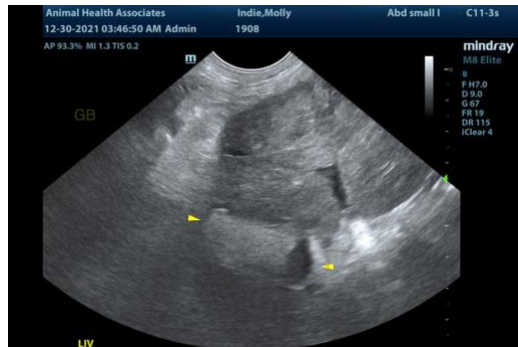
Judy Schroeder

INVOICE

10101

DATE

12/31/21



The information and recommendations provided are based on the images presented by the referring veterinarian. No evaluation can be communicated regarding pathology that was not visible in the image/video clips provided.

Thank you for this referral. If the clinical or image interpretation does not parallel your findings or if I can be of any further assistance please contact me.

Andrea Nicastro, DVM, Diplomate DACVIM (Small Animal Internal Medicine)
info@SonoPath.com