

**DATE**

12/30/21

PRESENTING CLINICAL SIGNS

History: Hx of chronic GI flare episodes where P seems uncomfortable, excessive "downward dog" stretching, retching and mild vomiting.

PATIENT

Joey Hector

Current Medications: Antronex bid, krill 1/2c bid, Lactoquil sid, Dermaquin sid, Perio powder SID, Gastrointestinal supportive in-patient therapy: anti-emetic - Cerenia 2mg/kg/d disp 24mg 4pk - 1/2 t SID, Analgesia- Tramadol 2mg/kg bid - disp 6 - give 1/4th t tid 3d, then bid thereafter, Diet- PR select prt disp; Visbiome 1 c SID.

SPECIES

Canine

Lab Results: Chem: WNL, CBC: low PDW, NOSF, spec cpli: Positive, Cobalamin: WNL 395, however low normal - low consistent w/SI dysbiosis, Folate: WNL - no clinical significance, Tli: WNL - no clinical significance, Pli: WNL - no clinical significance, Cortisol: WNL 1.5, however low end of normal- low consistent w/possible hypocorticism disease. Attached separately. 40x negative.

BREED

Rat Terrier

Radiographs: abdomen radiographs - decreased serosal detail around cranial abdomen w/thickened intestinal mucosa SI, digesta w/in stomach dilated, scant debris w/in SI, diaphragm intact, liver and spleen normal, urinary bladder normal, spine nsf, kidneys normal. NOSF.

SEX

Spayed Female

Date of Previous IntraPet Ultrasound: No previous IntraPet scans.

Sedation: Not required to complete full diagnostic ultrasound.

Stat Report: Not requested.

AGE

02/04/12

ULTRASONOGRAPHIC EXAMINATION OF THE ABDOMEN**WEIGHT**

15.5 Lbs.

Urinary System

The urinary bladder, trigone, and pelvic urethra are normal in thickness and the mucosal surface is smooth. The bladder lumen is moderately distended with anechoic urine. No masses, inflammatory changes or calculi are observed. Ureteral papillae and visualized portion of the proximal urethra, visible to a depth of 2 cm, are normal.

INTERPRETED BY

Andrea Nicastro,
DMV, Diplomate
DACVIM (Small
Animal
Internal Medicine)

The left kidney is normal size (4.23 cm in length); normal shape and architecture with smooth peripheral margins. There is a normal 1:3 cortex to medulla ratio with minimal to mild loss of corticomedullary distinction. There is no evidence of pyelectasia, nephroliths, infarcts or hydronephrosis. Renal vasculature is normal.

IMAGING PERFORMED BY

Stephanie Pearce
RDCS, RVT.

The right kidney is normal size (4.55 cm in length); normal shape and architecture with smooth peripheral margins. There is a normal 1:3 cortex to medulla ratio with minimal to mild loss of corticomedullary distinction. There is no evidence of pyelectasia, nephroliths, infarcts or hydronephrosis. Renal vasculature is normal.

HOSPITAL NAME

Happy Tails
Veterinary Hospital

Adrenal Glands

The left adrenal gland is mildly enlarged (0.88 cm at cranial pole) (0.73 cm at caudal pole) (2.27 cm in length); with a normal shape and smooth peripheral contours. The parenchyma is slightly heterogenous in appearance. No distinct focal lesions are observed. The phrenicoabdominal vein and surrounding vasculature are normal.

REFERRING VET

Dr. Calpeno

The right adrenal gland is mildly enlarged s (0.68 cm at cranial pole) (0.75 cm at caudal pole) (2.01 cm in length); with a normal shape and smooth peripheral contours. The parenchyma is slightly heterogenous in appearance. No distinct focal lesions are observed. The phrenicoabdominal vein and surrounding vasculature are normal.

INVOICE

10094

Spleen

The spleen is normal in size (1.37 cm in width at the level of the hilus) with a normal capsular

contour. There is appropriate echogenicity and echotexture. A 0.52 x 0.46 cm hyperechoic nodule is visualized. Splenic vasculature is normal.

Liver

The liver is subjectively normal in size with normal contours and structure. There is appropriate echogenicity and echotexture. No overt structural evidence of inflammatory, infiltrative or regenerative pathology is evident. Vascular and biliary tracts are of normal volume with no evidence of congestion. No pathological hepatic lymphadenopathy observed.

The gall bladder lumen is moderately distended. The wall is thin and smooth. A moderate amount of gravity dependent hyperechoic debris is observed within the lumen. The cystic and common bile ducts are normal.

Gastrointestinal

The stomach and intestine are free of stasis and exhibit normal peristaltic activity. The gastric lumen is not distended. The gastric wall and pylorus are normal in thickness with a normal layering pattern. The small intestinal lumen is segmentally dilated gas and chyme. The small intestinal wall thickness is normal with a normal layering pattern and appropriate mural detail. There is slight disruption in the normal 1:3 muscularis to mucosal ratio in some segments. Discreet masses are not identified. The colonic wall is normal. There is no evidence of an obstructive pattern.

Pancreas

The region of the pancreas is isoechoic relative to surrounding omental fat. No obvious parenchymal abnormalities are observed. There is no evidence of regional inflammation or effusion.

Free Abdomen

The peritoneal cavity is normal. There is no evidence of inflammation or effusion. The abdominal lymph nodes are normal/not visible.

ULTRASONOGRAPHIC FINDINGS

Primary Findings

- The small intestinal wall changes could be consistent with inflammatory bowel disease or may be a normal variant for this patient.
- There is no gross evidence of pancreatitis at this time. However, mild/microscopic pancreatitis cannot be completely excluded.

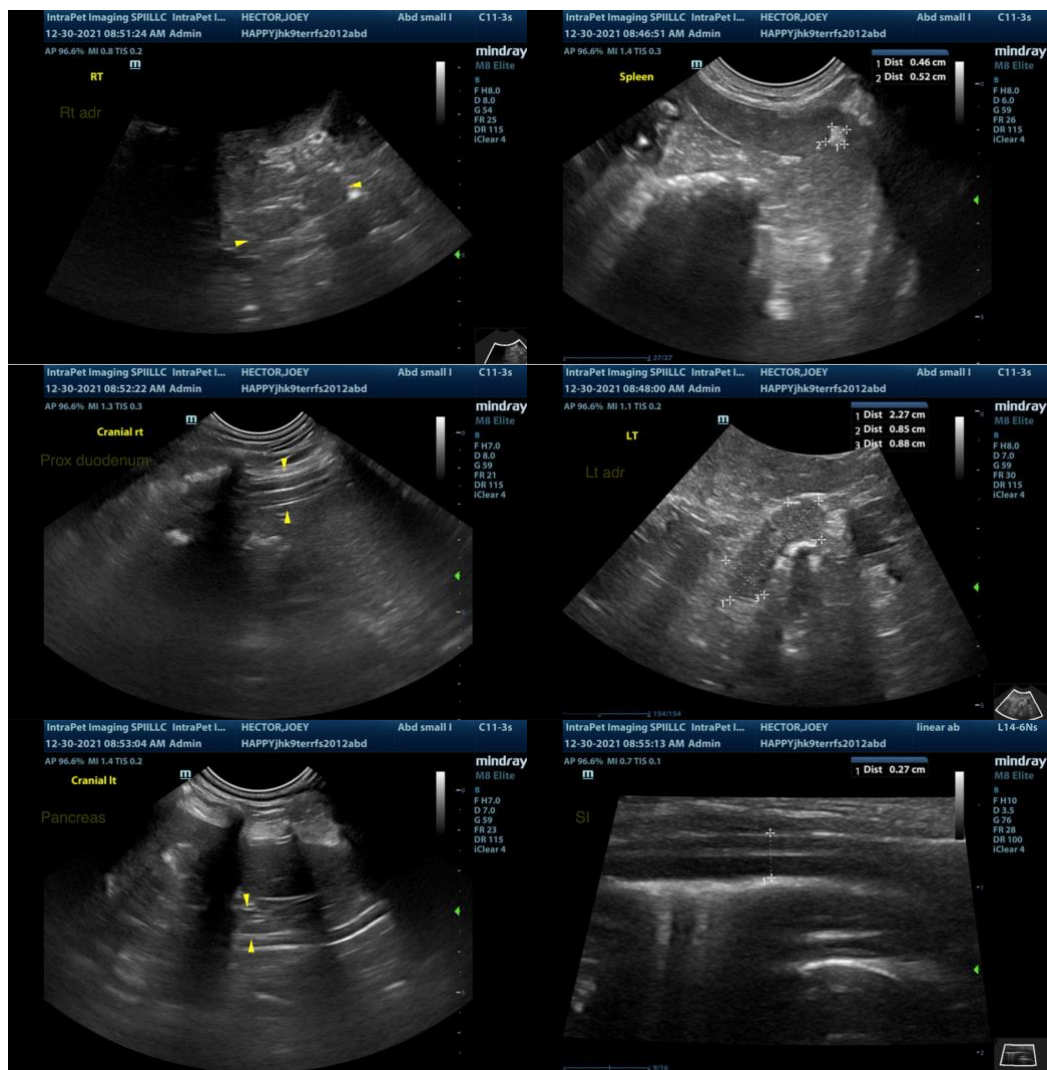
Secondary Findings

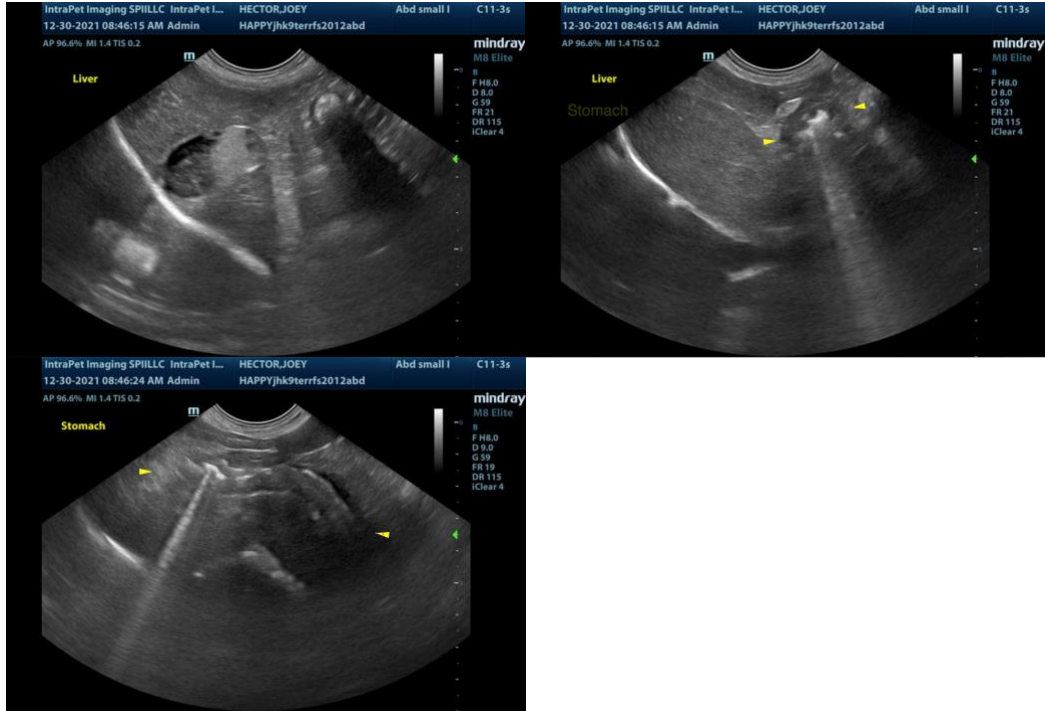
- Mild bilateral adrenomegaly.
- The hyperechoic splenic nodule trends toward the benign (i.e., myelolipoma), with a low possibility of emerging neoplasia.
- Minor age-related renal changes

INTERPRETATION OF THE FINDINGS & FURTHER RECOMMENDATIONS

- Given the chronicity of the GI signs, consider a more advanced workup, including the following:
 1. Fecal evaluation for ova and Giardia

2. ACTH stimulation test to further assess for hypoadrenocorticism, although this is unlikely given the mild bilateral adrenomegaly.
 3. A 6-week limited antigen diet trial to assess for food allergies
 4. Three-view thoracic radiographs to assess for occult esophageal disease
 5. Ultimately, endoscopic or surgical gastrointestinal biopsies may be necessary to get a definitive diagnosis.
- Given the borderline low cobalamin level, B12 supplementation is recommended.





The information and recommendations provided are based on the images presented by the referring veterinarian. No evaluation can be communicated regarding pathology that was not visible in the image/video clips provided.

Thank you for this referral. If the clinical or image interpretation does not parallel your findings or if I can be of any further assistance please contact me.

Andrea Nicastro, DVM, Diplomate DACVIM (Small Animal Internal Medicine)
info@SonoPath.com