



## DATE PRESENTING CLINICAL SIGNS

12/3/25

**Patient History:** Boomer is presented by his pet sitters for an acute onset of clinical signs today. He did not eat his dinner, has had loose stools, and is exhibiting a head tilt and difficulty walking, described as dragging his feet. The patient is approximately 9-10 years old (born in 2016). Appetite: DECREASED/ANOREXIC Drinking: Vomiting: None reported Diarrhea: YES, loose stools reported. Regular Diet: Coughing: None reported Sneezing: None reported Activity Level : DECREASED Lifestyle: Exposure to Ticks: Current Medications: Flea/Tick Prevention: Heartworm Prevention: History of vaccine reactions or medication reactions: Client Concerns: The pet sitters are concerned about the patient's sudden onset of anorexia, loose stool, lethargy, ataxia, and head tilt.

## PATIENT

Boomer Johnson

## SPECIES

Canine

## BREED

Golden Retriever

## SEX

Male, neutered

## AGE

12/2/2016

## WEIGHT

63.3 lbs.

## INTERPRETED BY

Andrea Nicastro, DVM,  
Diplomate ACVIM  
(Small Animal Internal  
Medicine)

## HOSPITAL NAME

Animal Emergency  
Hospital

## REFERRING VET

Dr. Kalinowski

## INVOICE

13413

**Current Medications:** Ondansetron, Buprenorphine, Cerenia,

**Labwork Results:** Labwork: AFAST/TFAST- moderate FF in abdomen, non-clotting blood; mild regenerative anemia, mild thrombocytopenia with normal coags. Hematocrit 36.8%, mild neutrophilia, chem panel WNL

**Date of Previous IntraPet Ultrasound:** No previous.

**Sedation:** Not required to complete full diagnostic ultrasound.

**Stat Report:** STAT requested.

**Imaging Performed by:** Rachel Brillhart, RDMS.

## ULTRASONOGRAPHIC EXAMINATION OF THE ABDOMEN

### Urinary System

The urinary bladder wall is normal in thickness and the mucosal surface is smooth. The bladder is moderately distended. Luminal contents are anechoic. No cystic calculi are observed. The region of the trigone and the visible portion of the proximal urethra, visible to a depth of 2 cm, are normal.

The prostate is normal in size (1.26 cm in width) and shape. Parenchyma is homogenous. The prostatic urethra appears normal without evidence of dilation or obstruction.

The left kidney is normal in size (6.38 cm in length) with a normal shape, architecture and smooth peripheral margins. There is a normal 1:3 cortex to medulla ratio with minimal to mild loss of corticomedullary distinction. There is no evidence of pyelectasia, nephroliths, infarcts or hydroureter. Renal vasculature is normal.

The right kidney is normal in size (7.27 cm in length) with a normal shape, architecture and smooth peripheral margins. There is a normal 1:3 cortex to medulla ratio with minimal to mild loss of corticomedullary distinction. There is no evidence of pyelectasia, nephroliths, infarcts or hydroureter. Renal vasculature is normal.

### Adrenal Glands

The left adrenal gland is normal in size (0.61 cm at cranial pole) (0.64 cm at caudal pole) with a normal shape and homogenous parenchyma. The glandular echogenicity and detail are unremarkable. Capsule, cortex, and medullary definition are normal. The phrenicoabdominal vein and surrounding vasculature are normal.

The right adrenal gland is normal in size (0.75 cm at cranial pole) (0.67 cm at caudal pole) with a normal shape and homogenous parenchyma. The glandular echogenicity and detail are unremarkable. Capsule, cortex, and medullary definition are normal. The phrenicoabdominal vein and surrounding vasculature are normal.

### Spleen

An approximately 5.3 x 3.9 cm irregular heterogeneous slightly cavitated mass is arising from the lateral margin at the mid to caudal aspect. Surrounding mesentery is hyperechoic. In the remainder of the spleen, the

margins are curvilinear and the parenchyma is relatively homogeneous. Splenic vasculature is normal with no evidence of thrombosis.

### ***Liver***

The liver is subjectively normal in size with normal curvilinear peripheral contours. The parenchyma is hypoechoic relative to the spleen and slightly mottled in appearance. No distinct focal lesions are observed. Hepatic vasculature and intrahepatic biliary tracts are of normal volume with no evidence of congestion.

The gallbladder is of normal contours and contains some dependent echogenic debris. The wall is normal in thickness. No choleliths are observed. The cystic and common bile ducts are normal.

### ***Gastrointestinal***

The gastric lumen is gas distended. The gastric wall is normal in thickness with a normal layering pattern. The small intestinal lumen is not dilated. The small intestinal wall thickness is normal with a normal layering pattern and appropriate mural detail. Discreet masses are not identified. The colonic wall is normal. There is no evidence of an obstructive pattern.

### ***Pancreas***

The region of the pancreas is isoechoic relative to surrounding omental fat. No obvious parenchymal abnormalities are observed. There is no evidence of regional inflammation or effusion.

### ***Lymph nodes***

The abdominal lymph nodes are normal/not visible.

### ***Free Abdomen***

A small amount of free fluid is present.

### ***Other***

A brief echocardiogram reveals no evidence of pericardial effusion or obvious right atrial/auricular mass.

## **ULTRASONOGRAPHIC FINDINGS**

### **Primary Findings:**

- Splenic mass, likely ruptured. Neoplasia (i.e., hemangiosarcoma, hemangioma) is suspected with a lower possibility of a non-neoplastic process. Adjacent peritonitis is present.
- The hepatic parenchymal changes are non-specific and could be secondary to age-related parenchymal remodeling, regenerative nodular hyperplasia, micrometastatic disease, other.

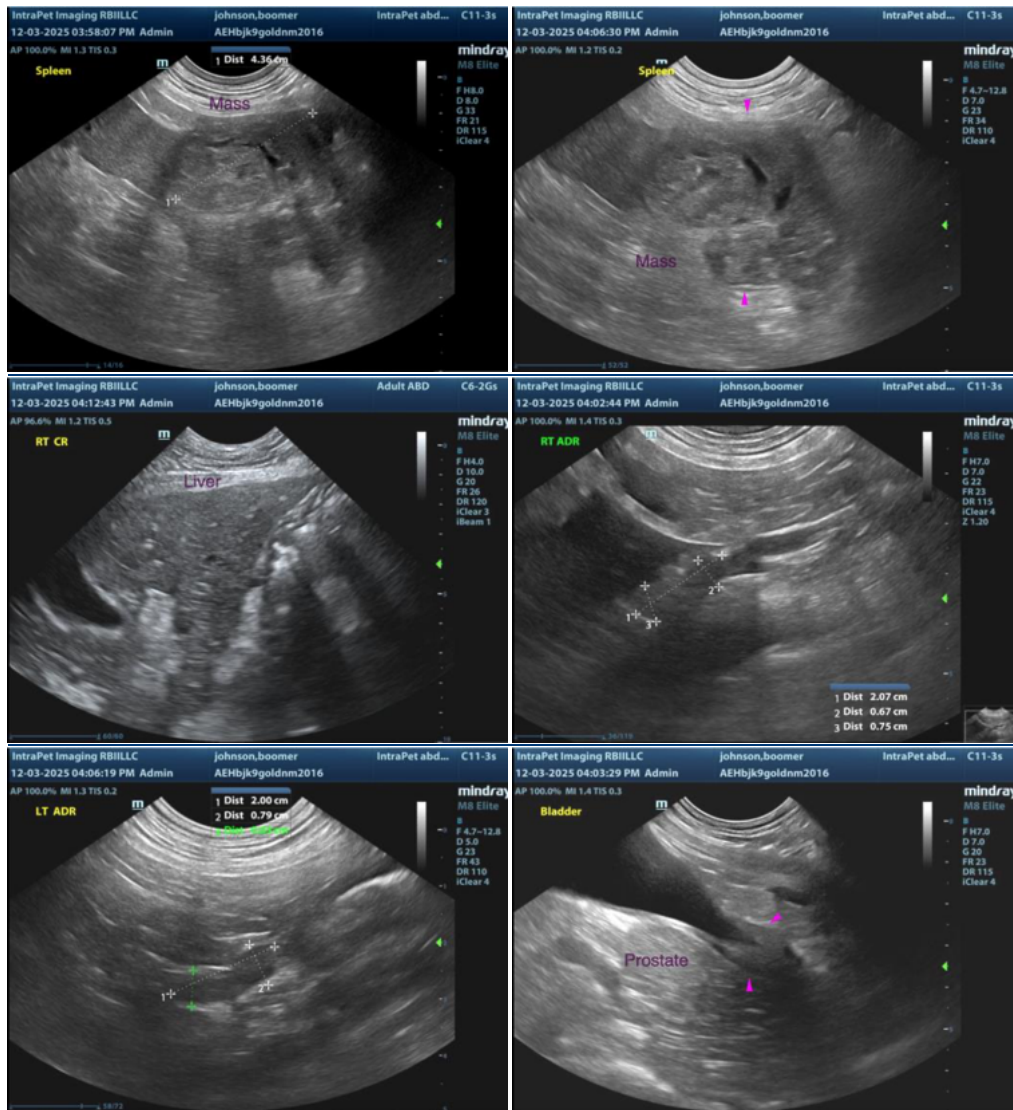
### **Secondary Findings:**

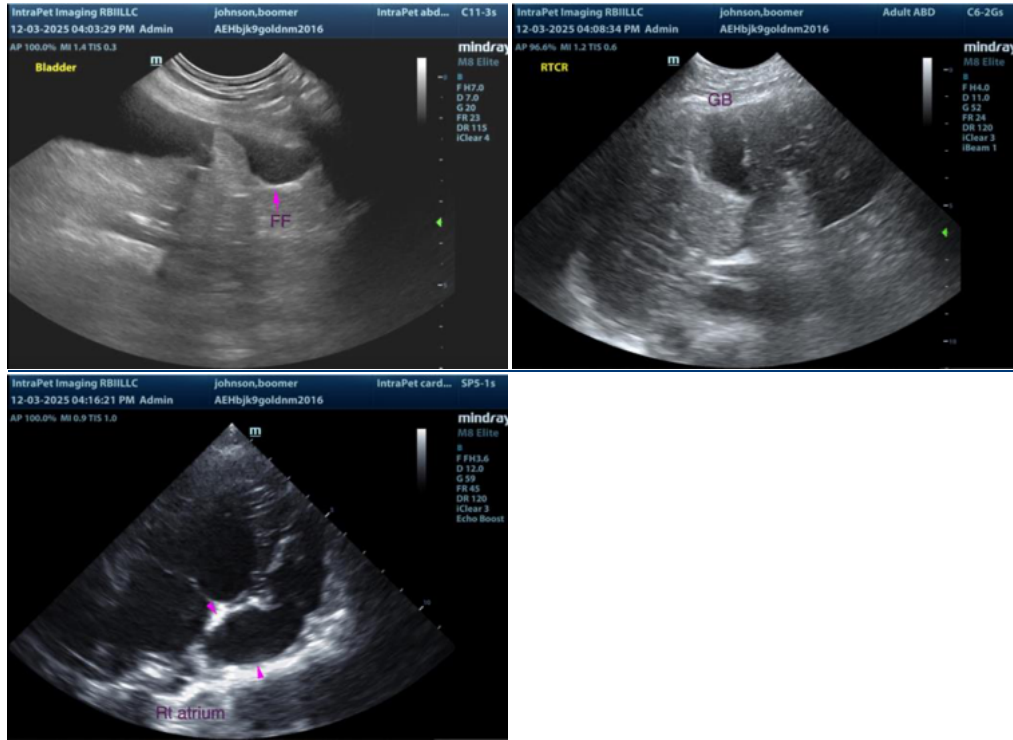
- Gallbladder debris, non-mucocele
- Minor bilateral age-related renal changes

## **INTERPRETATION OF THE FINDINGS & FURTHER RECOMMENDATIONS**

1. Three-view thoracic radiographs are recommended to assess for pulmonary metastases.

2. If there is no evidence of pulmonary metastatic disease, a splenectomy with submission of the spleen for histopathology can be considered. If pursued, liver biopsies should be obtained at the time of surgery to assess for micrometastatic disease.
3. Given the patient's neurologic signs, also consider a neurology consultation +/- brain MRI along with a baseline blood pressure measurement and thyroid level.





The information and recommendations provided are based on the images presented by the referring veterinarian/sonographer. No evaluation can be communicated regarding pathology that was not visible in the image/video clips provided.

Thank you for this referral. If the clinical or image interpretation does not parallel your findings or if I can be of any further assistance please contact me.

Andrea Nicastro, MPH, DVM, Diplomate DACVIM (Small Animal Internal Medicine) [info@SonoPath.com](mailto:info@SonoPath.com)