**PATIENT**

Champ Bryson

**PRESENTING CLINICAL SIGNS**

History: Previously diagnosed with an immune mediated disorder.

**SPECIES**

Canine

Abnormal PE/Chem/CBC/UA Results: Albumen 2.6. Globulin 3.9. ALT 142. ALP 145. tBili .5. Hematocrit is 15%. 68 nucleated red blood cells. Thrombocytopenia. T4 .7. 4dx negative. Elevated reticulocyte count. Possible splenic mass palpated on exam. Based on attached labs concerned for a bleed.

**BREED**

Terrier Mix

**ULTRASONOGRAPHIC EXAMINATION OF THE ABDOMEN****Urinary System**

The urinary bladder and visible portion of the pelvic urethra are normal for the degree of luminal distension. The urine is anechoic with no evidence of debris. Cystic calculi and discrete masses are not observed. The region of the trigone and the visible portion of the proximal urethra are normal.

**SEX**

Neutered Male

The prostate is normal in size (1.41 cm in width) and shape. Parenchyma is homogenous. The prostatic urethra appears normal without evidence of dilation or obstruction.

**AGE**

9 years

The left kidney is normal size (7.04 cm in length) with a normal shape, architecture and smooth peripheral margins. There is a normal 1:3 cortex to medulla ratio with normal corticomedullary distinction. There is no evidence of pyelectasia, nephroliths, infarcts or hydroureter.

**WEIGHT**

48.8 lbs

The right kidney is normal size (7.89 cm in length) with a normal shape, architecture and smooth peripheral margins. There is a normal 1:3 cortex to medulla ratio with normal corticomedullary distinction. There is no evidence of pyelectasia, nephroliths, infarcts or hydroureter.

**Adrenal Glands**

The left adrenal gland is normal size (0.61 cm at cranial pole) (0.64 cm at caudal pole) with a normal shape and homogenous parenchyma. The glandular echogenicity and detail are unremarkable. Capsule, cortex, and medullary definition are normal. The phrenicoabdominal vein and surrounding vasculature are normal.

The right adrenal gland is normal size (1.19 cm at cranial pole) (0.74 cm at caudal pole) with a normal shape and homogenous parenchyma. The glandular echogenicity and detail are unremarkable. Capsule, cortex, and medullary definition are normal. The phrenicoabdominal vein and surrounding vasculature are normal.

**INTERPRETED BY**

Andrea Nicastro, DVM,  
Diplomate ACVIM  
(Small Animal Internal  
Medicine)

**IMAGING PERFORMED BY**

Amy Mayhew LVT

**HOSPITAL NAME**

SVS Imaging Michigan

**Spleen**

The spleen is enlarged (2.83 cm in width at the level of the hilus) with swollen peripheral contours. The parenchyma is subtly mottled in appearance. A 1.88 cm hypoechoic nodule with an ill-defined hyperechoic center is observed approximately mid-spleen. Splenic vasculature appears normal with no evidence of thrombosis.

**REFERRING VET**

North Oakland  
Visiting Veterinarian

**Liver**

The liver is subjectively prominent in size with swollen curvilinear peripheral contours. The parenchyma is isoechoic relative to the spleen and exhibits mild heterogeneity. No distinct focal lesions are observed. Hepatic vasculature and biliary tracts are of normal volume with no evidence of congestion.

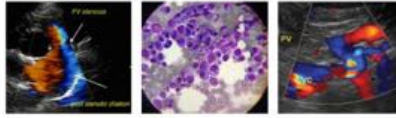
**INVOICE**

11986

The gall bladder lumen is moderately distended. The wall is thin and smooth. A small to moderate amount of partially dependent, echogenic debris is observed within the lumen. The cystic and common bile ducts are normal/not seen.

**DATE**

12.29.22



**PATIENT**

Champ Bryson

**SPECIES**

Canine

**BREED**

Terrier Mix

**SEX**

Neutered Male

**AGE**

9 years

**WEIGHT**

48.8 lbs

**INTERPRETED BY**

Andrea Nicastro, DVM,  
Diplomate ACVIM  
(Small Animal Internal  
Medicine)

**IMAGING PERFORMED BY**

Amy Mayhew LVT

**HOSPITAL NAME**

SVS Imaging Michigan

**REFERRING VET**

North Oakland  
Visiting Veterinarian

**INVOICE**

11986

**DATE**

12.29.22

**Gastrointestinal**

The gastric lumen is mildly fluid-distended. The gastric wall is diffusely thickened (up to 0.57 cm) with retention of the normal layering pattern. The pyloric outflow tract is patent. The small intestinal lumen is not dilated. The small intestinal wall thickness is normal with a normal layering pattern and appropriate mural detail. Discreet masses are not identified. The colonic wall is normal. There is no evidence of an obstructive pattern.

**Pancreas**

The region of the pancreas is isoechoic relative to surrounding omental fat. No obvious parenchymal abnormalities are observed. There is no evidence of regional inflammation or effusion.

**Free Abdomen**

Trace free fluid is observed. The abdominal lymph nodes are normal/not visible.

**Other**

A brief echocardiogram reveals a 1.95 x 1.54 cm irregular area of hyperechoic tissue in the right ventricular free wall at the level of the tricuspid valve. There is no obvious evidence of pericardial effusion.

**ULTRASONOGRAPHIC FINDINGS**

**Primary Findings**

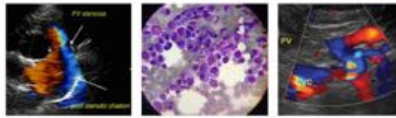
- The splenomegaly could be consistent with infiltrative neoplasia (i.e., round cell tumor). Alternatively, a benign process (i.e., lymphoid hyperplasia, extramedullary hematopoiesis, splenitis, antigenic stimulation) is possible. The splenic nodule trends toward a benign process (i.e., myelolipoma, lymphoid hyperplasia). However, an emerging tumor cannot be excluded.
- Trace ascites
- The significance of the thickened tissue at the level of the tricuspid is unclear. It may represent an emerging tumor, inflammatory tissue, other.

**Secondary Findings**

- The diffuse hepatic changes are non-specific and could be consistent with vacuolar hepatopathy, regenerative nodular hyperplasia, and/or age-related remodeling. Inflammatory and infiltrative disease are considered less likely.
- The gastric wall thickening is most consistent with an inflammatory process, with a lower possibility of emerging neoplasia.

**INTERPRETATION OF THE FINDINGS & FURTHER RECOMMENDATIONS**

- If the patient's clotting status can be stabilized, a fine needle aspirate of the spleen is recommended.
- Thoracic radiographs should also be considered to assess for occult disease in the chest.
- A comprehensive tick panel, including PCR and serology (submission to North Carolina State University's Vector Borne Disease Diagnostic Lab) is recommended.  
<https://cvm.ncsu.edu/research/labs/clinical-sciences/vector-borne-disease>
- Given the questionable thickened tissue at the level of the tricuspid valve, a full echocardiogram should be considered.



**PATIENT**

Champ Bryson

**SPECIES**

Canine

**BREED**

Terrier Mix

**SEX**

Neutered Male

**AGE**

9 years

**WEIGHT**

48.8 lbs

**INTERPRETED BY**

Andrea Nicastro, DVM,  
Diplomate ACVIM  
(Small Animal Internal  
Medicine)

**IMAGING PERFORMED BY**

Amy Mayhew LVT

**HOSPITAL NAME**

SVS Imaging Michigan

**REFERRING VET**

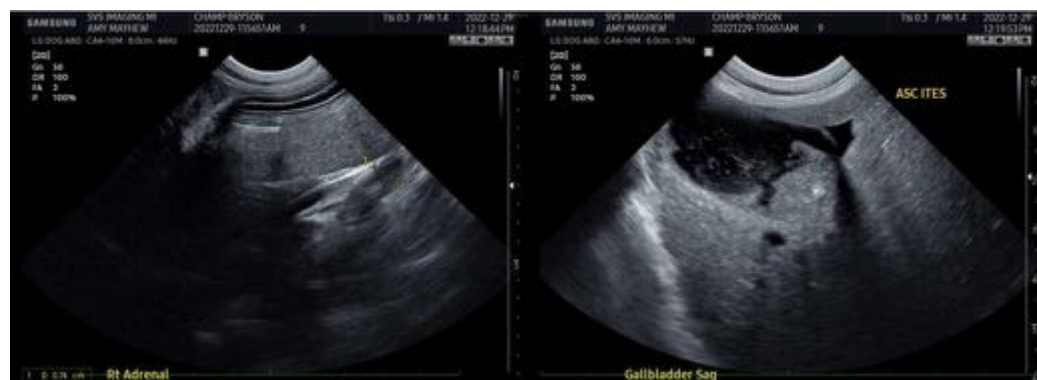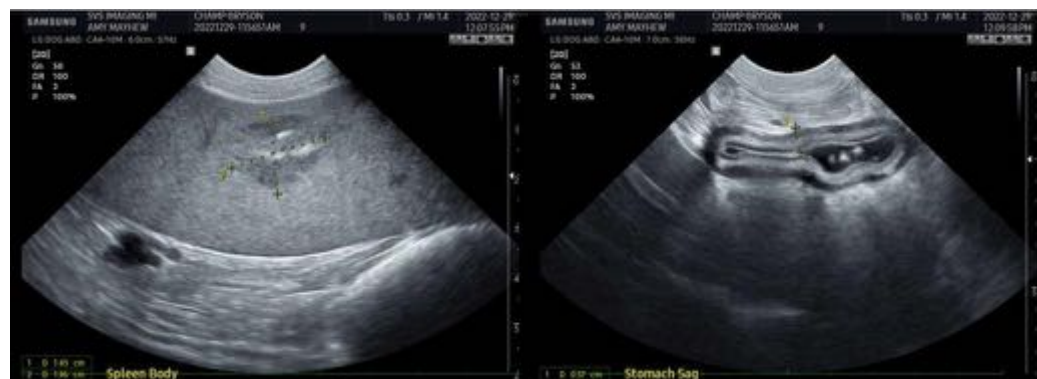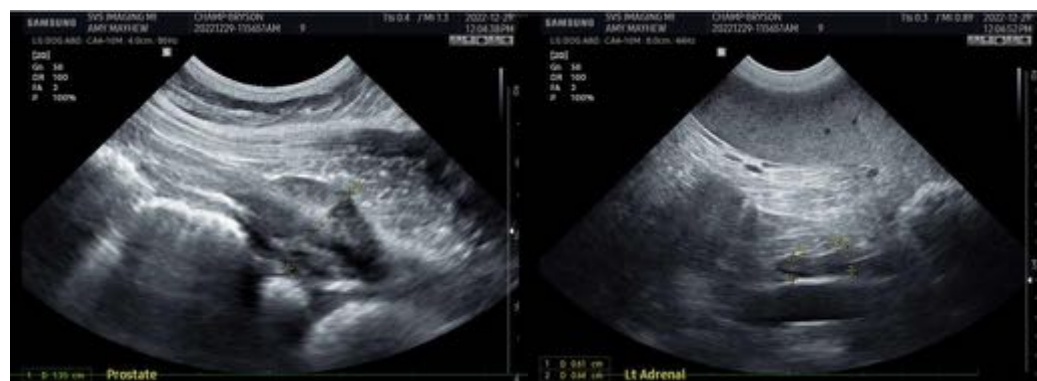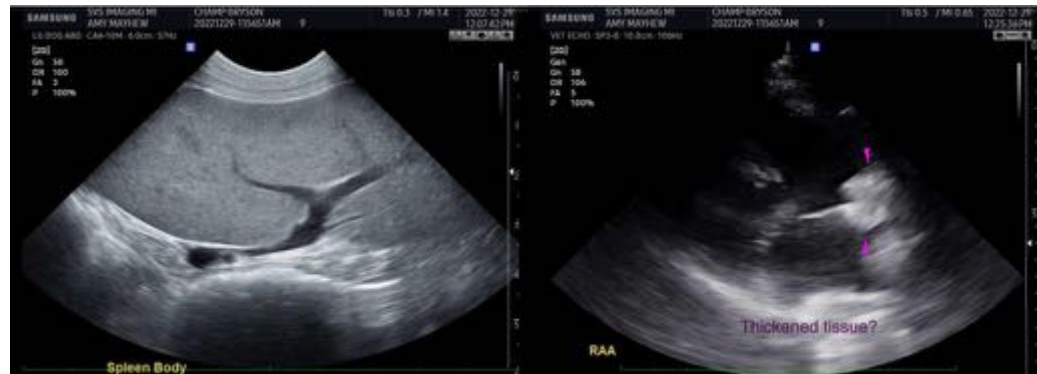
North Oakland  
Visiting Veterinarian

**INVOICE**

11986

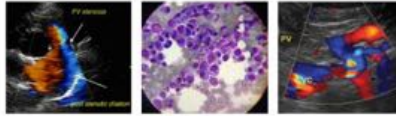
**DATE**

12.29.22



IMAGING PERFORMED BY

svsimagingqc.net 309-737-3070



Clinical Sonography & Telecytology

EDUCATIONAL TELECONSULTATION SERVICES™

1-800-838-4268 info@sonopath.com SonoPath.com

**PATIENT**

Champ Bryson

The information and recommendations provided are based on the images presented by the referring veterinarian/sonographer. No evaluation can be communicated regarding pathology that was not visible in the image/video clips provided.

**SPECIES**

Canine

Thank you for this referral. If the clinical or image interpretation does not parallel your findings or if I can be of any further assistance, please contact me.

**Andrea Nicastro, MPH, DVM, Diplomate DACVIM (Small Animal Internal Medicine)**  
[info@SonoPath.com](mailto:info@SonoPath.com)

**BREED**

Terrier Mix

**SEX**

Neutered Male

**AGE**

9 years

**WEIGHT**

48.8 lbs

**INTERPRETED BY**

Andrea Nicastro, DVM,  
Diplomate ACVIM  
(*Small Animal Internal  
Medicine*)

**IMAGING PERFORMED  
BY**

Amy Mayhew LVT

**HOSPITAL NAME**

SVS Imaging Michigan

**REFERRING VET**

North Oakland  
Visiting Veterinarian

**INVOICE**

11986

**DATE**

12.29.22