

**DATE**

12/29/21

**PRESENTING CLINICAL SIGNS**

History: Anorexia, lethargy, painful in abdomen, one episode of vomit

No know ingestion of foreign substance/object. PE: QAR, tense on abdominal palpation, temp 102.8, no other significant findings.

**PATIENT**

Penelope Mike

Current Medications: IV fluids therapy throughout day, Cerenia 10 mg/ml 2.7 mls IV, Famotidine 20 mg/ml 2.7 mls IV.

**SPECIES**

Canine

Lab Results: Chemistry WNL, CBC: mildly decreased WBC count, CPL: negative, Fecal float and smear normal.

**BREED**

Hound Mixed Breed

Date of Previous IntraPet Ultrasound: No previous IntraPet scans.

Sedation: Not required to complete full diagnostic ultrasound.

Stat Report: Not requested.

**SEX**

Spayed Female

Imaging Performed By: Andi Parkinson, RDMS

**ULTRASONOGRAPHIC EXAMINATION OF THE ABDOMEN****AGE**

12/29/17

**Urinary System**

The urinary bladder, trigone, and pelvic urethra are normal in thickness and the mucosal surface is smooth. The bladder lumen is moderately distended with anechoic urine. No masses, inflammatory changes or calculi are observed. Ureteral papillae and visualized portion of the proximal urethra, visible to a depth of 2 cm, are normal.

**WEIGHT**

60 Lbs.

The left kidney presented normal size (5.80 cm in length); normal shape and architecture with smooth peripheral margins. There is a normal 1:3 cortex to medulla ratio with normal corticomedullary distinction. There is no evidence of pyelectasia, nephroliths, infarcts or hydroureter.

The right kidney presented normal size (5.86 cm in length); normal shape and architecture with smooth peripheral margins. There is a normal 1:3 cortex to medulla ratio with normal corticomedullary distinction. There is no evidence of pyelectasia, nephroliths, infarcts or hydroureter.

**INTERPRETED BY**

Andrea Nicastro, DMV,  
Diplomate DACVIM  
(Small Animal  
Internal Medicine)

**HOSPITAL NAME**

Banfield PH of  
Towson

**Adrenal Glands**

The left adrenal gland is normal size (0.53 cm at cranial pole) (0.60 cm at caudal pole) (2.65 cm in length); normal shape; homogenous parenchyma. The glandular echogenicity and detail are unremarkable. Capsule, cortex, and medullary definition are normal. The phrenicoabdominal vein and surrounding vasculature are normal.

**REFERRING VET**

Dr. Lewis

The right adrenal gland is normal size (0.61 cm at cranial pole) (0.76 cm at caudal pole) (2.25 cm in length); normal shape; homogenous parenchyma. The glandular echogenicity and detail are unremarkable. Capsule, cortex, and medullary definition are normal. The phrenicoabdominal vein and surrounding vasculature are normal.

**INVOICE**

13243

**Spleen**

The spleen is normal in size (2.43 cm in width at the level of the hilus) with a normal capsular contour. There is appropriate echogenicity and echotexture. A 0.97 cm ill-defined hypoechoic nodule is observed at the cranial aspect. Splenic vasculature is normal.

### ***Liver***

The liver is subjectively normal in size with normal contours and structure. There is appropriate echogenicity and echotexture. No overt structural evidence of inflammatory, infiltrative or regenerative pathology is evident. Vascular and biliary tracts are of normal volume with no evidence of congestion. No pathological hepatic lymphadenopathy observed.

The gall bladder lumen is moderately distended. The wall is thin and smooth. A small amount of aggregated echogenic suspended debris is observed within the lumen. The cystic and common bile ducts are normal.

### ***Gastrointestinal***

The stomach and intestine are free of stasis and exhibit normal peristaltic activity. The gastric lumen is gas distended. The gastric wall and pylorus are normal in thickness with a normal layering pattern. The small intestinal lumen is not dilated. The small intestinal wall thickness is normal with a normal layering pattern and appropriate mural detail. There is slight disruption in the normal 1:3 muscularis to mucosa ratio in some segments. In addition, the submucosal layer is mildly thickened in some regions. Discreet masses are not identified. The colonic wall is normal. There is no evidence of an obstructive pattern.

### ***Pancreas***

The region of the pancreas is isoechoic relative to surrounding omental fat. No obvious parenchymal abnormalities are observed. There is no evidence of regional inflammation or effusion.

### ***Free Abdomen***

The peritoneal cavity is normal. There is no evidence of inflammation or effusion. A few prominent mesenteric lymph nodes are visualized, the largest measuring 3.32 cm in length. The nodes are normal in shape and echogenicity.

## **ULTRASONOGRAPHIC FINDINGS**

### **Primary Findings**

- The mild lymphadenopathy is consistent with reactive lymphadenitis or lymphoid hyperplasia.
- The small intestinal wall changes could be consistent with inflammatory bowel disease. Correlation with the patient's history is recommended.

### **Secondary Findings**

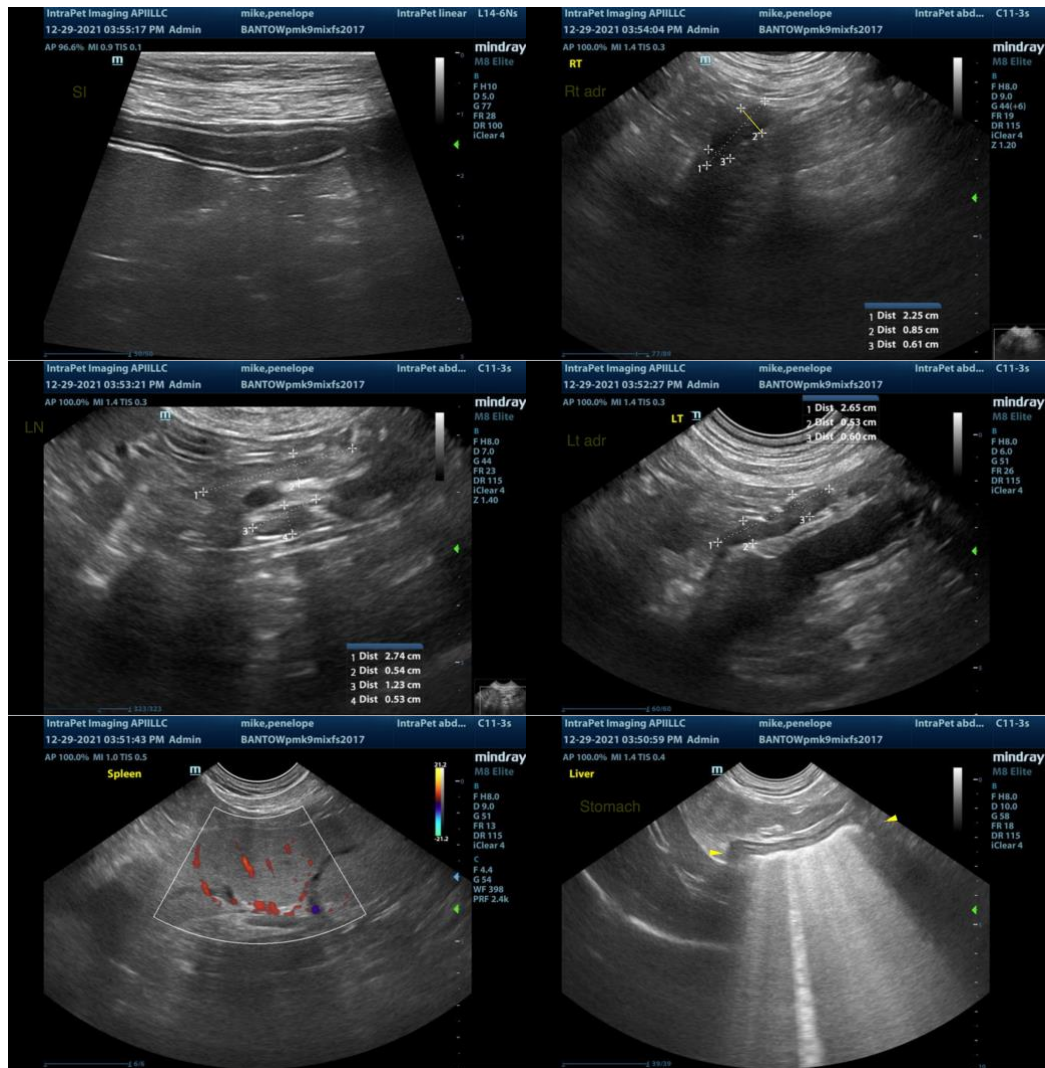
- The hypoechoic splenic nodule trends toward the benign (i.e., a focus of lymphoid hyperplasia or extramedullary hematopoiesis) with lower potential for emerging neoplasia.

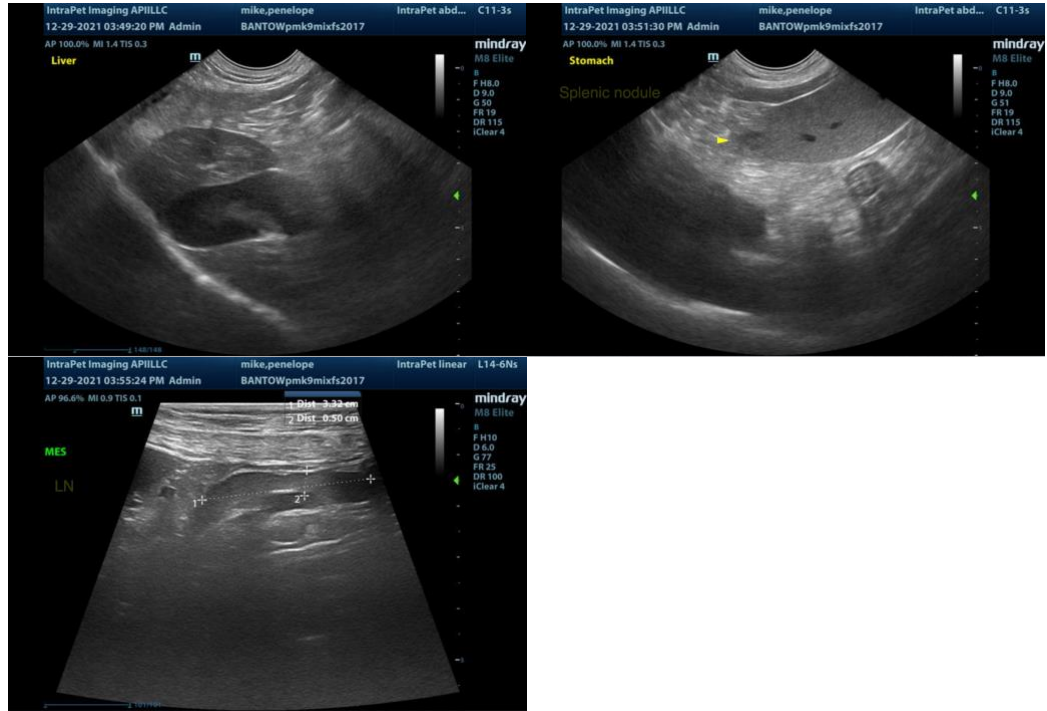
## **INTERPRETATION OF THE FINDINGS & FURTHER RECOMMENDATIONS**

- Fecal evaluation for ova and Giardia
- Continued supportive care for acute gastroenteritis is recommended.
- Given the low-grade fever, also consider three-view thoracic radiographs to assess for occult

aspiration pneumonia.

- If the patient's clinical signs do not improve within 48-72 hours of supportive care, a more advanced GI work up (i.e., malabsorption panel, resting cortisol level, hypoallergenic diet trial, +/- endoscopic or surgical gastrointestinal biopsies) may be warranted.





**The information and recommendations provided are based on the images presented by the referring veterinarian. No evaluation can be communicated regarding pathology that was not visible in the image/video clips provided.**

Thank you for this referral. If the clinical or image interpretation does not parallel your findings or if I can be of any further assistance please contact me.

**Andrea Nicastro, DVM, Diplomate DACVIM (Small Animal Internal Medicine)**  
info@SonoPath.com