



PATIENT

Crusty Stone

SPECIES

Feline

BREED

DSH

SEX

Female Spayed

AGE

1-1-2011

WEIGHT

7

INTERPRETED BY

Andrea Nicastro DVM
Diplomate ACVIM
(Sm Animal Internal Med)

**IMAGING
PERFORMED BY**

Andrea Nicastro DVM
Diplomate ACVIM
(Sm Animal Internal Med)

HOSPITAL NAME

AH of South Carolina

REFERRING VET

Matt Stone

INVOICE

22319

DATE

12-23-25

PRESENTING CLINICAL SIGNS

Patient has a history of stomatitis and full-mouth extractions, but still having oral issues. Wants ultrasound prior to referral to veterinary dentist.

ULTRASONOGRAPHIC EXAMINATION OF THE ABDOMEN

Urinary System

The urinary bladder wall is normal in thickness. The mucosal surface is smooth. The bladder is moderately distended. Luminal contents are mostly anechoic. No cystic calculi are observed. The region of the trigone is normal.

The left kidney is normal in size (3.49 cm in length) with a normal shape, architecture and smooth peripheral margins. There is a normal 1:3 cortex to medulla ratio with mild to moderate loss of corticomedullary distinction. There is no evidence of pyelectasia, nephroliths, infarcts or hydroureter. Renal vasculature is normal.

The right kidney is normal in size (3.48 cm in length) with a normal shape, architecture and smooth peripheral margins. There is a normal 1:3 cortex to medulla ratio with mild loss of corticomedullary distinction. There is no evidence of pyelectasia, nephroliths, infarcts or hydroureter. Renal vasculature is normal.

Adrenal Glands

The left adrenal gland is normal size (0.35 cm width). Normal shape and glandular echogenicity. The phrenicoabdominal vein and surrounding vasculature are normal.

The right adrenal gland is normal size (0.36 cm width). Normal shape and glandular echogenicity. The phrenicoabdominal vein and surrounding vasculature are normal.

Spleen

The spleen is normal in size (0.73 cm in width at the level of the hilus) with a normal capsular contour. Using a high-frequency probe, a light micronodular pattern is observed throughout the organ. No focal lesions are observed. Splenic vasculature is normal.

Liver

The liver is subjectively normal in size with normal curvilinear peripheral contours. The parenchyma is isoechoic relative to the spleen and diffusely homogeneous in appearance. No distinct focal lesions are observed. Vascular and biliary tracts are of normal volume with no evidence of congestion. The portal vein to caudal vena cava ratio is approximately 1: 1.

The gallbladder lumen is distended. The wall is thin and smooth. Luminal contents are anechoic. The cystic and common bile ducts are normal.

Gastrointestinal

The stomach and intestine are free of stasis and exhibit normal peristaltic activity. The gastric lumen is not distended. The gastric wall and pylorus are normal in thickness with a normal layering pattern. The pyloric outflow tract is patent. The small intestinal lumen is not dilated. The small intestinal wall thickness is normal. There is disruption in the normal 1:3 muscularis: mucosal ratio in most segments. Discreet masses are not identified. The ileocecal colic junction and colonic wall are normal. The lumen of the ascending colon contains liquid-appearing fecal material. There is no obvious evidence of an obstructive pattern.



PATIENT

Crusty Stone

SPECIES

Feline

BREED

DSH

SEX

Female Spayed

AGE

1-1-2011

WEIGHT

7

INTERPRETED BY

Andrea Nicastro DVM
Diplomate ACVIM
(Sm Animal Internal Med)

**IMAGING
PERFORMED BY**

Andrea Nicastro DVM
Diplomate ACVIM
(Sm Animal Internal Med)

HOSPITAL NAME

AH of South Carolina

REFERRING VET

Matt Stone

INVOICE

22319

DATE

12-23-25

Pancreas

The left limb of the pancreas is visible with normal curvilinear peripheral contours. The parenchyma is slightly hypoechoic relative to surrounding omental fat and slightly mottled in appearance. The pancreatic duct is visible but not overtly dilated. There is no evidence of peripancreatic inflammation or effusion.

Lymph Nodes

A few prominent mesenteric lymph nodes are visualized (one measuring 0.85 x 0.30 cm). Surrounding mesentery is hyperechoic.

Free Abdomen

There is no obvious evidence of free fluid.

Other

A brief echocardiogram reveals no obvious evidence of pericardial or pleural effusion in the visible window.

ULTRASONOGRAPHIC FINDINGS

- The splenic parenchymal changes are most consistent with a benign process such as lymphoid hyperplasia, extramedullary hematopoiesis, splenitis or antigenic stimulation with a lower possibility of infiltrative neoplasia (i.e., lymphoma, mast cell neoplasia).
- Bilateral nonspecific age-related renal changes
- The pancreatic changes are most consistent with age-related parenchymal remodeling, potentially secondary to a prior inflammatory episode, early fibrosis or chronic pancreatitis.
- The prominent abdominal lymph nodes are most consistent with reactive lymphadenitis or lymphoid hyperplasia. Neoplastic infiltration is considered less likely.
- Diarrheic stool

*There is no obvious evidence of neoplasia in the abdomen.

INTERPRETATION OF THE FINDINGS & FURTHER RECOMMENDATIONS

- Given the patient's age, consider three-view thoracic radiographs prior to any anesthetic event.
- If the patient develops gastrointestinal signs in the future, further work up (i.e., hypoallergenic diet trial, G.I. panel, +/- G.I. biopsies) may be indicated.



PATIENT

Crusty Stone

SPECIES

Feline

BREED

DSH

SEX

Female Spayed

AGE

1-1-2011

WEIGHT

7

INTERPRETED BY

Andrea Nicastro DVM
 Diplomate ACVIM
 (Sm Animal Internal Med)

IMAGING PERFORMED BY

Andrea Nicastro DVM
 Diplomate ACVIM
 (Sm Animal Internal Med)

HOSPITAL NAME

AH of South Carolina

REFERRING VET

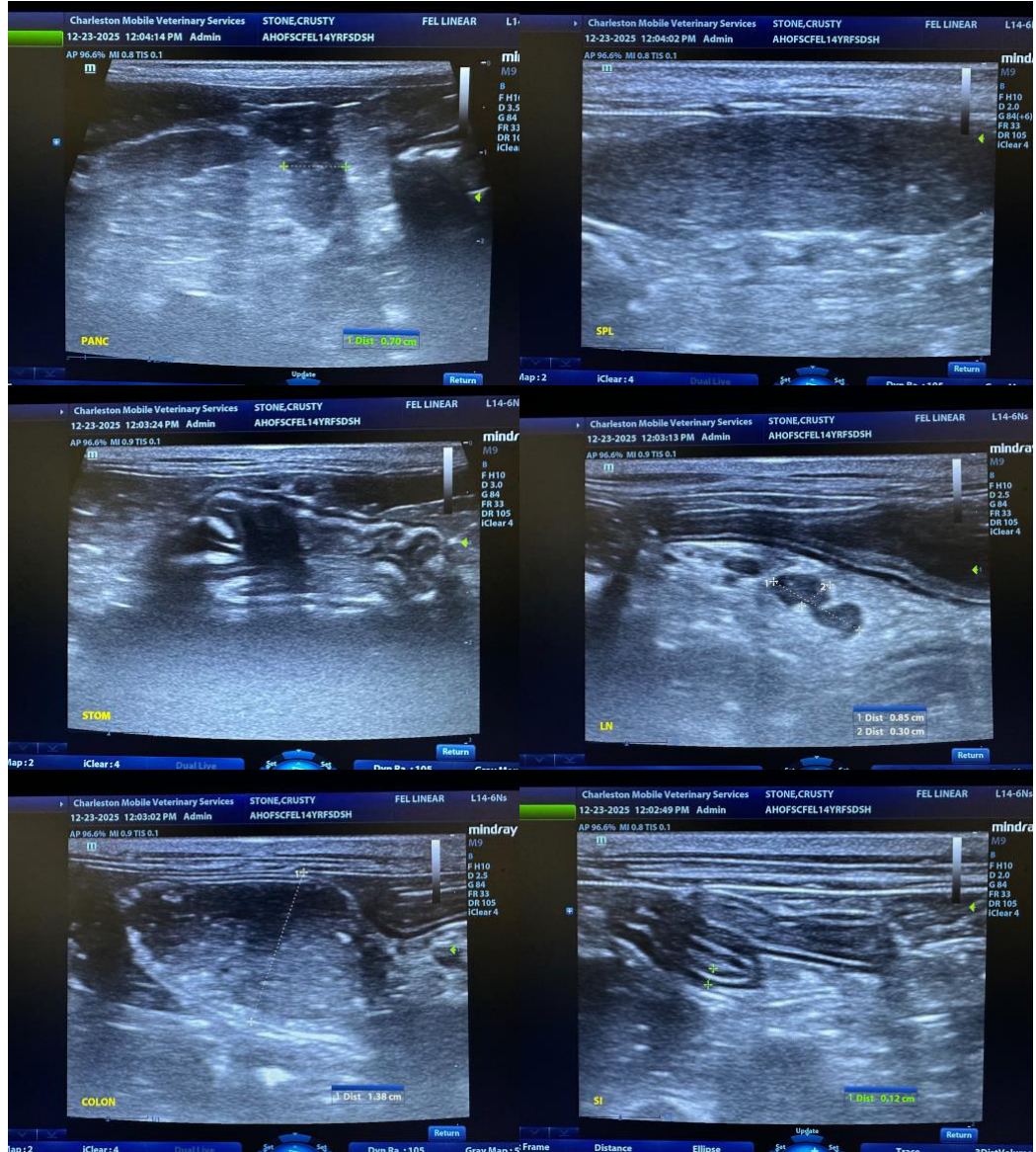
Matt Stone

INVOICE

22319

DATE

12-23-25





PATIENT

Crusty Stone

SPECIES

Feline

BREED

DSH

SEX

Female Spayed

AGE

1-1-2011

WEIGHT

7

INTERPRETED BY

Andrea Nicastro DVM
 Diplomate ACVIM
 (Sm Animal Internal Med)

IMAGING PERFORMED BY

Andrea Nicastro DVM
 Diplomate ACVIM
 (Sm Animal Internal Med)

HOSPITAL NAME

AH of South Carolina

REFERRING VET

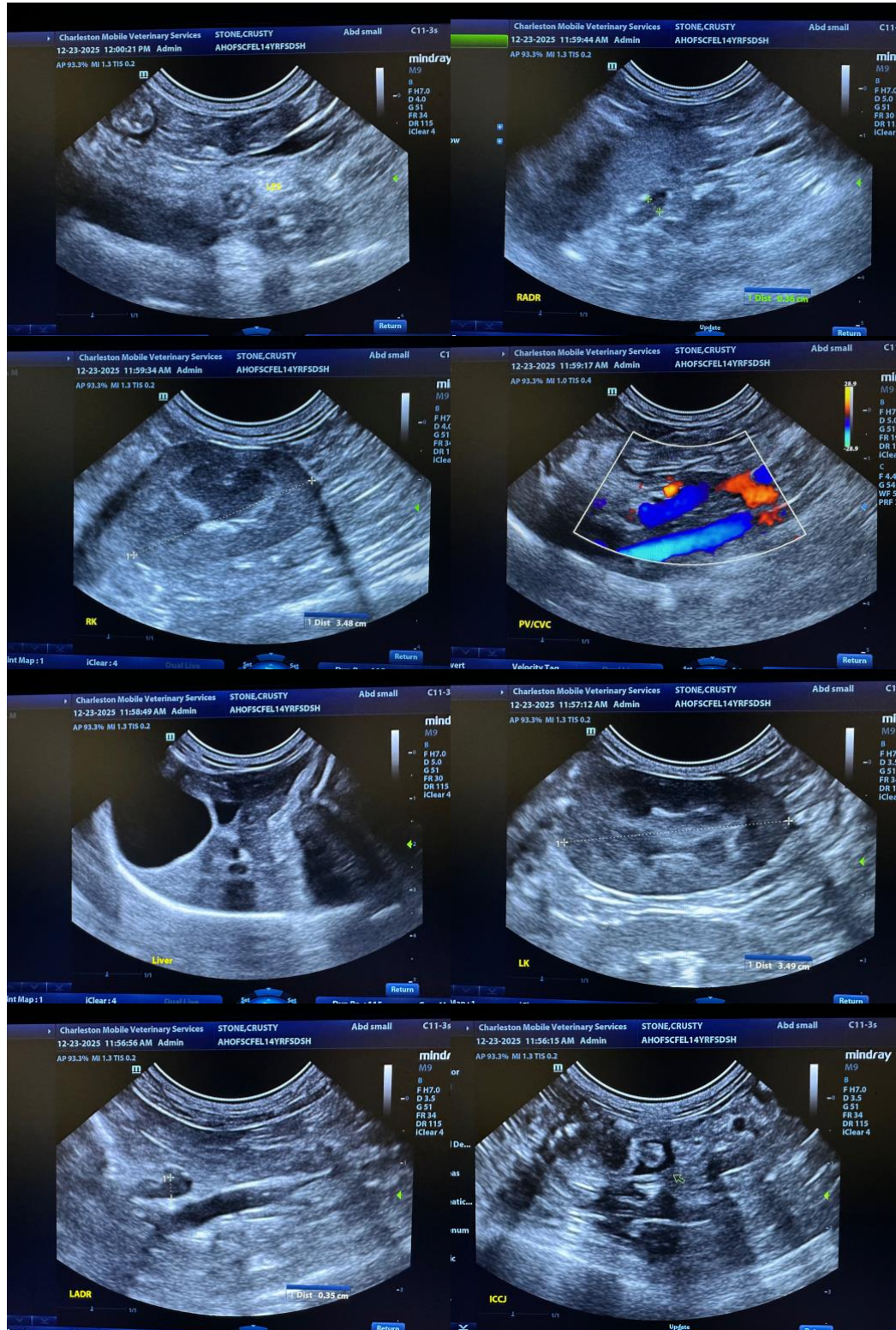
Matt Stone

INVOICE

22319

DATE

12-23-25





PATIENT

Crusty Stone

The information and recommendations provided are based on the images presented by the referring veterinarian/sonographer. No evaluation can be communicated regarding pathology that was not visible in the image/video clips provided.

SPECIES

Feline

Thank you for this referral. If the clinical or image interpretation does not parallel your findings or if I can be of any further assistance, please contact me.

BREED

DSH

Andrea Nicastro, MPH, DVM, Diplomate DACVIM (Small Animal Internal Medicine)
info@SonoPath.com

SEX

Female Spayed

AGE

1-1-2011

WEIGHT

7

INTERPRETED BY

Andrea Nicastro DVM
Diplomate ACVIM
(Sm Animal Internal Med)

**IMAGING
PERFORMED BY**

Andrea Nicastro DVM
Diplomate ACVIM
(Sm Animal Internal Med)

HOSPITAL NAME

AH of South Carolina

REFERRING VET

Matt Stone

INVOICE

22319

DATE

12-23-25