

**PATIENT PRESENTING CLINICAL SIGNS**

**Lebowski Perry**  
**SPECIES** Canine  
**BREED** Puli  
**SEX** Neutered Male  
**AGE** 10  
**WEIGHT** 15.2 kg

**History:** Severe Hepatopathy and Severe Pancreatitis - This is suspected based on the combination of clinical signs including lethargy, inappetence, vomiting, PD, PU, weight loss, and scleral icterus. Blood work results revealing severely elevated liver values support this assessment. Pancreatitis is also suspected given the clinical presentation. Harsh Lung Sounds (Left Side) - DDx: Aspiration pneumonia (secondary to vomiting), bronchitis, inflammatory airway disease, neoplasia. This finding requires further monitoring. Significant Weight Loss and Muscle Atrophy - These findings are considered secondary to the underlying systemic disease process, contributing to the patient's debility. Anxiety and Reactivity - This is a known behavioral comorbidity that complicates handling, examination, and treatment

Current Medications Mirtazapine 15mg tabs - 1 tablet once daily. Cerenia 60mg - 1/2 tab once daily.

**Abnormal PE/Chem/CBC/UA Results:** ALT too high to read ALK P and GGT severely elevated T.Bil Severely elevated T.Protein and globulins elevated - secondary to inflammation and dehydration Amylase and Lipase severely elevated Pancreatic Lipase severely elevated (>2000) UA: 1.020, severe bilirubin and urobilinogen  
Lepto In house Witness test: NEGATIVE  
Radiographic Findings n/a Primary Question to Be Answered in This Examination: More in detail evaluation of the liver and abdomen organs

**ULTRASONOGRAPHIC EXAMINATION OF THE ABDOMEN**

**Urinary System**

The urinary bladder wall is normal in thickness. The mucosal surface is smooth. The bladder is moderately distended. A scant amount of suspended echogenic debris is observed within the lumen. No cystic calculi are observed. The region of the trigone and the proximal urethra, visible to a depth of 2 cm, are normal.

The prostate is normal in size (1.14 cm in width) and shape. Parenchyma is homogenous. The prostatic urethra appears normal without evidence of dilation or obstruction.

The left kidney is normal in size (6.01 cm in length) with a normal shape, architecture and smooth peripheral margins. There is a normal 1:3 cortex to medulla ratio with minimal to mild loss of corticomedullary distinction. There is no evidence of pyelectasia, nephroliths, infarcts or hydroureter. Renal vasculature is normal.

The right kidney is normal in size (5.96 cm in length) with a normal shape, architecture and smooth peripheral margins. There is a normal 1:3 cortex to medulla ratio with mild loss of corticomedullary distinction. There is no evidence of pyelectasia, nephroliths, infarcts or hydroureter. Renal vasculature is normal.

**Adrenal Glands**

The left adrenal gland is normal in size (0.55 cm at cranial pole) (0.60 cm at caudal pole) with a normal shape and homogenous parenchyma. The glandular echogenicity and detail are unremarkable. Capsule, cortex, and medullary definition are normal. The phrenicoabdominal vein and surrounding vasculature are normal.

The right adrenal gland is normal in size (1.18 cm at cranial pole) (0.55 cm at caudal pole) with a normal shape and homogenous parenchyma. The glandular echogenicity and detail are unremarkable. Capsule, cortex, and medullary definition are normal. The phrenicoabdominal vein and surrounding vasculature are normal.

**Spleen**

The spleen is normal in size (1.39 cm in width at the level of the hilus) with a normal capsular

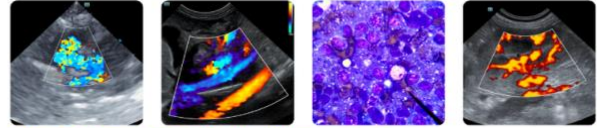
**INTERPRETED BY**  
Andrea Nicastro DVM  
Diplomate ACVIM  
(Sm Animal Internal Med)

**IMAGING PERFORMED BY**  
Amanda Stewart

**HOSPITAL NAME**  
Beatties SC

**REFERRING VET**  
Mellish

**INVOICE**  
22309  
**DATE**  
12-22-25



**PATIENT**

contour. There is appropriate echogenicity and echotexture. No focal lesions are observed. Splenic vasculature is normal.

Lebowski Perry

**SPECIES**

**Liver**

The liver is subjectively enlarged, with irregular peripheral contours. A >8.0 cm heterogenous mass is observed approximately mid-liver, and is seen surrounding the gallbladder. The remaining parenchyma is homogenous. Hepatic vasculature and intrahepatic biliary tracts are of normal volume with no evidence of congestion.

Canine

**BREED**

The gallbladder is contracted. The wall is appropriate thickness for the level of repletion. A small amount of echogenic-to-mineralized debris/sand is observed within the lumen. The cystic and common bile ducts are not seen.

Puli

**SEX**

**Gastrointestinal**

The gastric lumen is not distended. The gastric wall and pylorus are normal in thickness with a normal layering pattern. The pyloric outflow tract is patent. The small intestinal lumen is not dilated. The small intestinal wall is normal in thickness with a normal layering pattern and appropriate mural detail. Discreet masses are not identified. The colonic wall is normal. There is no evidence of an obstructive pattern.

Neutered Male

**AGE**

10

**WEIGHT**

**Pancreas**

The pancreas is diffusely visible/prominent with minimal deviation from the normal peripheral contours. The parenchyma is variable in its echogenicity/heterogenous in appearance. The pancreatic duct is not overtly dilated.

15.2 kg

**INTERPRETED BY**

**Lymph Nodes**

The abdominal lymph nodes are normal/not visible.

Andrea Nicastro DVM  
Diplomate ACVIM  
(Sm Animal Internal Med)

**Free Abdomen**

The mesentery in the cranial abdomen is hyperechoic.

**IMAGING PERFORMED BY**

**ULTRASONOGRAPHIC FINDINGS**

Amanda Stewart

**Primary Findings**

- Large, mid-hepatic mass adjacent to the gallbladder. Neoplasia (i.e., adenocarcinoma, sarcoma, round cell tumor) is suspected, with a low possibility of non-neoplastic process (i.e., inflammatory). It is unclear whether there is involvement of the gallbladder wall. Adjacent peritonitis is present.

**HOSPITAL NAME**

Beatties SC

**Secondary Findings**

**REFERRING VET**

Mellish

- Minor bilateral age-related renal changes
- The pancreatic changes are most consistent with age-related parenchymal remodeling, potentially secondary to a prior inflammatory episode, early fibrosis or chronic pancreatitis.

**INVOICE**

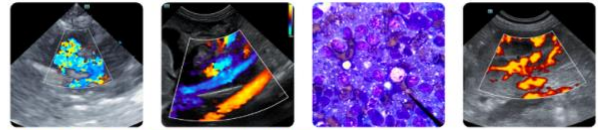
22309

**INTERPRETATION OF THE FINDINGS & FURTHER RECOMMENDATIONS**

**DATE**

12-22-25

- Three-view thoracic radiographs are recommended to assess for pulmonary metastases. If there is no evidence of pulmonary metastatic disease and an aggressive approach is desired, consider consultation with a board-certified surgeon to assess mass removal or debulking. An abdominal CT scan would be useful in presurgical planning. Fine-needle aspiration of the mass can also be considered, assuming normal clotting status. A 25-gauge needle should be used. It should be noted,



**PATIENT**

Lebowski Perry

**SPECIES**

Canine

**BREED**

Puli

**SEX**

Neutered Male

**AGE**

10

**WEIGHT**

15.2 kg

**INTERPRETED BY**

Andrea Nicastrò DVM  
 Diplomate ACVIM  
 (Sm Animal Internal Med)

**IMAGING PERFORMED BY**

Amanda Stewart

**HOSPITAL NAME**

Beatties SC

**REFERRING VET**

Mellish

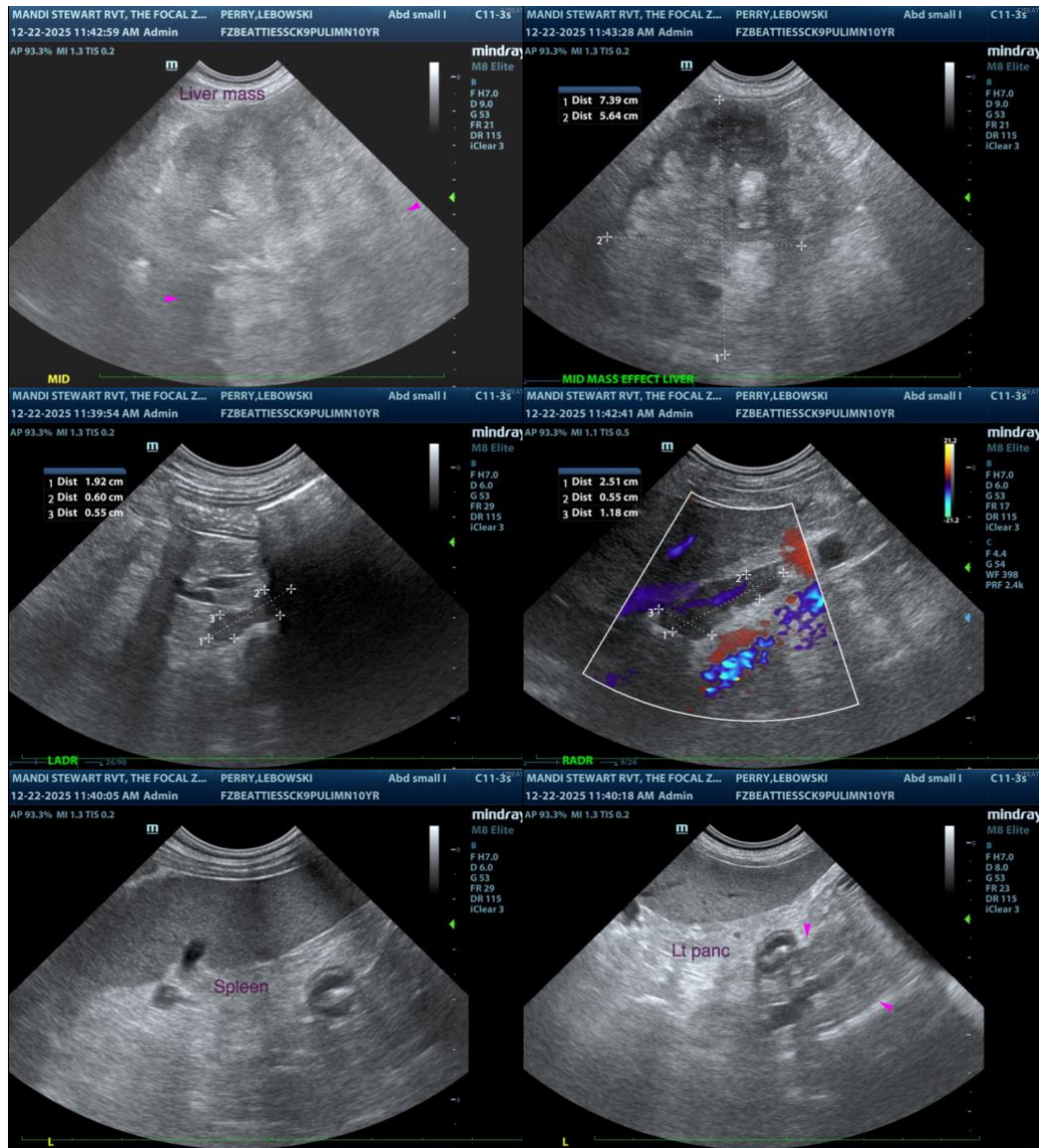
**INVOICE**

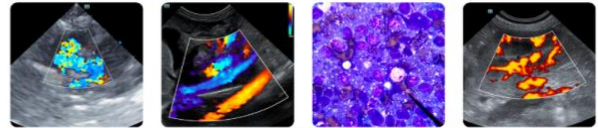
22309

**DATE**

12-22-25

however, that primary hepatic tumors can be difficult to diagnostic cytologically, and histopathology may be necessary to get a definitive diagnosis.





**PATIENT**

Lebowski Perry

**SPECIES**

Canine

**BREED**

Puli

**SEX**

Neutered Male

**AGE**

10

**WEIGHT**

15.2 kg

**INTERPRETED BY**

Andrea Nicastro DVM  
 Diplomate ACVIM  
 (Sm Animal Internal Med)

**IMAGING PERFORMED BY**

Amanda Stewart

**HOSPITAL NAME**

Beatties SC

**REFERRING VET**

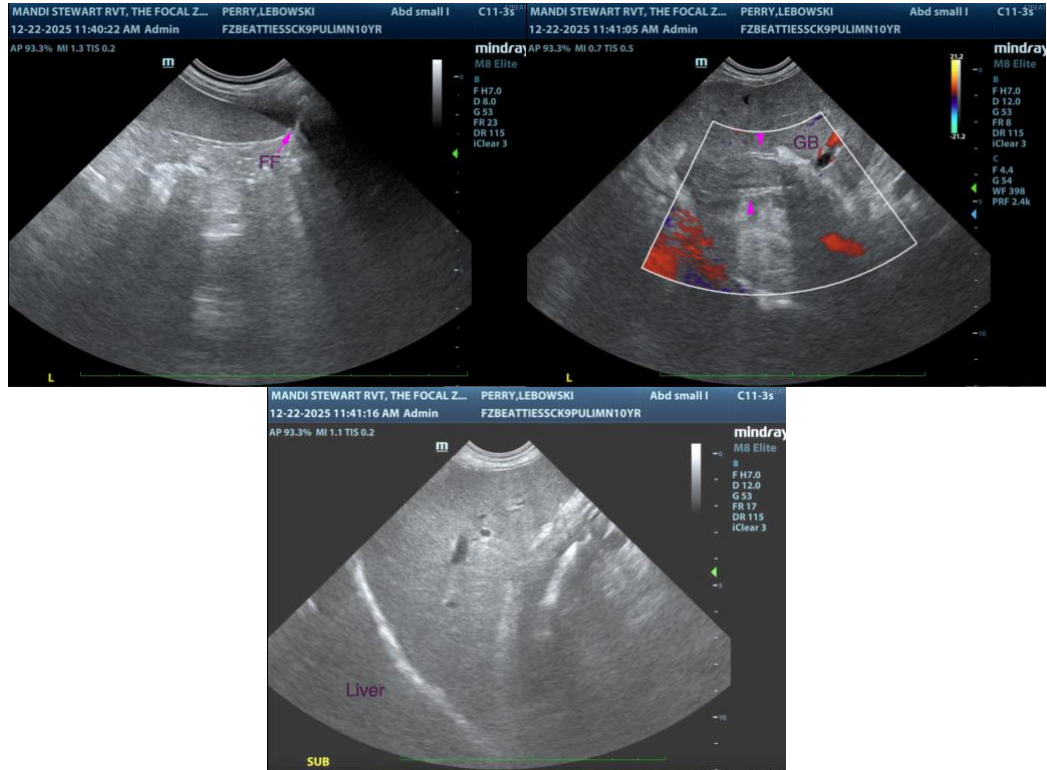
Mellish

**INVOICE**

22309

**DATE**

12-22-25



The information and recommendations provided are based on the images presented by the referring veterinarian/sonographer. No evaluation can be communicated regarding pathology that was not visible in the image/video clips provided.

Thank you for this referral. If the clinical or image interpretation does not parallel your findings or if I can be of any further assistance, please contact me.

**Andrea Nicastro, MPH, DVM, Diplomate DACVIM (Small Animal Internal Medicine)**  
[info@SonoPath.com](mailto:info@SonoPath.com)