



PATIENT

Echo Dermody

PRESENTING CLINICAL SIGNS

History: Presented to primary care vet on 12/16/2022 for several days' duration diarrhea. Normal demeanor/activity, eating fine, has been on chicken and rice past few days, regular diet is Blue Buffalo. No history of gastric indiscretions. She has lost 5 pounds since weight of 41 pounds in Aug 2022. She was treated with metronidazole and probiotic on outpatient basis and returns today for ultrasound. Her fasting state prior to ultrasound is not confirmed.

SPECIES

Canine

BREED

English Bulldog

Abnormal PE/Chem/CBC/UA Results: Her PE is pretty unremarkable. She is at present probably ideal body condition. Diagnostics: 12/16/2022: -Fecal (IDEXX) NEG -4DX NEG -T4 Normal -Chemistries: decreased ALB (1.7), TP 3.8, AST slight elev 61 (ref 15-55), slight hypocholesterolemia 128 (ref 131-145), mild elev CH 261 (ref 10-200) -CBC normal other than elev PLT 667 (ref 143-448) 10/17/2022: -HW Neg

SEX

Spayed Female

ULTRASONOGRAPHIC EXAMINATION OF THE ABDOMEN

Urinary System

The urinary bladder wall is normal in thickness and the mucosal surface is smooth. The bladder lumen is moderately distended with anechoic urine. No masses, inflammatory changes or calculi are observed. Ureteral papillae and visualized portion of the proximal urethra, visible to a depth of 1-2 cm, are normal.

AGE

8 years, 6 mos

The left kidney is normal size (6.24 cm in length) with a normal shape, architecture and smooth peripheral margins. There is a normal 1:3 cortex to medulla ratio minimal to mild loss of normal corticomedullary distinction. There is no evidence of pyelectasia, nephroliths, infarcts or hydronephrosis.

WEIGHT

6.4 kg

The right kidney is normal size (6.93 cm in length) with a normal shape, architecture and smooth peripheral margins. There is a normal 1:3 cortex to medulla ratio minimal to mild loss of normal corticomedullary distinction. There is no evidence of pyelectasia, nephroliths, infarcts or hydronephrosis.

INTERPRETED BY

Andrea Nicastro, DVM,
Diplomate ACVIM (*Small
Animal Internal Medicine*)

Adrenal Glands

The left adrenal gland is normal size (0.67 cm at cranial pole) (0.64 cm at caudal pole) with a normal shape and homogenous parenchyma. The glandular echogenicity and detail are unremarkable. Capsule, cortex, and medullary definition are normal. The phrenicoabdominal vein and surrounding vasculature are normal.

**IMAGING
PERFORMED BY**

Dr. Callihan/Pacific
Crest Mobile
Veterinary Service

The right adrenal gland is normal size (1.07 cm at cranial pole) (0.65 cm at caudal pole) with a normal shape and homogenous parenchyma. The glandular echogenicity and detail are unremarkable. Capsule, cortex, and medullary definition are normal. The phrenicoabdominal vein and surrounding vasculature are normal.

HOSPITAL NAME

Pacific Crest Mobile
Vet Svc

Spleen

The spleen is normal in size (0.91 cm in width at the level of the hilus) with a normal capsular contour. There is appropriate echogenicity and echotexture. No focal lesions are observed. Splenic vasculature is normal.

REFERRING VET

Dr. Boekenooen
Nooksack AH

Liver

The liver is subjectively normal in size with normal contours and structure. There is appropriate echogenicity and echotexture. No overt structural evidence of inflammatory, infiltrative, or regenerative pathology is evident. Vascular and biliary tracts are of normal volume with no evidence of congestion. No pathological hepatic lymphadenopathy observed. The portal vein to caudal vena cava ratio is approximately 1:1.

INVOICE

11898

The gall bladder is mildly distended. The wall is slightly thickened (up to 0.27 cm) and hyperechoic. Luminal contents are anechoic. The cystic and common bile ducts are normal/not seen.

DATE

12.22.22

Gastrointestinal

The gastric lumen is mildly distended with ingesta. The gastric wall and pylorus are normal in thickness with a normal layering pattern. The pyloric outflow tract is patent. The small intestinal lumen is segmentally dilated with chyme. The small intestinal wall is normal to mildly thickened (up to 0.55 cm) with retention of the normal layering pattern. There is evidence of mucosal striations +/- fogging in some segments. Discreet masses are not identified. The colonic wall is normal. There is no evidence of an obstructive pattern.

Pancreas

The region of the pancreas is isoechoic relative to surrounding omental fat. No obvious parenchymal abnormalities are observed. There is no evidence of regional inflammation or effusion.

Free Abdomen

The peritoneal cavity is normal. There is no evidence of inflammation or effusion. The abdominal lymph nodes are normal/not visible.

Other

A uterine stump is visible (0.59 cm in width). No obvious pathology is observed.

ULTRASONOGRAPHIC FINDINGS

Primary Findings

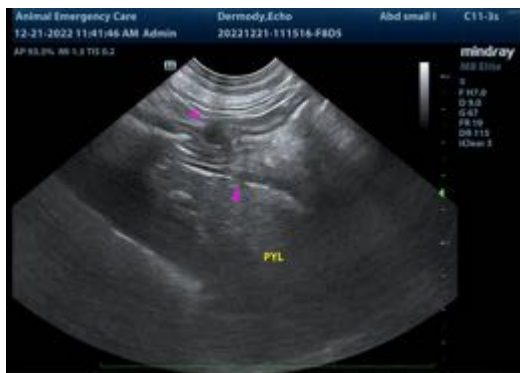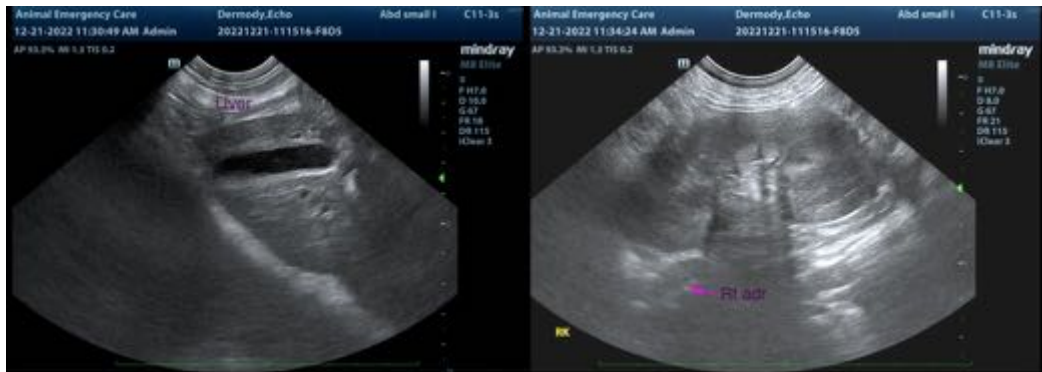
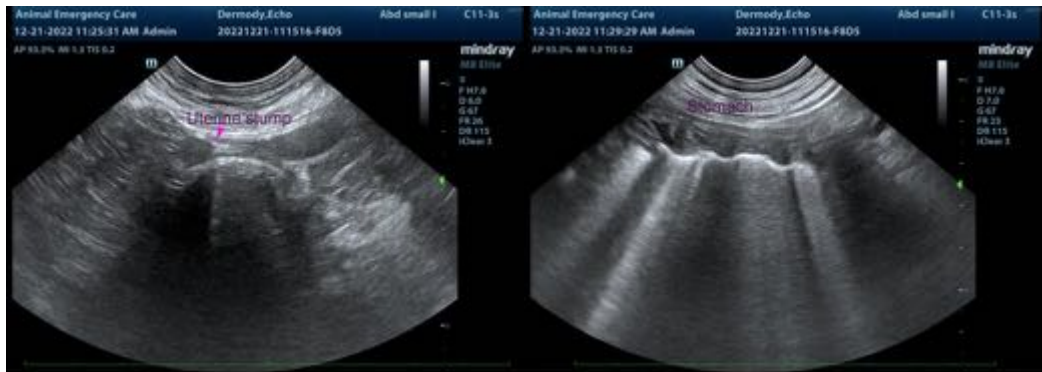
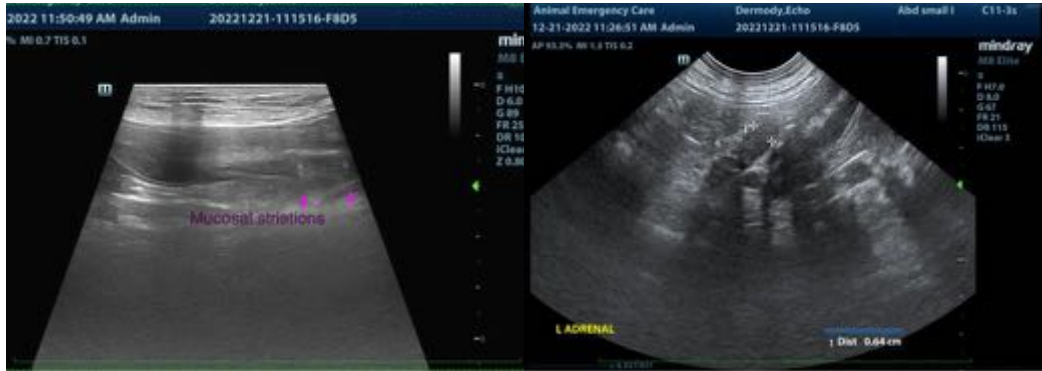- The patient's clinical history, in conjunction with the sonographic bowel changes are concerning for a protein-losing nephropathy. Differentials include lymphangiectasia, inflammatory bowel disease, infectious/parasitic disease, or less likely, infiltrative neoplasia.

Secondary Findings

- Minor bilateral age-related renal changes
- The thickened gall bladder wall may be artifactual due to lack of full repletion or may be secondary to benign age-related hyperplasia or cholecystitis.
- Visible uterine stump – incidental.

INTERPRETATION OF THE FINDINGS & FURTHER RECOMMENDATIONS

- Given the bowel changes, consider the following:
 1. Fecal evaluation for ova and Giardia
 2. Prophylactic deworming with Fenbendazole
 3. Malabsorption panel, including serum cobalamin and folate, TLI and PLI
 4. Consider transitioning to a low-fat limited antigen diet
 5. Ultimately endoscopic or surgical biopsies would be necessary to get a definitive diagnosis. Surgical biopsies would be ideal in that all areas of bowel can be accessed. If tissue sampling is pursued, thoracic radiographs should be performed prior to anesthesia.
- To evaluate for other concurrent causes of hypoalbuminemia, consider the following:
 1. UPC (if proteinuria is present)
 2. Pre-and postprandial serum bile acids to assess hepatic function
 3. Resting cortisol level to evaluate for atypical hypoadrenocorticism



The information and recommendations provided are based on the images presented by the referring veterinarian/sonographer. No evaluation can be communicated regarding pathology that was not visible in the image/video clips provided.

Thank you for this referral. If the clinical or image interpretation does not parallel your findings or if I can be of any further assistance, please contact me.

Andrea Nicastro, MPH, DVM, Diplomate DACVIM (Small Animal Internal Medicine)
info@SonoPath.com