



PATIENT

Skylar Moylen

PRESENTING CLINICAL SIGNS

History: ITP, vomiting blood

SPECIES

Canine

ULTRASONOGRAPHIC EXAMINATION OF THE ABDOMEN

Urinary System

BREED

Poodle mix

The urinary bladder wall is normal in thickness and the mucosal surface is smooth. The bladder lumen is moderately distended with anechoic urine. No masses, inflammatory changes or calculi are observed. Ureteral papillae and visualized portion of the proximal urethra, visible to a depth of 2 cm, are normal.

SEX

Female, spayed

The left kidney is normal size (6.76 cm in length); normal shape and architecture with smooth peripheral margins. There is a normal 1:3 cortex to medulla ratio with normal corticomedullary distinction. There is no evidence of pyelectasia, nephroliths, infarcts or hydronephrosis. Renal vasculature is normal.

AGE

6 Yrs.

The right kidney is normal size (6.07 cm in length); normal shape and architecture with smooth peripheral margins. There is a normal 1:3 cortex to medulla ratio with normal corticomedullary distinction. There is no evidence of pyelectasia, nephroliths, infarcts or hydronephrosis. Renal vasculature is normal.

WEIGHT

90.5.

Adrenal Glands

The left adrenal gland is normal size (0.60 cm at cranial pole) (0.61 cm at caudal pole); normal shape; homogenous parenchyma. The glandular echogenicity and detail are unremarkable. Capsule, cortex, and medullary definition are normal. The phrenicoabdominal vein and surrounding vasculature are normal.

INTERPRETED BY

Andrea Nicastro, DVM,
Diplomate ACVIM
(Small Animal Internal
Medicine)

The region of the right adrenal gland is evaluated. No obvious pathology is observed.

Spleen

The spleen is normal in size (2.13 cm in width at the level of the hilus) with a normal capsular contour. There is appropriate echogenicity and echotexture. No focal lesions are observed. Splenic vasculature is normal.

IMAGING PERFORMED BY

Jenn

Liver

The liver is subjectively normal in size with normal contours and structure. There is appropriate echogenicity and echotexture. No overt structural evidence of inflammatory, infiltrative or regenerative pathology is evident. Vascular and biliary tracts are of normal volume with no evidence of congestion. No pathological hepatic lymphadenopathy observed. The gall bladder lumen is moderately distended. The wall is thin and smooth. Luminal contents are anechoic. The cystic and common bile ducts are normal/not seen.

HOSPITAL NAME

Rockaway

REFERRING VET

Dr. Maniar

Gastrointestinal

The gastric lumen is not distended. The gastric wall is normal in thickness with a normal layering pattern. The small intestinal lumen is not dilated. The small intestinal wall thickness is normal with a normal layering pattern and appropriate mural detail. Discreet masses are not identified. The colonic wall is normal. No obstructive disease is noted.

INVOICE

14391

Pancreas

DATE

12/21/22



PATIENT

Skyler Moylen

The region of the pancreas is isoechoic relative to surrounding omental fat. No obvious parenchymal abnormalities are observed. There is no evidence of regional inflammation or effusion.

SPECIES

Canine

Free Abdomen

The peritoneal cavity is normal. There is no evidence of inflammation or effusion. The abdominal lymph nodes are normal/not visible.

BREED

Poodle mix

ULTRASONOGRAPHIC FINDINGS

Unremarkable abdomen.

SEX

Female, spayed

INTERPRETATION OF THE FINDINGS & FURTHER RECOMMENDATIONS

AGE

6 Yrs.

- A comprehensive tick panel, including PCR and serology (submission to North Carolina State University's Vector Borne Disease Diagnostic Lab) is recommended. <https://cvm.ncsu.edu/research/labs/clinical-sciences/vector-borne-disease/>.
- Consider three-view thoracic radiographs to assess for occult neoplasia in the chest, which can result in immune mediated thrombocytopenia.
- While awaiting test results, supportive care for immune mediated thrombocytopenia along with gastric protectants and other supportive measures is recommended.

WEIGHT

90.5.

INTERPRETED BY

Andrea Nicastro, DVM,
Diplomate ACVIM
(Small Animal Internal
Medicine)

IMAGING PERFORMED BY

Jenn

HOSPITAL NAME

Rockaway

REFERRING VET

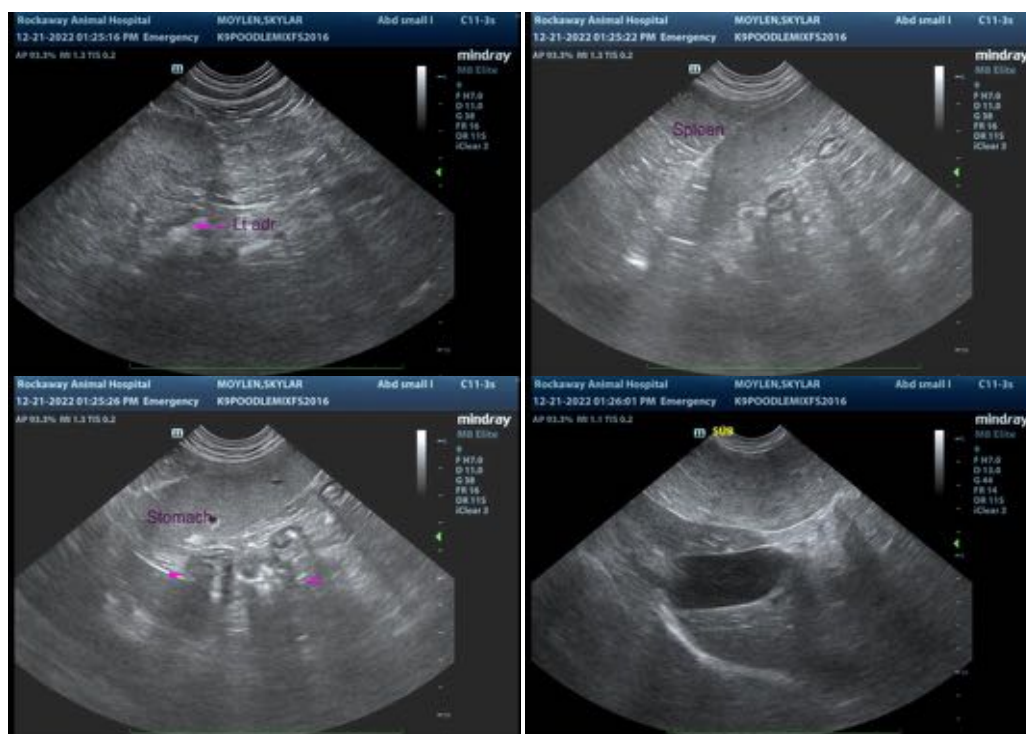
Dr. Maniar

INVOICE

14391

DATE

12/21/22





PATIENT

Skylar Moylen

SPECIES

Canine

BREED

Poodle mix

SEX

Female, spayed

AGE

6 Yrs.

WEIGHT

90.5.

INTERPRETED BY

Andrea Nicastro, DVM,
Diplomate ACVIM
(Small Animal Internal
Medicine)

**IMAGING
PERFORMED BY**

Jenn

HOSPITAL NAME

Rockaway

REFERRING VET

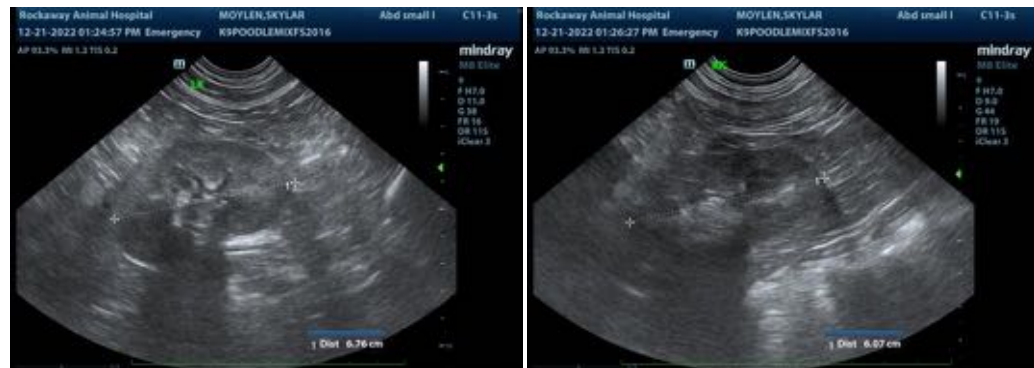Dr. Maniar

INVOICE

14391

DATE

12/21/22



The information and recommendations provided are based on the images presented by the referring veterinarian/sonographer. No evaluation can be communicated regarding pathology that was not visible in the image/video clips provided.

Thank you for this referral. If the clinical or image interpretation does not parallel your findings or if I can be of any further assistance please contact me.

Andrea Nicastro, MPH, DVM, Diplomate DACVIM (Small Animal Internal Medicine)
info@SonoPath.com