SonoPath
Clinical Sonography & Telecytology

EDUCATIONAL TELECONSULTATION SERVICES™

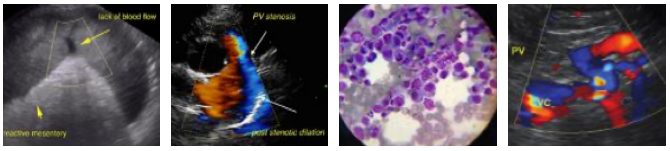

SonoPath.com™
1-800-838-4268 info@sonopath.com

PATIENT
Socks Cohen

SPECIES
Feline

BREED
Domestic shorthair

SEX
Male, neutered

AGE
14.5 Yrs.

WEIGHT
12.6 lbs.

INTERPRETED BY
Andrea Nicastro, DVM, Diplomate ACVIM (*Small Animal Internal Medicine*)

IMAGING PERFORMED BY
Shari Reffi CVT

HOSPITAL NAME
ACC Flanders

REFERRING VET
Dr. Hallihan

INVOICE
12744

DATE
12/21/21

PRESENTING CLINICAL SIGNS

History: Vomiting, anorexia x 3 days. R/O FB vs other. Current meds: Cerenia
Abnormal PE/Chem/CBC/UA Results: Creat 2.7, BUN 29. USG 1.020

ULTRASONOGRAPHIC EXAMINATION OF THE ABDOMEN

Urinary System

The urinary bladder, trigone, and pelvic urethra are normal in thickness and the mucosal surface is smooth. The bladder lumen is moderately distended with anechoic urine. No masses, inflammatory changes or calculi are observed. Ureteral papillae and visualized portion of the proximal urethra, visible to a depth of 2 cm, are normal.

The left kidney is normal size (3.77 cm in length); normal shape and architecture with smooth peripheral margins. There is a normal 1:3 cortex to medulla ratio with minimal loss of corticomedullary distinction. There is no evidence of pyelectasia, nephroliths, infarcts or hydroureter. Renal vasculature is normal.

The right kidney is normal size (3.57 cm in length); normal shape and architecture with smooth peripheral margins. There is a normal 1:3 cortex to medulla ratio with minimal loss of corticomedullary distinction. Trace pyelectasia is present. There is no evidence of nephroliths, infarcts or hydroureter.

Adrenal Glands

The region of the left adrenal gland is evaluated. No obvious pathology is observed.

The right adrenal gland is normal in size (0.52 cm width). Normal shape and glandular echogenicity. The phrenicoabdominal vein and surrounding vasculature are normal.

Spleen

The spleen is normal in size (0.91 cm in width at the level of the hilus) with a normal capsular contour. There is appropriate echogenicity and echotexture. A 0.25 cm hyperechoic focus is observed at the cranial aspect. Splenic vasculature is normal.

Liver

The liver is subjectively normal in size with normal contours and structure. There is appropriate echogenicity and echotexture. No overt structural evidence of inflammatory, infiltrative or regenerative pathology is evident. Vascular and biliary tracts are of normal volume with no evidence of congestion. No pathological hepatic lymphadenopathy observed. The gallbladder is of normal contours and contains some dependent echogenic debris. The wall is normal in thickness. No choleliths are observed. The cystic and common bile ducts are normal.

Gastrointestinal

The gastric lumen is mildly distended with ingesta. The gastric wall and pylorus are normal in thickness with a normal layering pattern. The pyloric outflow tract is patent. The small intestinal lumen is not dilated. The small intestinal wall is mildly thickened (up to 0.32 cm) with a normal layering pattern and appropriate mural detail. There is disruption in the normal 1:3 muscularis: mucosal ratio with a 1:1 ratio in some segments. Discreet masses are not identified. The colonic wall is normal. No obstructive disease is noted.

SonoPath
Clinical Sonography & Telecytology
EDUCATIONAL TELECONSULTATION SERVICES™

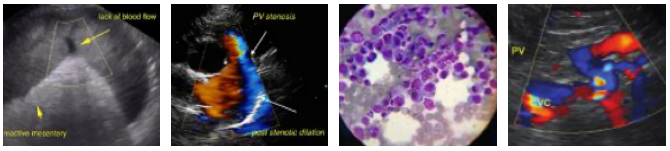

SonoPath.com
1-800-838-4268 info@sonopath.com

PATIENT
Socks Cohen

SPECIES
Feline

BREED
Domestic shorthair

SEX
Male, neutered

AGE
14.5 Yrs.

WEIGHT
12.6 lbs.

INTERPRETED BY
Andrea Nicastro, DVM, Diplomate ACVIM (*Small Animal Internal Medicine*)

IMAGING PERFORMED BY
Shari Reffi CVT

HOSPITAL NAME
ACC Flanders

REFERRING VET
Dr. Hallihan

INVOICE
12744

DATE
12/21/21

Pancreas

The region of the pancreas is isoechoic relative to surrounding omental fat. No obvious parenchymal abnormalities are observed. There is no evidence of regional inflammation or effusion.

Free Abdomen

There is no evidence of free fluid. A few prominent mesenteric lymph nodes are visualized, the largest measuring 0.85 cm in length. Surrounding mesentery is hyperechoic.

ULTRASONOGRAPHIC FINDINGS

Primary Findings:

- Bowel pattern consistent with inflammatory bowel disease with potential for emerging lymphoma.
- The prominent abdominal lymph nodes are most consistent with reactive lymphadenitis or lymphoid hyperplasia. Neoplastic infiltration is considered less likely.

Secondary Findings:

- Minor age-related renal changes.
- The hyperechoic splenic focus likely represents benign change (i.e., myelolipoma, focus of lymphoid hyperplasia).

INTERPRETATION OF THE FINDINGS & FURTHER RECOMMENDATIONS

- GI panel (sent to Texas A&M).
- A fecal evaluation for ova/Giardia
- Ultimately, endoscopic or surgical gastrointestinal biopsies may be necessary to get a definitive diagnosis.
- Three-view thoracic radiographs should be performed prior to any anesthetic event.
- Given the mild azotemia, consider the following:
  1. Urine culture and sensitivity
  2. UPC (if proteinuria is present)
  3. Baseline blood pressure measurement

SonoPath

Clinical Sonography & Telecytology

EDUCATIONAL TELECONSULTATION SERVICES™

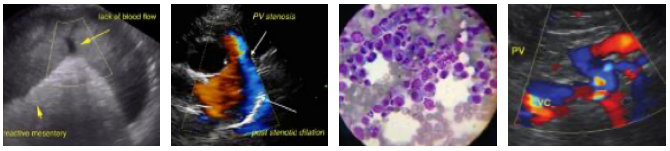

SonoPath.com™

1-800-838-4268 info@sonopath.com

PATIENT

Socks Cohen

SPECIES

Feline

BREED

Domestic shorthair

SEX

Male, neutered

AGE

14.5 Yrs.

WEIGHT

12.6 lbs.

INTERPRETED BY

Andrea Nicastro, DVM, Diplomate ACVIM (*Small Animal Internal Medicine*)

IMAGING PERFORMED BY

Shari Reffi CVT

HOSPITAL NAME

ACC Flanders

REFERRING VET

Dr. Hallihan

INVOICE

12744

DATE

12/21/21

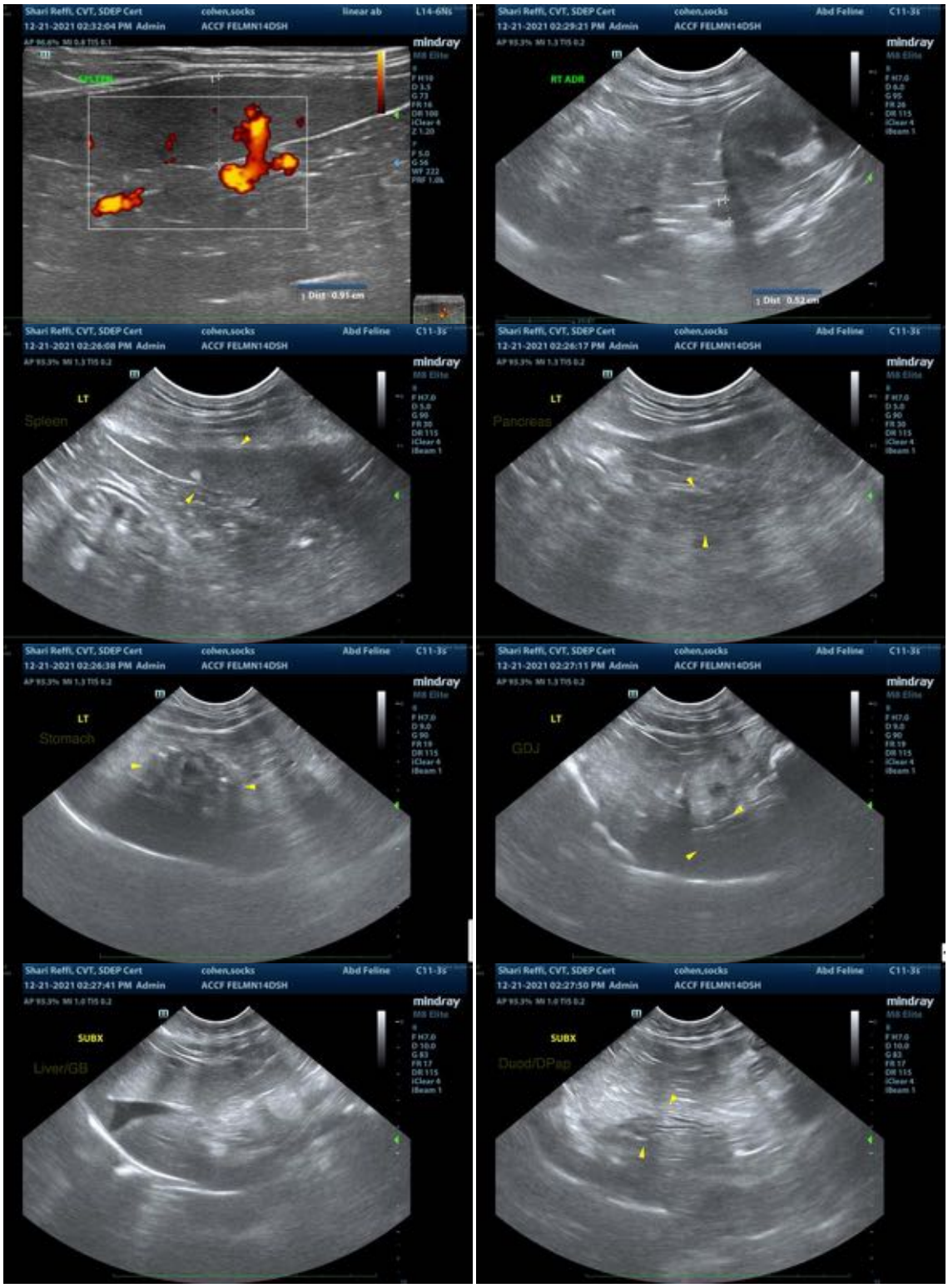

SonoPath

Clinical Sonography & Telecytology

EDUCATIONAL TELECONSULTATION SERVICES™

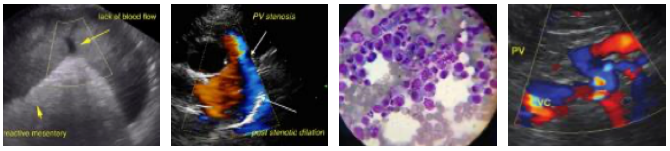

SonoPath.com™

1-800-838-4268 info@sonopath.com

PATIENT

Socks Cohen

SPECIES

Feline

BREED

Domestic shorthair

SEX

Male, neutered

AGE

14.5 Yrs.

WEIGHT

12.6 lbs.

INTERPRETED BY

Andrea Nicastro, DVM, Diplomate ACVIM (*Small Animal Internal Medicine*)

IMAGING PERFORMED BY

Shari Reffi CVT

HOSPITAL NAME

ACC Flanders

REFERRING VET

Dr. Hallihan

INVOICE

12744

DATE

12/21/21

The information and recommendations provided are based on the images presented by the referring veterinarian. No evaluation can be communicated regarding pathology that was not visible in the image/video clips provided.

Thank you for this referral. If the clinical or image interpretation does not parallel your findings or if I can be of any further assistance please contact me.

Andrea Nicastro, DVM, Diplomate ACVIM (*Small Animal Internal Medicine*)

Andrea.nicastro@sonopath.com