

**DATE**

12/20/21

PRESENTING CLINICAL SIGNS

History: Patient presents for significant orthopedic concerns but has 10-pound weight loss; owner wishes to investigate causes for weight loss.

PATIENT

Juneau Kozlowski

Radiographs: Unremarkable thorax.

Date of Previous IntraPet Ultrasound: No previous IntraPet scans.

Sedation: Not required to complete full diagnostic ultrasound.

Stat Report: Not requested.

SPECIES

Canine

BREED

Great Pyranese

SEX

Female, spayed

AGE

10/13/2012

WEIGHT

95 lbs.

INTERPRETED BY

Andrea Nicastro, DVM,
 Diplomate ACVIM
 (Small Animal Internal
 Medicine)

IMAGING PERFORMED BY

Andi Parkinson RDMS

HOSPITAL NAME

Perry Hall AH

REFERRING VET

Dr. Miller

INVOICE

12724

ULTRASONOGRAPHIC EXAMINATION OF THE ABDOMEN**Urinary System**

The urinary bladder and visible portion of the pelvic urethra are normal for the degree of luminal distension. The urine is anechoic with no evidence of debris. Cystic calculi and discrete masses are not observed. The region of the trigone and the visible portion of the proximal urethra are normal.

The left kidney is normal size (7.62 cm in length); normal shape and architecture with smooth peripheral margins. There is a normal 1:3 cortex to medulla ratio with normal corticomedullary distinction. There is no evidence of pyelectasia, nephroliths, infarcts or hydroureter.

The right kidney is normal size (7.25 cm in length); normal shape and architecture with smooth peripheral margins. There is a normal 1:3 cortex to medulla ratio with normal corticomedullary distinction. There is no evidence of pyelectasia, nephroliths, infarcts or hydroureter.

Adrenal Glands

The left adrenal gland is normal size (0.59 cm at cranial pole) (0.65 cm at caudal pole) (3.58 cm in length); normal shape; homogenous parenchyma. The glandular echogenicity and detail are unremarkable. Capsule, cortex, and medullary definition are normal. The phrenicoabdominal vein and surrounding vasculature are normal.

The right adrenal gland is normal size (0.57 cm at caudal pole) (2.45 cm in length); normal shape; homogenous parenchyma. The glandular echogenicity and detail are unremarkable. Capsule, cortex, and medullary definition are normal. The phrenicoabdominal vein and surrounding vasculature are normal.

Spleen

The spleen is normal in size (1.93 cm in width at the level of the hilus) with a normal capsular contour. There is appropriate echogenicity and echotexture. No focal lesions are observed. Splenic vasculature is normal.

Liver

The liver is subjectively normal in size with normal contours and structure. There is appropriate echogenicity and echotexture. No overt structural evidence of inflammatory, infiltrative or regenerative pathology is evident. Vascular and biliary tracts are of normal volume with no evidence of congestion. No pathological hepatic lymphadenopathy observed. The gallbladder is of normal contours and contains some dependent echogenic debris. The wall is normal in thickness. No choleliths are observed. The cystic and common bile ducts are normal.

Gastrointestinal

The stomach and intestine are free of stasis and exhibit normal peristaltic activity. The gastric lumen is mildly gas distended. The gastric wall is normal in thickness with a normal layering pattern. The small intestinal lumen is segmentally gas distended. The small intestinal wall thickness is normal with a normal layering pattern and appropriate mural detail. Discreet masses are not identified. The colonic wall is normal. No obstructive disease is noted.

Pancreas

The pancreas is normal in size with normal peripheral contours. The pancreatic duct is normal. The base and limbs of the pancreas are isoechoic to surrounding omental fat. No focal lesions are observed. There is no evidence of peripancreatic inflammation or effusion.

Free Abdomen

The peritoneal cavity is normal. There is no evidence of inflammation or effusion. The abdominal lymph nodes are normal/not visible.

ULTRASONOGRAPHIC FINDINGS

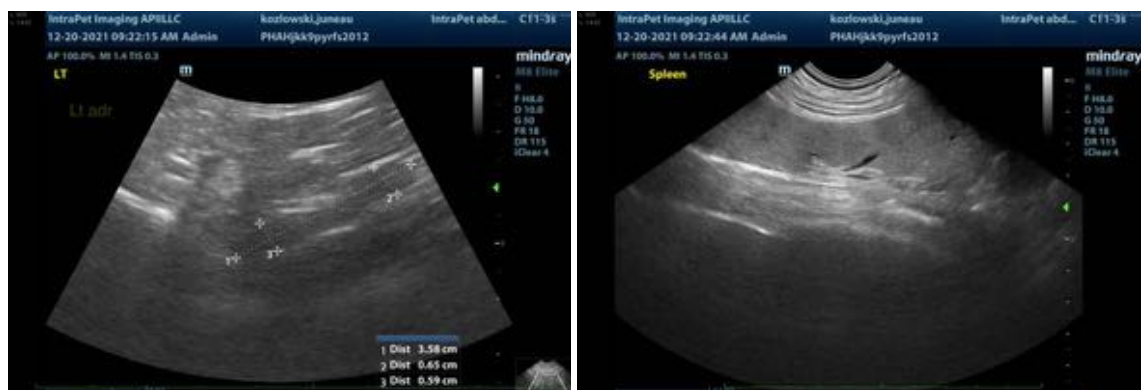
Unremarkable abdomen. An obvious cause for the patient's weight loss is not identified in this study. Considerations include microscopic gastrointestinal disease, occult neoplasia, primary neurologic issue (i.e., brain tumor), weight loss secondary to pain (i.e., from orthopedic disease), other.

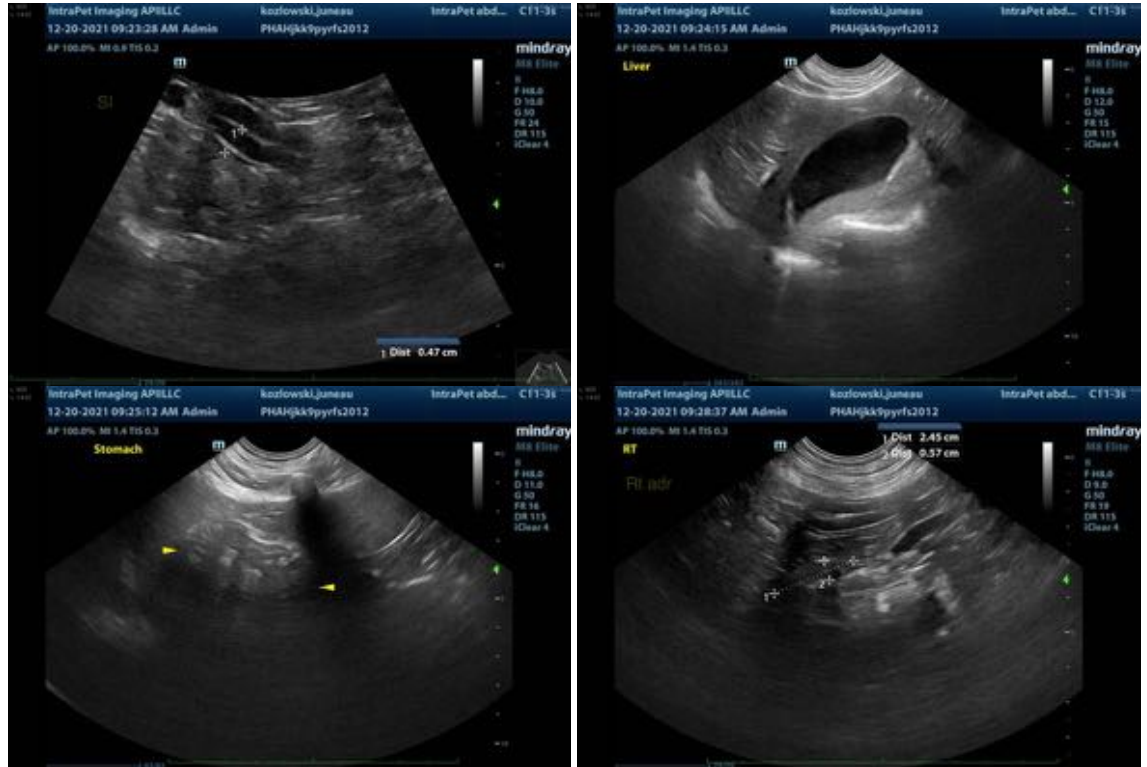
INTERPRETATION OF THE FINDINGS & FURTHER RECOMMENDATIONS

Three-view thoracic radiographs are recommended to assess for occult neoplasia in the chest.

A thorough neurologic examination is recommended to assess for deficits as weight loss can be the sole clinical sign for primary brain tumors.

Also consider a GI panel including serum cobalamin, folate, TLI and PLI.





The information and recommendations provided are based on the images presented by the referring veterinarian. No evaluation can be communicated regarding pathology that was not visible in the image/video clips provided.

Thank you for this referral. If the clinical or image interpretation does not parallel your findings or if I can be of any further assistance please contact me.

Andrea Nicastro, DVM, Diplomate ACVIM (*Small Animal Internal Medicine*)
Andrea.nicastro@sonopath.com