

**DATE PRESENTING CLINICAL SIGNS**

12/20/21

History: Persistent V, with no relief other than when Cerenia administered.

PATIENT

Gracie Maenner

Lab Results: Total Protein 8.9 (5.5 - 7.5 g/dL), Albumin 2.2 (2.7 - 3.9 g/dL), Globulin 6.7 (2.4 - 4.0 g/dL), Albumin: Globulin Ratio 0.3 (0.7 - 1.5). T4 normal. Lyme positive.

Date of Previous IntraPet Ultrasound: No previous IntraPet scans.

Sedation: Not required to complete full diagnostic ultrasound.

Stat Report: Not requested.

SPECIES

Canine

BREEDChesapeake Bay
Retriever**SEX**

Female, intact

AGE

9/6/2014

WEIGHT

85.2 lbs.

INTERPRETED BYAndrea Nicastro, DVM,
Diplomate ACVIM
(Small Animal Internal
Medicine)**IMAGING PERFORMED BY**

Andi Parkinson RDMS

HOSPITAL NAME

White Marsh AH

REFERRING VET

Dr. Danna

INVOICE

12725

ULTRASONOGRAPHIC EXAMINATION OF THE ABDOMEN**Urinary System**

The urinary bladder, trigone, and pelvic urethra are normal in thickness and the mucosal surface is smooth. The bladder lumen is moderately distended with anechoic urine. No masses, inflammatory changes or calculi are observed. Ureteral papillae and visualized portion of the proximal urethra, visible to a depth of 2 cm, are normal.

The left kidney is normal size (6.90 cm in length); normal shape and architecture with smooth peripheral margins. There is a normal 1:3 cortex to medulla ratio with normal corticomedullary distinction. There is no evidence of pyelectasia, nephroliths, infarcts or hydroureter. The right kidney is normal size (8.66 cm in length); normal shape and architecture with smooth peripheral margins. There is a normal 1:3 cortex to medulla ratio with normal corticomedullary distinction. There is no evidence of pyelectasia, nephroliths, infarcts or hydroureter.

Adrenal Glands

The left adrenal gland is enlarged (0.64 cm at cranial pole) (1.17 cm at caudal pole) (3.15 cm in length) with a slightly irregular shape. A 1.38 x 1.19 cm hyperechoic to slightly heterogeneous nodule is observed at the caudal pole. The glandular echogenicity and detail at the cranial pole are unremarkable. The phrenicoabdominal vein and surrounding vasculature are normal.

The right adrenal gland is normal size (0.76 cm at cranial pole) (0.75 cm at caudal pole) (2.95 cm in length); normal shape; homogenous parenchyma. The glandular echogenicity and detail are unremarkable. Capsule, cortex, and medullary definition are normal. The phrenicoabdominal vein and surrounding vasculature are normal.

Spleen

The spleen is normal in size (2.80 cm in width at the level of the hilus) with a normal capsular contour. There is appropriate echogenicity and echotexture. No focal lesions are observed. Splenic vasculature is normal.

Liver

The liver is subjectively normal in size with normal contours and structure. There is appropriate echogenicity and echotexture. No overt structural evidence of inflammatory, infiltrative or regenerative pathology is evident. Vascular and biliary tracts are of normal volume with no evidence of congestion. No pathological hepatic lymphadenopathy observed. The gall bladder lumen is moderately distended. The wall is thin and smooth. Luminal contents are anechoic. The cystic and common bile ducts are normal/not seen.

Gastrointestinal

The stomach and intestine are free of stasis and exhibit normal peristaltic activity. The gastric lumen is not distended. The gastric wall and pylorus are normal in thickness with a normal layering pattern. The pyloric outflow tract is patent. The small intestinal lumen is not dilated. A 3-4 cm segment of jejunum is thickened (up to 0.93 cm) with a prominent muscularis layer. There is suspected loss of the normal layering pattern in one portion of this thickened segment. The remainder of the small intestinal tract is normal with a normal layering pattern and appropriate mural detail. The colonic wall is normal. No obstructive disease is noted.

Pancreas

The left limb/body is visible with normal curvilinear peripheral contours. The parenchyma is hypoechoic relative to surrounding omental fat. No distinct focal lesions are observed. The pancreatic duct is not overtly dilated. The mesentery effacing the serosal surface is mildly hyperechoic.

Free Abdomen

There is no evidence of free fluid. Several prominent mesenteric and caudal abdominal lymph nodes are visualized, the largest measuring 3.11 cm in length.

Other

The right ovary is subjectively normal in size (2.69 x 1.76 cm) with normal peripheral margins. Follicles are observed within the parenchyma. No obvious pathology is seen.

The left ovary is subjectively normal in size (2.65 x 2.29 cm). Multiple follicles are visualized. No obvious pathology is observed.

The uterus is visible. No obvious pathology is observed.

ULTRASONOGRAPHIC FINDINGS

Primary Findings:

- The focal jejunal thickening is concerning for infiltrative neoplasia (i.e., adenocarcinoma, lymphoma). However, a severe inflammatory process cannot be excluded.
- The abdominal lymphadenopathy could be consistent with reactive lymphadenitis, lymphoid hyperplasia or infiltrative neoplasia.
- The pancreatic changes are suggestive of low-grade pancreatitis.

Secondary Findings:

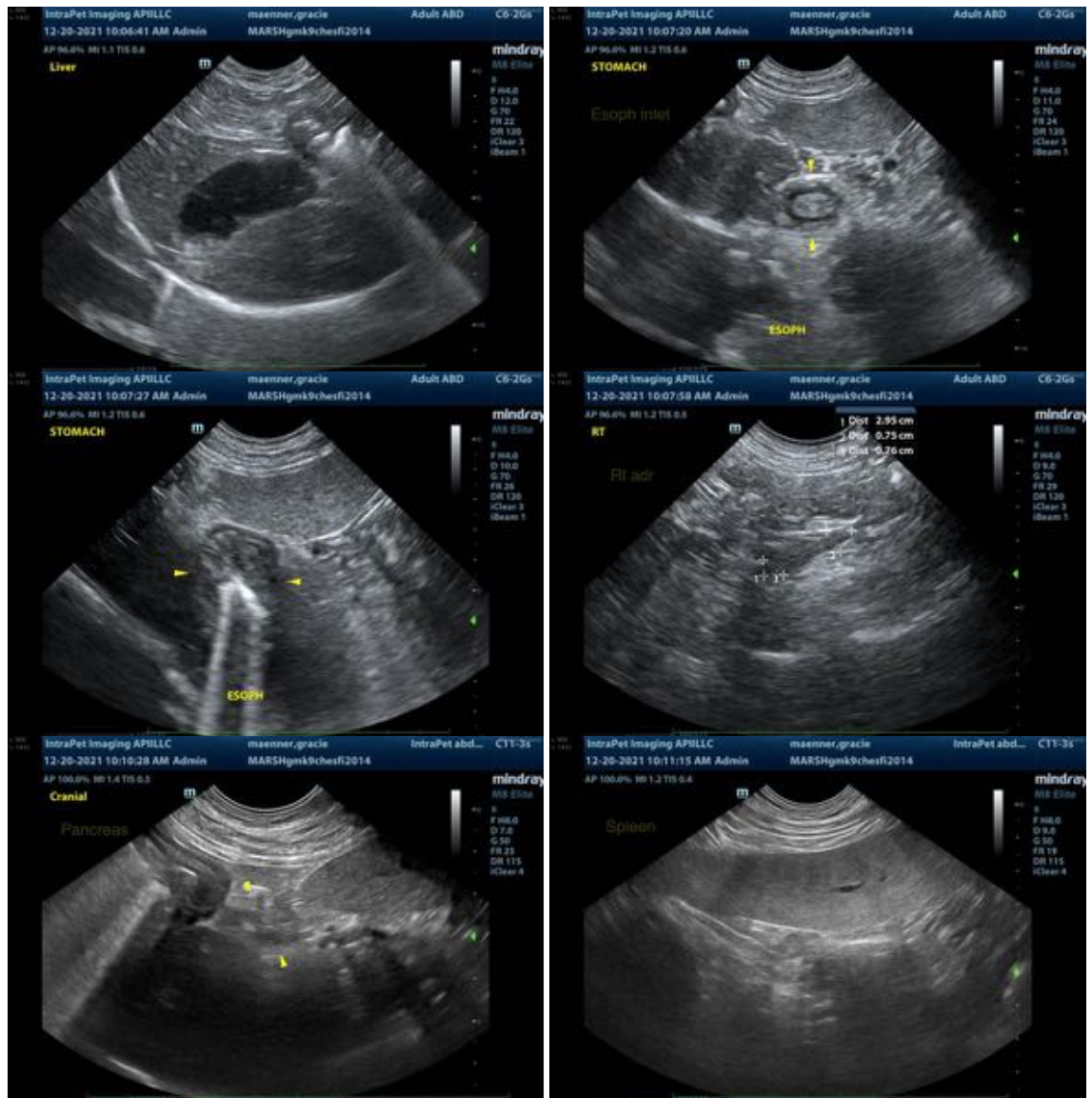
- The left adrenal nodule could be consistent with a benign process (i.e., nodular hyperplasia). Alternatively, an emerging neoplastic process may be present.

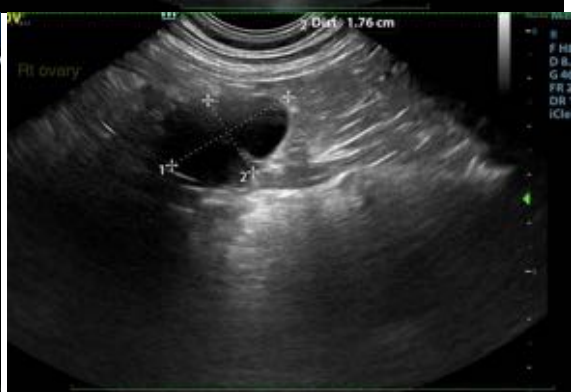
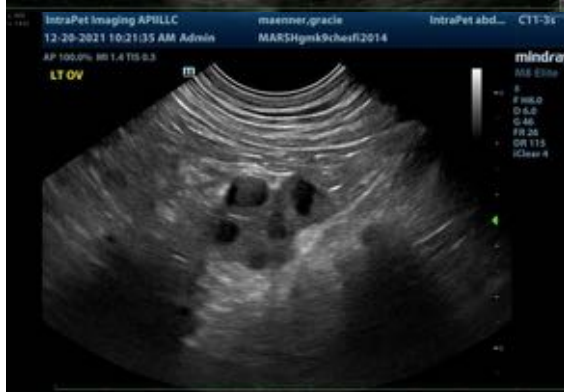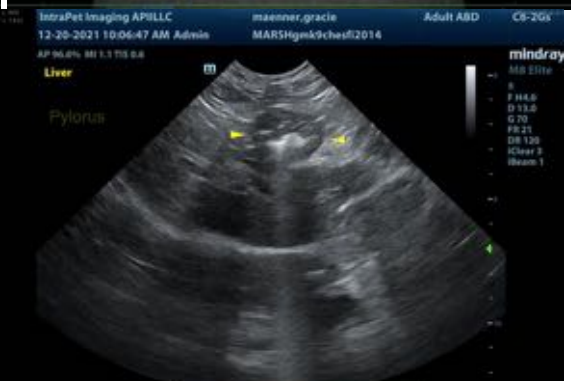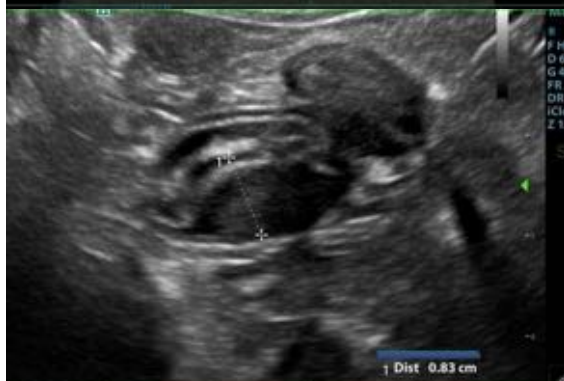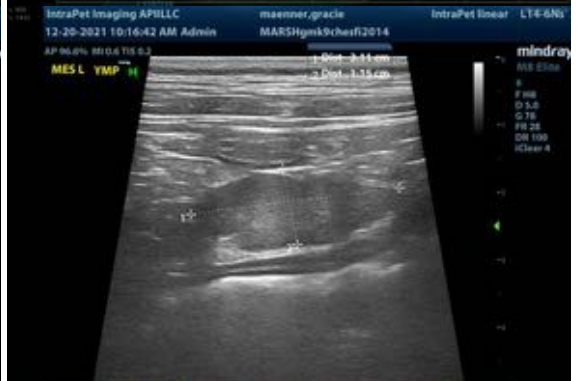
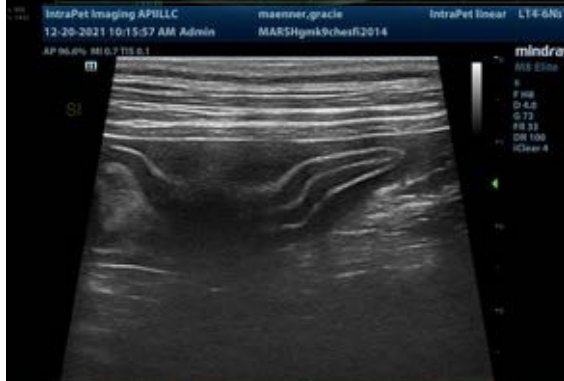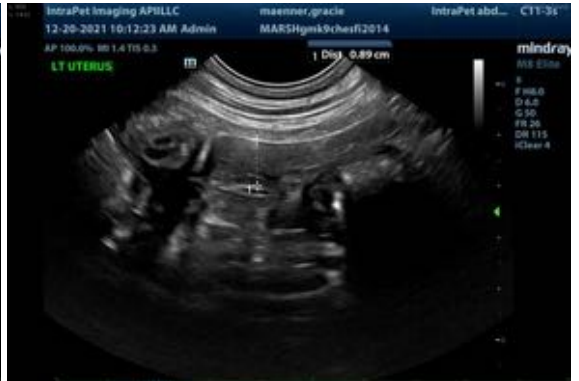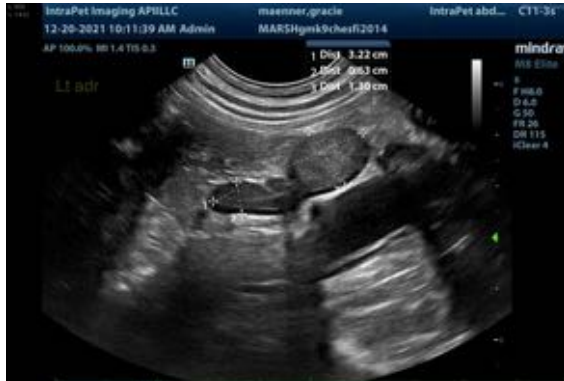INTERPRETATION OF THE FINDINGS & FURTHER RECOMMENDATIONS

- Three-view thoracic radiographs are recommended to assess for pulmonary metastases.
- If accessible, a fine needle aspirate of the thickened jejunal segment is recommended (if clotting status is appropriate). If cytologic evaluation is inconclusive or if the region is not accessible an

abdominal exploratory with surgical gastrointestinal and abdominal lymph node biopsies may be necessary to get a definitive diagnosis.

- A malabsorption panel including serum cobalamin, folate, TLI and PLI is also recommended.





The information and recommendations provided are based on the images presented by the referring veterinarian. No evaluation can be communicated regarding pathology that was not visible in the image/video clips provided.

Thank you for this referral. If the clinical or image interpretation does not parallel your findings or if I can be of any further assistance please contact me.

Andrea Nicastro, DVM, Diplomate ACVIM (*Small Animal Internal Medicine*)
Andrea.nicastro@sonopath.com