

**DATE PRESENTING CLINICAL SIGNS**

12/2/21 History: Intermittent diarrhea- vomiting - Low albumin on Labs - mild distention of cranial abd – hepatomegaly.

PATIENT

Ripken Patro

Current Medications: Diigel , Visbiome , Metronidazole for diarrhea - just commenced on Nov 30th.
 Lab Results: low serum Albumin (1.9), TP - 3.2, hypocalcemic. Attached separately. Globulins are low at 1.3
 Date of Previous IntraPet Ultrasound: No previous IntraPet scans.

SPECIES

Canine

Sedation: Not required to complete full diagnostic ultrasound.
 Stat Report: Not requested.

BREED

Boston Terrier

ULTRASONOGRAPHIC EXAMINATION OF THE ABDOMEN**SEX**

Neutered Male

Urinary System

The urinary bladder, trigone, and pelvic urethra are normal in thickness and the mucosal surface is smooth. The bladder lumen is moderately distended with anechoic urine. No masses, inflammatory changes or calculi are observed. Ureteral papillae and visualized portion of the proximal urethra, visible to a depth of 2.0 cm, are normal.

AGE

10/1/12

The prostate is normal in size (0.71 cm in width) and shape. Parenchyma is homogenous. The prostatic urethra appears normal without evidence of dilation or obstruction.

WEIGHT

22.6 Lbs.

The left kidney presented normal size (5.11 cm in length); normal shape and architecture with smooth peripheral margins. There is a normal 1:3 cortex to medulla ratio with normal corticomedullary distinction. There is no evidence of pyelectasia, nephroliths, infarcts or hydroureter. Renal vasculature is normal.

INTERPRETED BY

Andrea Nicastro, DMV,
 Diplomate DACVIM
 (Small Animal
 Internal Medicine)

The right kidney presented normal size (4.32 cm in length); normal shape and architecture with smooth peripheral margins. There is a normal 1:3 cortex to medulla ratio with normal corticomedullary distinction. There is no evidence of pyelectasia, nephroliths, infarcts or hydroureter. Renal vasculature is normal.

IMAGING PERFORMED BY

Andi Parkinson RDMS

Adrenal Glands

The left adrenal gland is normal size (0.64 cm at cranial pole) (0.69 cm at caudal pole) (1.96 cm in length); normal shape; homogenous parenchyma. The glandular echogenicity and detail are unremarkable. Capsule, cortex, and medullary definition are normal. The phrenicoabdominal vein and surrounding vasculature are normal.

HOSPITAL NAME

Eastern AH

The right adrenal gland is normal size (0.54 cm at cranial pole) (0.44 cm at caudal pole) (2.01 cm in length); normal shape; homogenous parenchyma. The glandular echogenicity and detail are unremarkable. Capsule, cortex, and medullary definition are normal. The phrenicoabdominal vein and surrounding vasculature are normal.

REFERRING VET

Dr. Kaufman

Spleen

The spleen is normal in size (1.58 cm at the level of the hilus) with a normal capsular contour. There is appropriate echogenicity and echotexture. No focal lesions are observed. Splenic vasculature is normal.

Liver**INVOICE**

12789

The liver is subjectively prominent in size with swollen curvilinear peripheral contours. The parenchyma is isoechoic relative to the spleen and exhibits mild heterogeneity. No focal distinct lesions are observed. Hepatic vasculature and biliary tracts are of normal volume with no evidence of congestion.

The gall bladder lumen is moderately distended. The wall is thin and smooth. A scant amount of aggregated echogenic partially dependent debris is observed within the lumen. The cystic and common bile ducts are normal/not seen.

Gastrointestinal

The gastric lumen is moderately distended with ingesta. The gastric wall is normal in thickness with a normal layering pattern. The small intestinal lumen is not dilated. The small intestinal wall is normal to borderline thickened (up to 0.48 cm) with a normal layering pattern. There is evidence of slight mucosal speckling in some segments. Discreet masses are not identified. The colonic wall is normal. There is no evidence of an obstructive pattern.

Pancreas

The portion of the pancreas is obscured by the gastric distention. In the visualized portions, no obvious pathology is observed.

Free Abdomen

The mesentery surrounding the small intestinal loops is hyperechoic. Trace free fluid is observed. 1-2 mesenteric lymph nodes are visible. Surrounding mesentery is hyperechoic.

ULTRASONOGRAPHIC FINDINGS

Primary Findings

- Given the patients clinical history and sonographic findings, a protein-losing enteropathy is suspected. Differentials include inflammatory bowel disease, lymphangiectasia, infectious/parasitic disease, infiltrative neoplasia (less likely), other.
- Mild peritonitis, likely secondary to bowel pathology

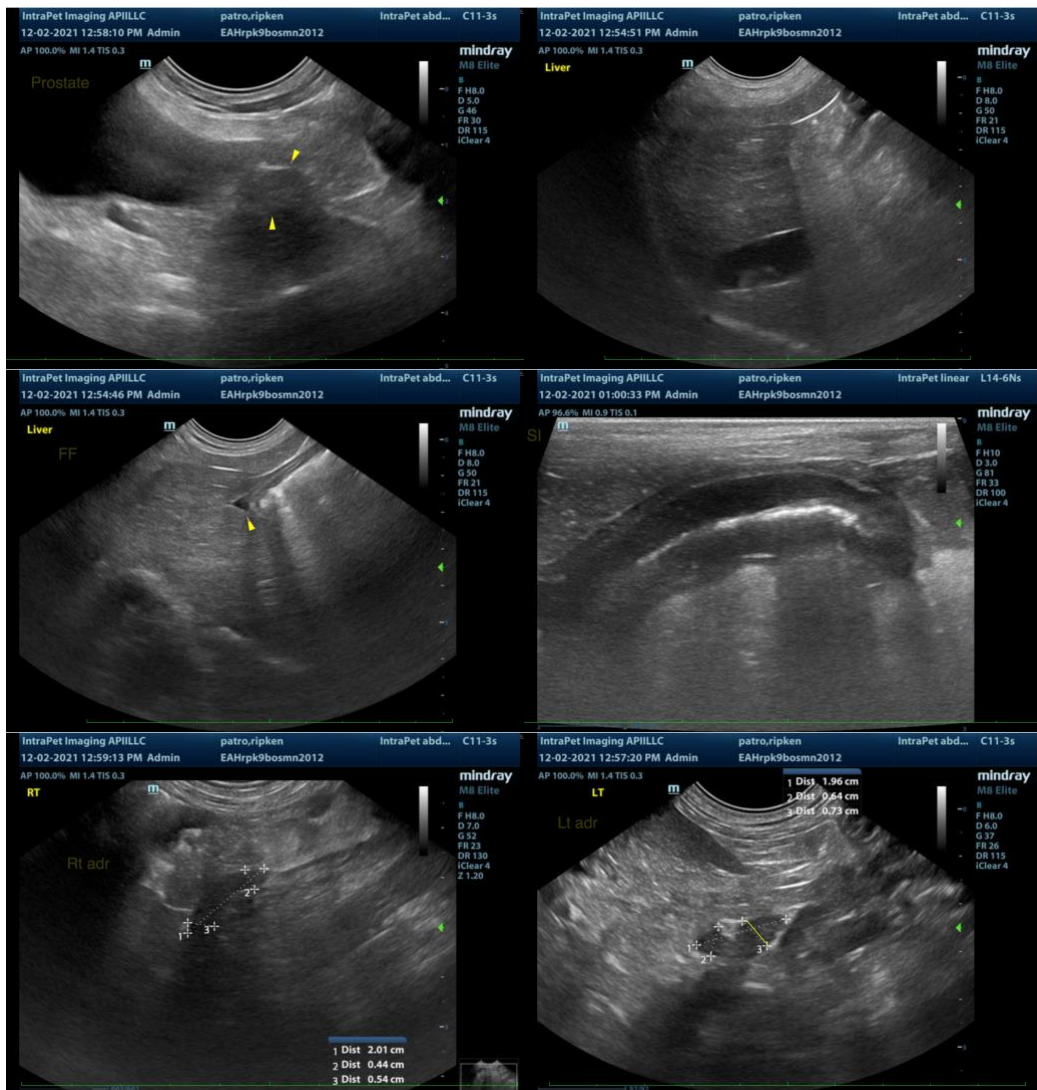
Secondary Findings

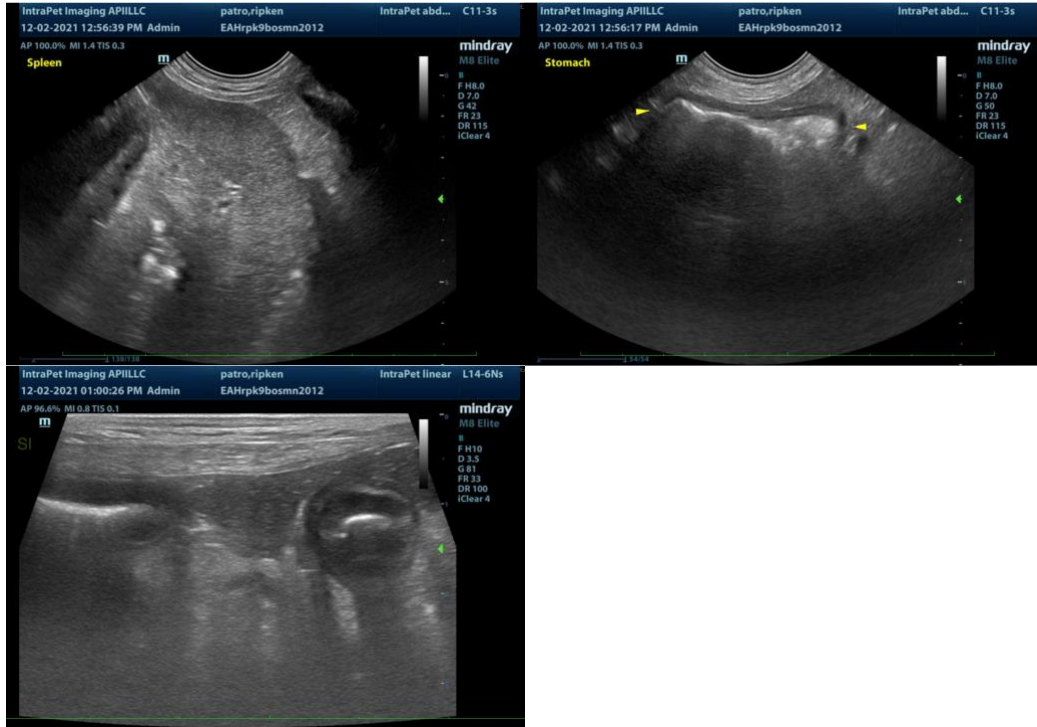
- The diffuse hepatic changes are non-specific and could be consistent with vacuolar hepatopathy, regenerative nodular hyperplasia, and/or age-related remodeling. Inflammatory and infiltrative disease are considered unlikely.

INTERPRETATION OF THE FINDINGS & FURTHER RECOMMENDATIONS

- Three-view thoracic radiographs are recommended to assess cardiopulmonary status, particularly in light of the patients' hypoalbuminemia, which can result in third spacing of fluids.
- A fecal evaluation for ova/Giardia
- Prophylactic deworming with Fenbendazole at 50 mg/kg once a day for 5 days is recommended. Repeat above protocol in 3 weeks.
- A GI panel (send to Texas A & M), including serum cobalamin, folate, PLI and TLI is recommended.

- Consider transitioning to a low-fat limited antigen diet.
- Ultimately, endoscopic or surgical gastrointestinal biopsies would be necessary to get a definitive diagnosis. Surgical biopsies are preferred, as all portions of bowel can be accessed.
- To assess for other concurrent causes of hypoalbuminemia, consider the following:
 1. UPC
 2. Pre-and postprandial serum bile acids
 3. A resting cortisol level to screen for hypoadrenocorticism. If resting cortisol level is < 2.0 mcg/dL, an ACTH stimulation test is recommended





The information and recommendations provided are based on the images presented by the referring veterinarian. No evaluation can be communicated regarding pathology that was not visible in the image/video clips provided.

Thank you for this referral. If the clinical or image interpretation does not parallel your findings or if I can be of any further assistance please contact me.

Andrea Nicastro, DVM, Diplomate DACVIM (Small Animal Internal Medicine)
info@SonoPath.com