



PATIENT

Cookie Nagamoto

SPECIES

Canine

BREED

Poodle Mix

SEX

Spayed Female

AGE

14 Years

WEIGHT

17.2 Lbs.

INTERPRETED BY

Andrea Nicastro,
DVM, Diplomate
ACVIM (*Small Animal
Internal Medicine*)

**IMAGING
PERFORMED BY**

Jenna Walsh, CVT

HOSPITAL NAME

West Hills AH

REFERRING VET

Dr. Remcho

DATE

12/2/21

INVOICE

12806

PRESENTING CLINICAL SIGNS

History: Presentation and clinical exam findings: Poor appetite, intermittent diarrhea. HX of IBD with food sensitivities. Also undergoing tx for IVDD. P has a Grade 5/6 SHM without signs of CHF at this time.

Abnormal PE/Chem/CBC/UA Results: August 2021 ALT 282, AST 58, proBNP 1174 Radiographic Findings Radiograph findings: Thorax, abdomen, and survey spinal radiographs (6 images) dated August 9, 2021. Compared to images dated June 11, 2020. THORAX: • There is straightening of the caudal cardiac waist with increased opacity in the region of the left atrium. The VHS measures 9.75, which is within normal limits. • The pulmonary parenchyma is unremarkable. • The pleural space and mediastinum are unremarkable. ABDOMEN: • There are mineral opacities within the renal silhouettes, which is similar compared to the prior study. • The urinary bladder is unremarkable. • The stomach and small intestine are within normal limits with no evidence of pathologic distention or plication. • The liver and spleen are unremarkable. • The abdominal serosal margin detail is normal. MUSCULOSKELETAL: • There is persistent narrowing of the T 13–L1 intervertebral disc space with slightly more pronounced spondylosis deformans. • The skeletal structures are otherwise unremarkable. Assessment: 1. Mild left atriomagalgy. Consider compensated mitral valve disease. No evidence of congestive heart failure. 2. Otherwise, unremarkable thorax. No evidence of pulmonary metastasis or intrathoracic lymphadenopathy. 3. Persistent nephrolithiasis. 4. Otherwise, unremarkable abdomen. 5. Persistent T 13–L1 chronic intervertebral disc degeneration with a more pronounced spondylosis deformans.

ULTRASONOGRAPHIC EXAMINATION OF THE ABDOMEN

Urinary System

The urinary bladder, trigone, and pelvic urethra are normal in thickness and the mucosal surface is smooth. The bladder lumen is moderately distended with anechoic urine. No masses, inflammatory changes or calculi are observed. Ureteral papillae and visualized portion of the proximal urethra, visible to a depth of 2.0 cm, are normal.

The left kidney presented normal size (3.54 cm in length); normal shape and architecture with smooth peripheral margins. There is a normal 1:3 cortex to medulla ratio with minimal to mild loss of corticomedullary distinction. 1-2 small cortical cysts are visualized. Several non-obstructive nephroliths are visualized. There is no evidence of pyelectasia, infarcts or hydroureter. Renal vasculature is normal.

The right kidney is normal in size (3.63 cm in length) with a slightly irregular shape. There is a normal 1:3 cortex to medulla ratio with minimal to mild loss of corticomedullary distinction. Several non-obstructive nephroliths are visualized. There is no evidence of pyelectasia or hydroureter. Renal vasculature is normal.

Adrenal Glands

The left adrenal gland is normal size (0.27 cm at cranial pole) (0.34 cm at caudal pole) (1.21 cm in length); normal shape; homogenous parenchyma. The glandular echogenicity and detail are unremarkable. Capsule, cortex, and medullary definition are normal. The phrenicoabdominal vein and surrounding vasculature are normal.



PATIENT

Cookie Nagamoto

SPECIES

Canine

BREED

Poodle Mix

SEX

Spayed Female

AGE

14 Years

WEIGHT

17.2 Lbs.

INTERPRETED BY

Andrea Nicastro,
DVM, Diplomate
ACVIM (*Small Animal
Internal Medicine*)

**IMAGING
PERFORMED BY**

Jenna Walsh, CVT

HOSPITAL NAME

West Hills AH

REFERRING VET

Dr. Remcho

DATE

12/2/21

INVOICE

12806

The right adrenal gland is normal size (0.72 cm at cranial pole) (0.48 cm at caudal pole) (1.23 cm in length); normal shape; homogenous parenchyma. The glandular echogenicity and detail are unremarkable. Capsule, cortex, and medullary definition are normal. The phrenicoabdominal vein and surrounding vasculature are normal.

Spleen

The spleen is normal in size (1.53 cm at the level of the hilus) with a normal capsular contour. There is appropriate echogenicity and echotexture. Several ill-defined hyperechoic nodules are observed throughout the organ. Splenic vasculature is normal.

Liver

The liver is subjectively prominent in size with slightly swollen peripheral contours. The parenchymal is isoechoic relative to the spleen and has a finely heterogeneous appearance. No distinct focal lesions are observed. Hepatic vasculature and intrahepatic biliary tracts are of normal volume with no evidence of congestion.

The gall bladder is of normal contours and contains some gravity dependent echogenic debris. The wall is normal in thickness. No choleliths are observed. The cystic and common bile ducts are normal/not seen.

Gastrointestinal

The stomach and intestine are free of stasis and exhibit normal peristaltic activity. The gastric lumen is not distended. The gastric wall and pylorus are normal in thickness with a normal layering pattern. The small intestinal lumen is not dilated. The small intestinal wall thickness is normal with a normal layering pattern. There is evidence of mucosal speckling in some segments. Discreet masses are not identified. The colonic wall is normal. There is no evidence of an obstructive pattern.

Pancreas

The region of the pancreas is isoechoic relative to surrounding omental fat. No obvious parenchymal abnormalities are observed. There is no evidence of regional inflammation or effusion.

Free Abdomen

The peritoneal cavity is normal. There is no evidence of inflammation or effusion. The abdominal lymph nodes are normal/not visible.

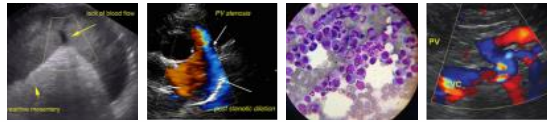
Other

A brief echocardiogram reveals no evidence of pericardial effusion or obvious right atrial/auricular mass.

ULTRASONOGRAPHIC FINDINGS

Primary Findings

- The small intestinal mucosal speckling has been associated with enteritis. However, correlation with clinical findings is recommended.



PATIENT

Cookie Nagamoto

SPECIES

Canine

BREED

Poodle Mix

SEX

Spayed Female

AGE

14 Years

WEIGHT

17.2 Lbs.

INTERPRETED BY

Andrea Nicastro,
DVM, Diplomate
ACVIM (*Small Animal
Internal Medicine*)

**IMAGING
PERFORMED BY**

Jenna Walsh, CVT

HOSPITAL NAME

West Hills AH

REFERRING VET

Dr. Remcho

DATE

12/2/21

INVOICE

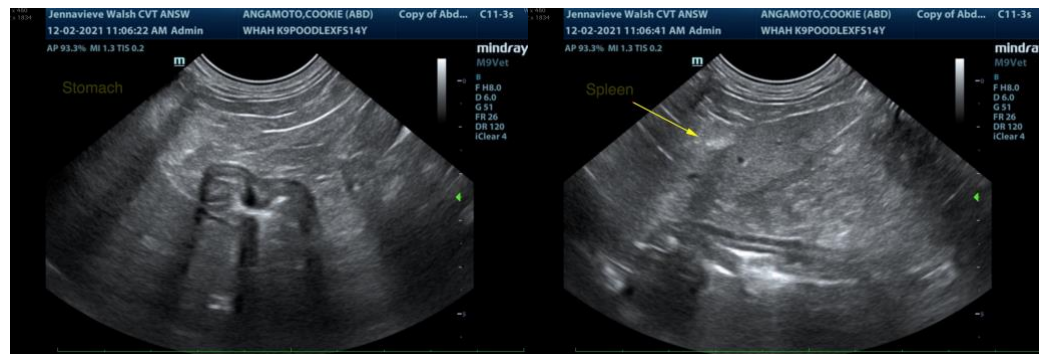
12806

Secondary Findings

- Bilateral non-obstructive nephrolithiasis with age-related renal changes
 - The hyperechoic lesions adjacent to the splenic vessels are most consistent with myelolipomas. Although a neoplastic process within the spleen cannot be excluded, it is considered unlikely in this patient.
- *An obvious cause for the patients' clinical signs is not identified in the study. Considerations include microscopic gastrointestinal (i.e., IBD flare up, infectious/parasitic, intestinal dysbiosis) or pancreatic disease, underlying metabolic issue, other.

INTERPRETATION OF THE FINDINGS & FURTHER RECOMMENDATIONS

- A fecal evaluation for ova/Giardia
- Prophylactic deworming with Fenbendazole at 50 mg/kg once a day for 5 days is recommended. Repeat above protocol in 3 weeks.
- Consider supplementation with a probiotic with a high colony count (i.e., proviable, forte or Visbiome).
- Consider empirical treatment for small intestinal bacterial overgrowth with a 4-week course of Tylosin.
- Other diagnostic considerations include the following:
 1. GI panel (send to Texas A & M)
 2. A resting cortisol level to screen for hypoadrenocorticism. If resting cortisol level is < 2.0 mcg/dL, an ACTH stimulation test is recommended
 3. Ultimately, endoscopic or surgical gastrointestinal biopsies may be necessary to get a definitive diagnosis. A cardiac evaluation should be used to determine whether it is safe for the patient to undergo anesthesia.





PATIENT

Cookie Nagamoto

SPECIES

Canine

BREED

Poodle Mix

SEX

Spayed Female

AGE

14 Years

WEIGHT

17.2 Lbs.

INTERPRETED BY

Andrea Nicastro,
DVM, Diplomate
ACVIM (Small Animal
Internal Medicine)

IMAGING PERFORMED BY

Jenna Walsh, CVT

HOSPITAL NAME

West Hills AH

REFERRING VET

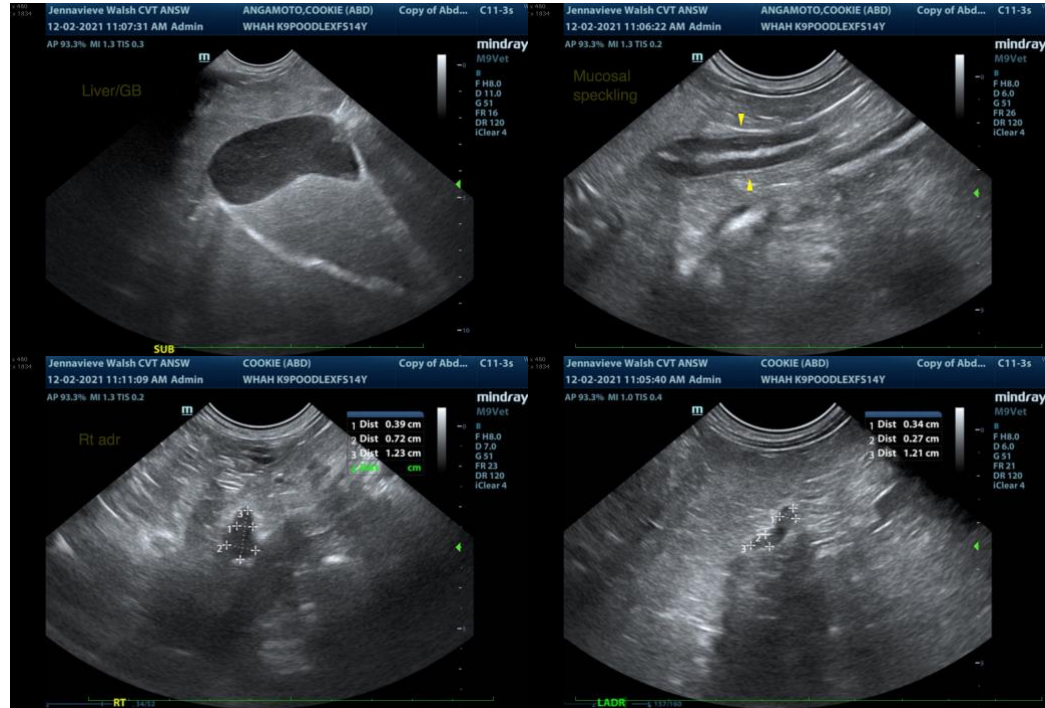
Dr. Remcho

DATE

12/2/21

INVOICE

12806



The information and recommendations provided are based on the images presented by the referring veterinarian. No evaluation can be communicated regarding pathology that was not visible in the image/video clips provided.

Thank you for this referral. If the clinical or image interpretation does not parallel your findings or if I can be of any further assistance please contact me.

Andrea Nicastro, DVM, Diplomate ACVIM (Small Animal Internal Medicine)

andrea_nicastro2@hotmail.com