
PATIENT PRESENTING CLINICAL SIGNS

Ares Gunsinger

History: Diagnosed with diabetes 09/2022. Elevated WBC at this time of unknown origin. Responded well to treatment with Prozac, diabetic diet, and antibiotics. History of increased vomiting in last week and PU despite good control of diabetes. Reluctance to eat food in the last 2 days which is not like him at all. PE relatively unremarkable. Previous history of cholangiohepatitis in 2009. IMPA diagnosed 2012. Went into remission in 2015 to become clinical again in 2018. Herpesvirus positive. Current Medications Prozac 0.5 IU q12h, omeprazole 1 mg/kg given last night. Dexamethasone 0.125 EOD.

SPECIES

Feline

BREED

DSH

SEX

Neutered Male

Abnormal PE/Chem/CBC/UA Results/Abnormal lab-work values:

WBC 27.90 (2.87-17.02), Neut 19.06 (2.3-10.29), Mono 1.67 (0.05-0.67). BG 9.33 (95-8.84), Glob 54 (28-51), ALT 829 (12-130), ALP 189 (14-111), GGT 13 (0-4), Amylase 1508 (500-1500), Lipase 2349 (100-1400). A) Moderate leukocytosis with neutrophilia and monocytosis. Mild hyperglycemia. Severe elevation in ALT, mild elevation in ALP. Mild elevation in amylase, moderate elevation in lipase.

Radiographic Findings Most recent radiographs normal.

ULTRASONOGRAPHIC EXAMINATION OF THE ABDOMEN
Urinary System
AGE

16 years

The urinary bladder and visible portion of the pelvic urethra are normal for the degree of luminal distension. The urine is anechoic with no evidence of debris. Cystic calculi and discrete masses are not observed. The region of the trigone is normal.

WEIGHT

4.7 kg

The left kidney is normal size (3.95 cm in length) with a normal shape, architecture and smooth peripheral margins. There is a normal 1:3 cortex to medulla ratio with moderate loss of corticomedullary distinction. The cortex is hypoechoic. There is no evidence of pyelectasia, nephroliths, infarcts or hydronephrosis. Renal vasculature is normal.

INTERPRETED BY

Andrea Nicastro, DVM,
 Diplomate ACVIM
 (Small Animal Internal
 Medicine)

The right kidney is normal size (4.02 cm in length) with a normal shape, architecture and smooth peripheral margins. There is a normal 1:3 cortex to medulla ratio with normal corticomedullary distinction. There is no evidence of pyelectasia, nephroliths, infarcts or hydronephrosis. Renal vasculature is normal.

Adrenal Glands

The region of the adrenal glands is evaluated. No obvious pathology is observed.

IMAGING PERFORMED BY

Kelly Reschny

Spleen

The spleen is normal in size (0.60 cm in width at the level of the hilus) with a normal capsular contour. There is appropriate echogenicity and echotexture. No focal lesions are observed. Splenic vasculature is normal.

HOSPITAL NAME

Snelgrove VS

Liver

The liver is subjectively normal in size with normal curvilinear peripheral contours. The parenchyma is isoechoic relative to the spleen and homogenous in appearance. Intrahepatic biliary stones are visualized, along with dilation of the intrahepatic bile ducts.

REFERRING VET

Dr. Gunsinger

What is thought to be gall bladder lumen is mildly distended. The wall is normal in thickness. Mineralized debris is suspected within the lumen. The common bile duct is visualized at the level of the duodenal papilla and is dilated (up to 0.41 cm) with subjectively thickened walls. The duodenal papilla is again, 0.80 cm in width. A 0.29 focus of mineralization is also observed at the level of the duodenal papilla.

INVOICE

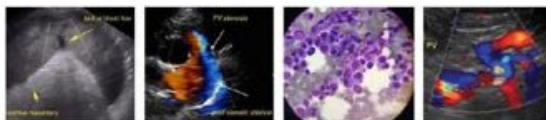
11883

Gastrointestinal

The stomach and intestine are free of stasis and exhibit normal peristaltic activity. The gastric lumen is mildly fluid-distended. The gastric wall and pylorus are normal in thickness with a normal layering

DATE

12.19.22


PATIENT

Ares Gunsinger

pattern. The pyloric outflow tract is patent. The small intestinal lumen is segmentally dilated with chyme (mild). The small intestinal wall thickness is normal with a normal layering pattern and appropriate mural detail. Discreet masses are not identified. The colonic wall is normal. There is no evidence of an obstructive pattern.

SPECIES

Feline

Pancreas

The pancreas is diffusely enlarged with irregular peripheral contours. The parenchyma is hypoechoic relative to surrounding omental fat and nodular in appearance. An approximately 3.00 cm echogenic mass is observed in the region of the left limb. Surrounding mesentery is hyperechoic. The pancreatic duct is dilated (0.29 cm in diameter).

BREED

DSH

Free Abdomen

There is no obvious evidence of free fluid.

SEX

Neutered Male

Lymph nodes

(See "Pancreas").

ULTRASONOGRAPHIC FINDINGS
AGE

16 years

Primary Findings

- Cranial abdominal mass, suspected to be of pancreatic origin. Other possible origins include lymph nodes, mesentery, other. Neoplasia (i.e., adenocarcinoma, other) is suspected. The remaining pancreatic changes are also concerning for neoplasia. Although a benign process (i.e., inflammatory disease with benign nodular hyperplasia) cannot be excluded. Adjacent peritonitis is present.
- The hepatic parenchymal changes are nonspecific and could be secondary to diabetes mellitus, hepatic lipidosis, inflammatory disease (i.e., bacterial cholangiohepatitis, lymphoplasmacytic hepatitis), other hepatopathy. Intrahepatic biliary stones are present and likely incidental.
- The common bile duct changes are most consistent with cholangitis.
- The mineralized focus at the level of the duodenal papilla may be causing a partial obstruction of the common bile duct.

WEIGHT

4.7 kg

INTERPRETED BY

Andrea Nicastro, DVM,
 Diplomate ACVIM
 (Small Animal Internal
 Medicine)

IMAGING PERFORMED BY

Kelly Reschny

Secondary Findings

- Bilateral age-related renal changes

HOSPITAL NAME

Snelgrove VS

INTERPRETATION OF THE FINDINGS & FURTHER RECOMMENDATIONS

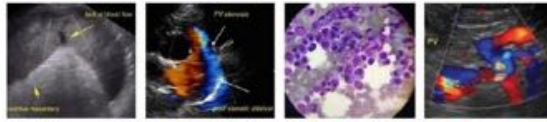
- Three-view thoracic radiographs are recommended to assess for pulmonary metastases.
- Consider fine needle aspirates of the cranial abdominal mass in the region of the pancreas, as well as the liver parenchyma (if clotting status is appropriate). Twenty-five gauge-needles should be used. If cytology results are inconclusive, surgical biopsies may be necessary to get a definitive diagnosis.
- A urinalysis is also recommended to assess for ketonuria.
- While awaiting test results, supportive care for pancreatitis, cholangiohepatitis/cholangitis is recommended.

INVOICE

11883

DATE

12.19.22



PATIENT

Ares Gunsinger

SPECIES

Feline

BREED

DSH

SEX

Neutered Male

AGE

16 years

WEIGHT

4.7 kg

INTERPRETED BY

Andrea Nicastro, DVM,
Diplomate ACVIM
(Small Animal Internal
Medicine)

**IMAGING
PERFORMED BY**

Kelly Reschny

HOSPITAL NAME

Snelgrove VS

REFERRING VET

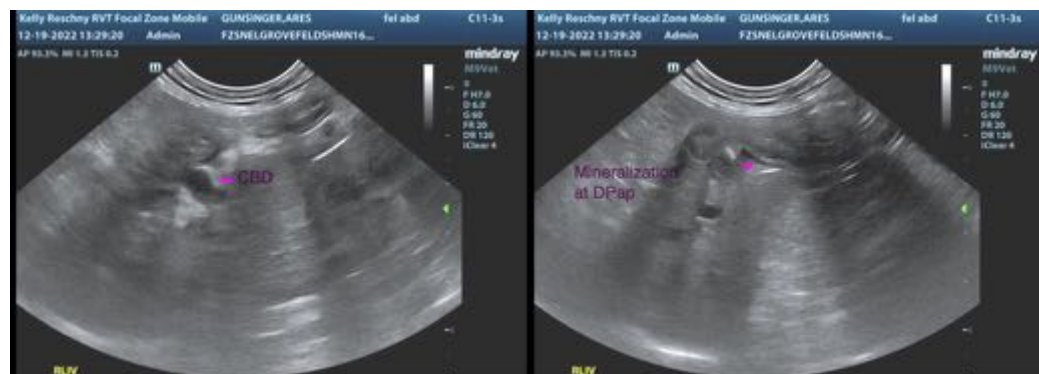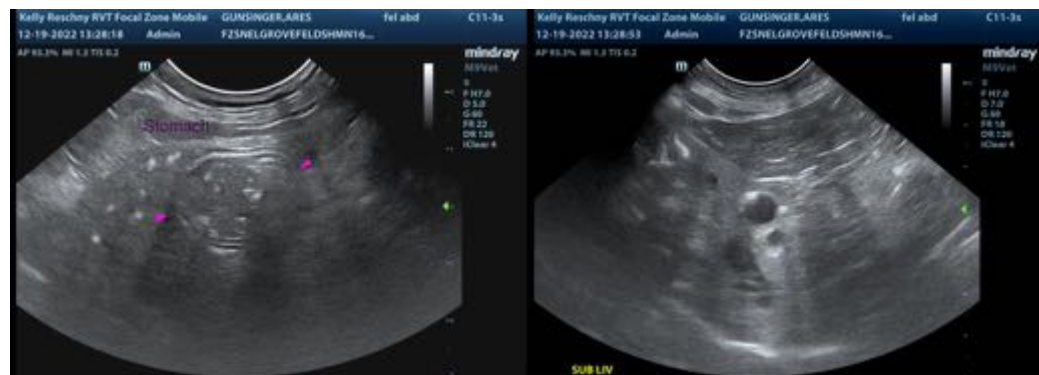
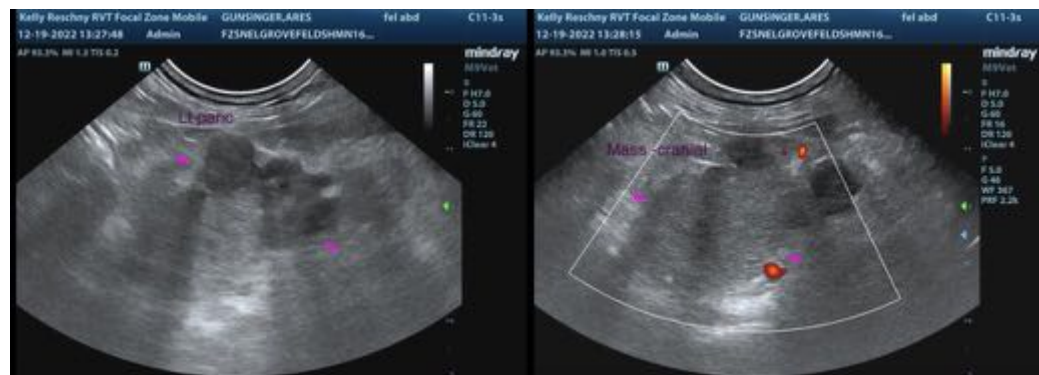
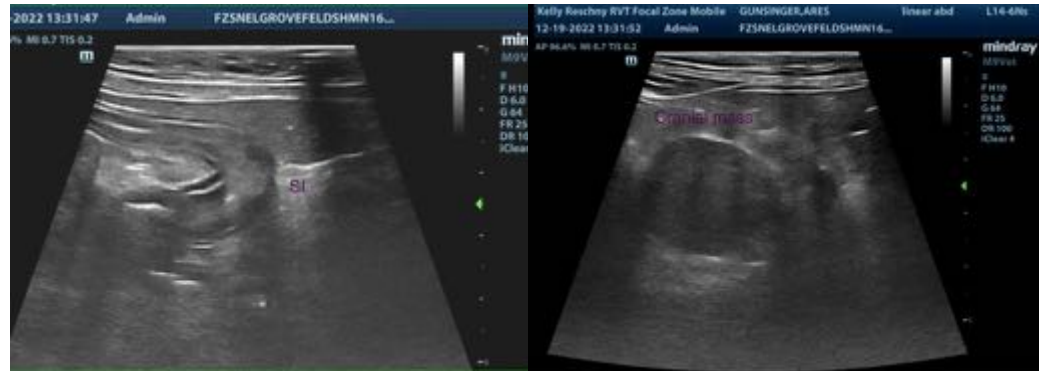Dr. Gunsinger

INVOICE

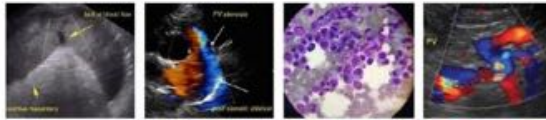
11883

DATE

12.19.22



The information and recommendations provided are based on the images presented by the referring veterinarian/sonographer. No evaluation can be communicated regarding pathology that was not visible in the image/video clips provided.



PATIENT

Ares Gunsinger

Thank you for this referral. If the clinical or image interpretation does not parallel your findings or if I can be of any further assistance, please contact me.

SPECIES

Feline

Andrea Nicaastro, DVM, Diplomate DACVIM (Small Animal Internal Medicine)
info@SonoPath.com

BREED

DSH

SEX

Neutered Male

AGE

16 years

WEIGHT

4.7 kg

INTERPRETED BY

Andrea Nicaastro, DVM,
Diplomate ACVIM
(*Small Animal Internal
Medicine*)

**IMAGING
PERFORMED BY**

Kelly Reschny

HOSPITAL NAME

Snelgrove VS

REFERRING VET

Dr. Gunsinger

INVOICE

11883

DATE

12.19.22