

**DATE PRESENTING CLINICAL SIGNS**

12/16/21

PATIENT

Heidi Rolka

SPECIES

Canine

BREED

Yorkshire Terrier

SEX

Spayed Female

AGE

12/21/10

WEIGHT

16 Lbs.

INTERPRETED BY

Andrea Nicastro, DMV,
Diplomate DACVIM
(Small Animal
Internal Medicine)

IMAGING PERFORMED BY

Stephanie Pearce
RDCS, RVT

HOSPITAL NAME

Everhart VC

REFERRING VET

Dr. Notarangelo

INVOICE

13083

History: Presented for wellness 11/4/21. New heart murmur detected, worsening cough and cardiomegaly noted on x-rays. Lab work showed PSL elevation, proteinuria and alkp elevation. Advise bicavitary study. Additional history: T4 is normal 1.3, inactive urinary sediment.

Current Medications: Started vetmedin 1.25 mg BID (dog is overweight).

Lab Results: ALKP 206, PSL 507, 3+ proteinuria USG 1.029.

Date of Previous IntraPet Ultrasound: No previous IntraPet scans.

Sedation: Not required for a full diagnostic ultrasound.

Stat Report: Not requested.

ULTRASONOGRAPHIC EXAMINATION OF THE ABDOMEN**Urinary System**

The urinary bladder, trigone, and pelvic urethra are normal in thickness and the mucosal surface is smooth. The bladder lumen is moderately distended with anechoic urine. No masses, inflammatory changes or calculi are observed. Ureteral papillae and visualized portion of the proximal urethra, visible to a depth of 2 cm, are normal.

The left kidney is normal in size (4.58 cm in length); with a normal shape and smooth peripheral contours. The cortex is mildly thickened and there is mild loss of corticomedullary distinction. There is no evidence of pyelectasia, nephroliths, infarcts or hydroureter. Renal vasculature is normal.

The right kidney presented normal size (5.02 cm in length); with a normal shape and smooth peripheral contours. The cortex is mildly thickened and there is mild loss of corticomedullary distinction. Hyperechoic shadowing diverticular foci are visualized. There is no evidence of pyelectasia, nephroliths, infarcts or hydroureter. Renal vasculature is normal.

Adrenal Glands

The left adrenal gland is mildly enlarged (0.40 cm at cranial pole) (0.75 cm at caudal pole) (2.47 cm in length); normal shape; homogenous parenchyma. The glandular echogenicity and detail are unremarkable. Capsule, cortex, and medullary definition are normal. The phrenicoabdominal vein and surrounding vasculature are normal.

The right adrenal gland is mildly enlarged (0.61 cm at cranial pole) (0.63 cm at caudal pole) (2.12 cm in length); with a normal shape and smooth peripheral contours. The parenchyma is slightly heterogeneous with mild loss of glandular detail. The phrenicoabdominal vein and surrounding vasculature are normal.

Spleen

The spleen is normal in size (1.20 cm in width at the level of the hilus) with a normal capsular contour. There is appropriate echogenicity and echotexture. No focal lesions are observed. Splenic vasculature is normal.

Liver

The liver is subjectively prominent in size with slightly swollen peripheral contours. The parenchyma is hypoechoic relative to the spleen. A 1.12 cm x 1.02 cm ill-defined multiseptated cystic nodule is observed on the left side. The remaining parenchyma is homogeneous in appearance. Hepatic vasculature and intrahepatic biliary tracts are of normal volume with no evidence of congestion.

The gall bladder lumen is moderately distended. The wall is thin and smooth. A small amount of aggregated echogenic partially dependent debris is observed within the lumen. The cystic and common bile ducts are normal.

Gastrointestinal

The stomach and intestine are free of stasis and exhibit normal peristaltic activity. The gastric lumen is not distended. The gastric wall and pylorus are normal in thickness with a normal layering pattern. The small intestinal lumen is not dilated. The small intestinal wall thickness is normal with a normal layering pattern and appropriate mural detail. Discreet masses are not identified. The colonic wall is normal. No obstructive or overt infiltrative disease is noted.

Pancreas

The left and right limbs of the pancreas are visible with normal curvilinear peripheral contours. The parenchyma is largely isoechoic relative to surrounding omental fat and slightly mottled in appearance. The pancreatic duct is visible but not overtly dilated. There is no evidence of peripancreatic inflammation or effusion.

Free Abdomen

The peritoneal cavity is normal. There is no evidence of inflammation or effusion. The abdominal lymph nodes are normal/not visible.

ULTRASONOGRAPHIC FINDINGS

Primary Findings

- The cystic hepatic nodule may represent a biliary cystadenoma, biliary cystadenocarcinoma, early hemangiosarcoma, benign cystic lesion, other. Histopathology would be necessary to get a definitive diagnosis. The diffuse hepatic parenchymal changes are likely secondary to benign age-related change (i.e., vacuolar hepatopathy).
- Mild bilateral adrenomegaly

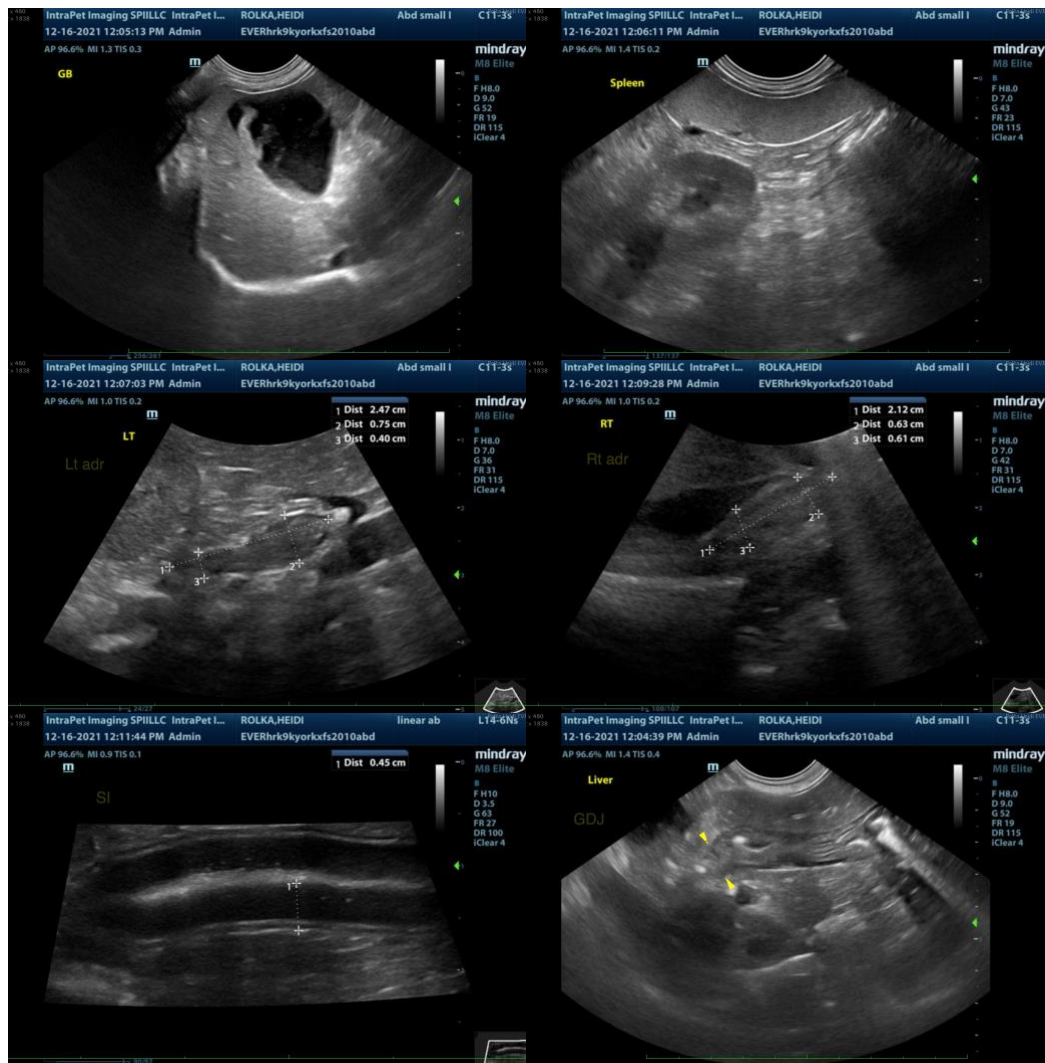
Secondary Findings

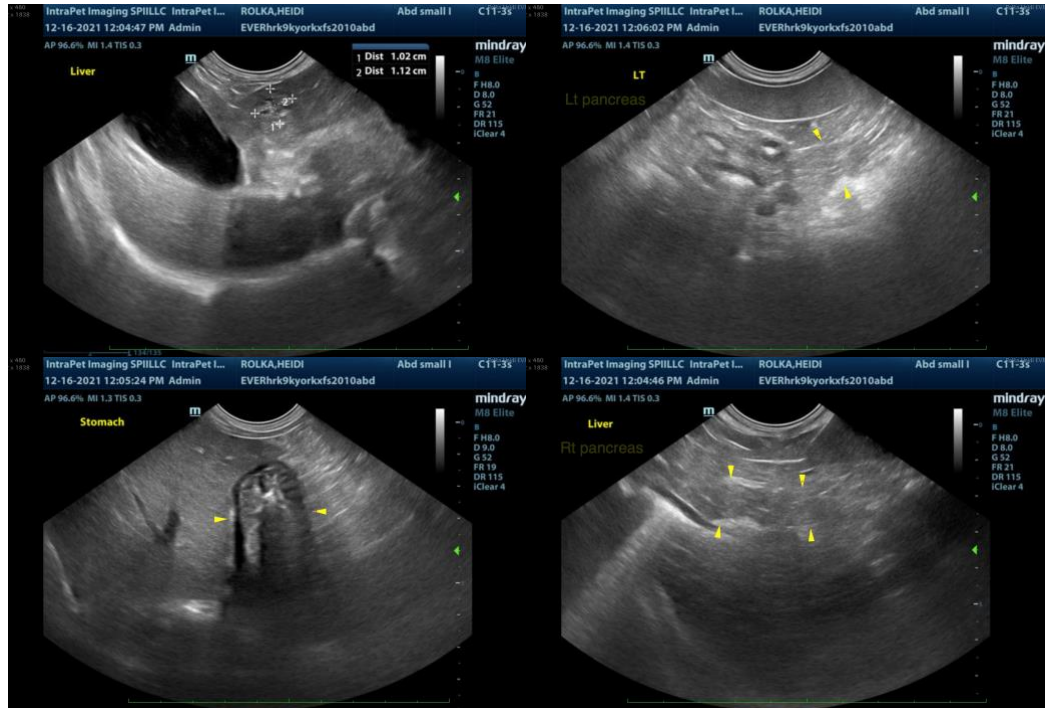
- Minor bilateral age-related renal changes with right dystrophic mineralization
- Age-related pancreatic remodeling.

INTERPRETATION OF THE FINDINGS & FURTHER RECOMMENDATIONS

- Given the proteinuria, a UPC +/- baseline blood pressure measurement should be considered.

- Consider testing for hyperadrenocorticism with a low-dose dexamethasone suppression test or ACTH stimulation test if clinical signs (i.e., PU/PD) develop in the future.
- Regarding the cystic hepatic nodule, if an aggressive approach is desired, an abdominal exploratory with nodule removal and submission for histopathology can be considered. If a more conservative approach is desired, consider a repeat ultrasound in 4-6 weeks to assess for progression.
- Serial monitoring (i.e., every 3-4 months) of the patient's liver values are recommended. If values continue to increase, a repeat abdominal ultrasound +/- pre-and postprandial serum bile acids and hepatic tissue sampling may be warranted.





The information and recommendations provided are based on the images presented by the referring veterinarian. No evaluation can be communicated regarding pathology that was not visible in the image/video clips provided.

Thank you for this referral. If the clinical or image interpretation does not parallel your findings or if I can be of any further assistance please contact me.

Andrea Nicastro, DVM, Diplomate DACVIM (Small Animal Internal Medicine)
info@SonoPath.com