

**DATE PRESENTING CLINICAL SIGNS**

12/16/21

PATIENT

Archie Hilton

SPECIES

Canine

BREEDChihuahua Mixed
Breed**SEX**

Neutered Male

AGE

8/8/12

WEIGHT

9.63 Lbs.

INTERPRETED BYAndrea Nicastro, DMV,
Diplomate DACVIM
(Small Animal
Internal Medicine)**IMAGING
PERFORMED BY**Stephanie Pearce
RDCS, RVT**HOSPITAL NAME**

Everhart VC

REFERRING VET**INVOICE**

13082

History: Patient has a chronic and increasing murmur (also receiving echo today). presented on Monday for severe lethargy, inappetence, labored breathing, dec drinking. Murmur increased in intensity from 2/6 in June 4/6 in Sept, now 5/6 today. Patient hospitalized for cardiac care, admin Lasix, Pimo, Amoxicillin. cardiac status improved during the day and remains stable today on 10mg Lasix, 1.25mg Pimo. Lethargy continues, decreased appetite continues despite improvement in resp rates. Unclear if additional pathology leading to lethargy, dec appetite or primary cardiac only. labs submitted 12/14 show no significant abnormalities.

Current Medications: Biomox, Pimo, Lasix.

Lab Results: NSF. Attached separately.

Radiographs: Thx rads on Monday showed cardiomegaly with cardiogenic pulmonary edema.

Date of Previous IntraPet Ultrasound: No previous IntraPet scans.

Sedation: Not required for a full diagnostic ultrasound.

Stat Report: Not requested.

ULTRASONOGRAPHIC EXAMINATION OF THE ABDOMEN**Urinary System**

The urinary bladder, trigone, and pelvic urethra are normal in thickness and the mucosal surface is smooth. The bladder lumen is moderately distended with anechoic urine. No masses, inflammatory changes or calculi are observed. Ureteral papillae and visualized portion of the proximal urethra, visible to a depth of 2 cm, are normal.

The prostate is normal in size (0.88 cm in width) and shape. Parenchyma is homogenous. The prostatic urethra appears normal without evidence of dilation or obstruction.

The left kidney presented normal size (3.70 cm in length); normal shape and architecture with smooth peripheral margins. There is a normal 1:3 cortex to medulla ratio with minimal loss of corticomedullary distinction. A hyperechoic medullary band is observed adjacent to the corticomedullary junction. Trace pyelectasia is present. There is no evidence of nephroliths, infarcts or hydroureter. Renal vasculature is normal.

The right kidney presented normal size (3.32 cm in length); normal shape and architecture with smooth peripheral margins. There is a normal 1:3 cortex to medulla ratio with minimal loss of corticomedullary distinction. A hyperechoic medullary band is observed adjacent to the corticomedullary junction. Trace pyelectasia is present. There is no evidence of nephroliths, infarcts or hydroureter. Renal vasculature is normal.

Adrenal Glands

The left adrenal gland is normal size (0.36 cm at cranial pole) (0.42 cm at caudal pole) (1.29 cm in length); normal shape; homogenous parenchyma. The glandular echogenicity and detail are unremarkable. Capsule, cortex, and medullary definition are normal. The phrenicoabdominal vein and surrounding vasculature are normal.

The right adrenal gland is normal size (0.61 cm at cranial pole) (0.45 cm at caudal pole) (1.53 cm in length); normal shape; homogenous parenchyma. The glandular echogenicity and detail are unremarkable. Capsule, cortex, and medullary definition are normal. The phrenicoabdominal vein and surrounding vasculature are normal.

Spleen

The spleen is subjectively normal in size (0.69 cm in width at the level of the hilus) with slightly irregular peripheral contours. A 0.99 cm x 0.65 cm irregular hyperechoic nodule is observed within the parenchyma. The remaining parenchyma is homogeneous in appearance. Splenic vasculature appears normal with no evidence of thrombosis.

Liver

The liver is subjectively normal in size with normal contours and structure. There is appropriate echogenicity and echotexture. No overt structural evidence of inflammatory, infiltrative or regenerative pathology is evident. Vascular and biliary tracts are of normal volume with no evidence of congestion. No pathological hepatic lymphadenopathy observed.

The gall bladder lumen is moderately distended. The wall is thin and smooth. A small amount of aggregated echogenic partially dependent debris/sludge is observed within the lumen. The cystic and common bile ducts are normal.

Gastrointestinal

The stomach and intestine are free of stasis and exhibit normal peristaltic activity. The gastric lumen is not distended. The gastric wall and pylorus are normal in thickness with a normal layering pattern. The small intestinal lumen is not dilated. The small intestinal wall thickness is normal with a normal layering pattern and appropriate mural detail. Discreet masses are not identified. The colonic wall is normal. The colonic lumen contains granular appearing fecal material. There is no evidence of an obstructive pattern.

Pancreas

The region of the pancreas is isoechoic relative to surrounding omental fat. No obvious parenchymal abnormalities are observed. There is no evidence of regional inflammation or effusion.

Free Abdomen

The peritoneal cavity is normal. There is no evidence of inflammation or effusion. The abdominal lymph nodes are normal/not visible.

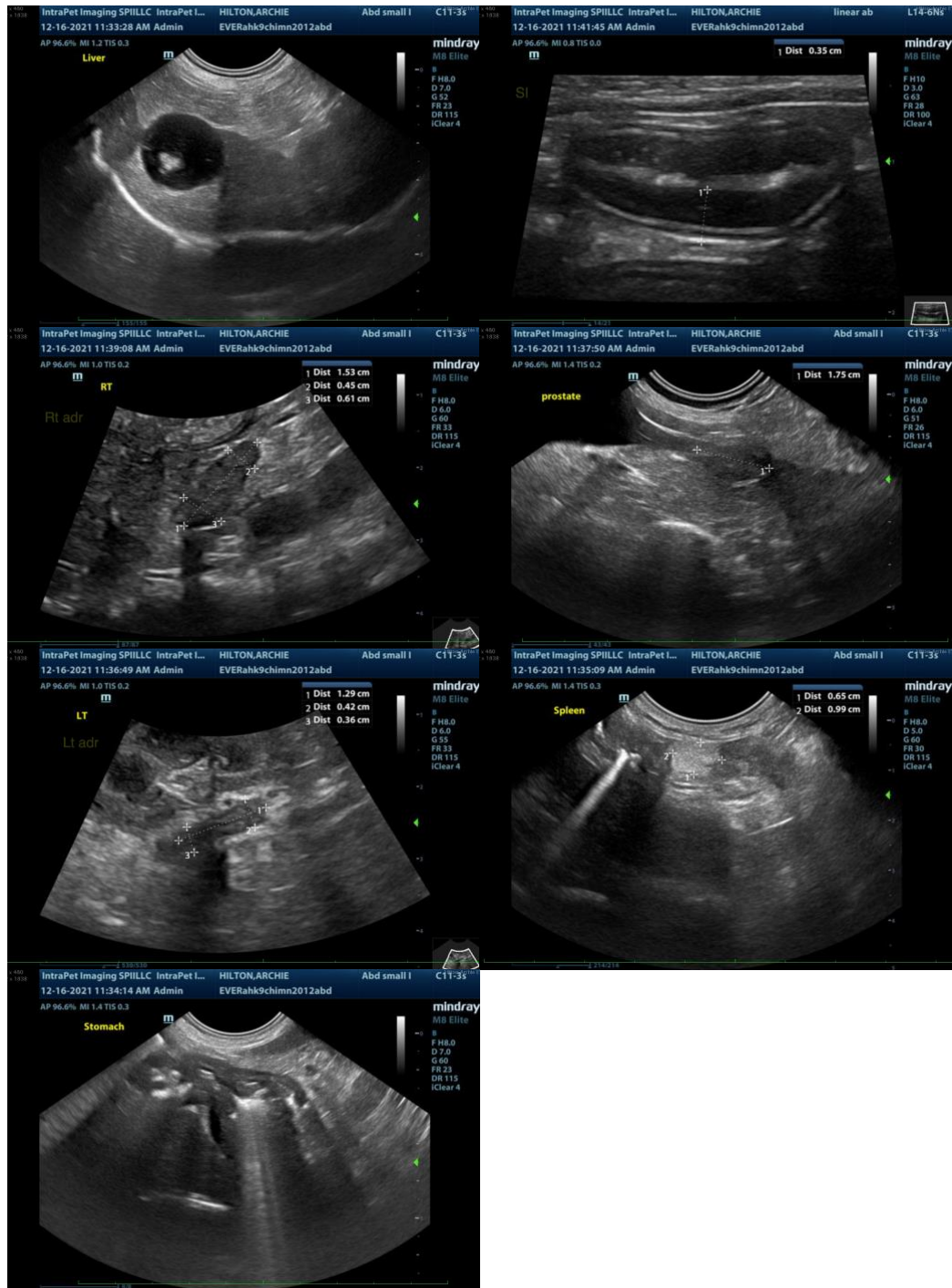
ULTRASONOGRAPHIC FINDINGS

- Minor nonspecific age-related renal changes
- The hyperechoic splenic nodule trends toward the benign (i.e., myelolipoma or focus of lymphoid hyperplasia) with lower potential for emerging neoplasia.

*An obvious cause for the patient's decreased appetite and lethargy is not identified in the abdomen.

INTERPRETATION OF THE FINDINGS & FURTHER RECOMMENDATIONS

- If the clinical signs persist despite persistently stable cardiac disease, a more advanced GI work up (i.e., fecal evaluation for ova and Giardia, malabsorption panel, etc.) may be warranted.



The information and recommendations provided are based on the images presented by the referring veterinarian. No evaluation can be communicated regarding pathology that was not visible in the image/video clips provided.

Thank you for this referral. If the clinical or image interpretation does not parallel your findings or if I can be of any further assistance please contact me.

Andrea Nicastro, DVM, Diplomate DACVIM (Small Animal Internal Medicine)
info@SonoPath.com