



DATE PRESENTING CLINICAL SIGNS

12/15/25

Patient History: Historic elevation of ALKP. Seen on 12/12/25 for infrequent loose stool, abdomen tense and appears distended on exam. Lab work indicated a cholestatic hepatopathy, not noted previously.

PATIENT

Watson Clayton

Current Medications: Ursodiol 30mg tablets- GIVE 1 TABLET BY MOUTH EVERY 24 HOURS UNTIL FURTHER DIRECTED. Denamarin Advanced Feline and Small Canine (up to 12lbs)- Give 1 tablet every 24 hours until gone

SPECIES

Canine

Convenia 80mg/ml Injectable- 0.39 mls SQ.

Labwork Results: Labwork not submitted but reported as IOF--ALKP 580 H, ALT 141 H, CHOL 332 H, GGT 15 H. CBC--WBC 17.59 H LYM 0.75 L, NEU 15.08 H, EOS 0.96 H, PLT 592 H. Lytes: K 3.3 L.

Date of Previous IntraPet Ultrasound: 9/2024. See attached.

BREED

Maltese

Sedation: Not required to complete full diagnostic ultrasound.

Stat Report: Not requested.

Imaging Performed by: Andi Parkinson, BS, RDMS.

SEX

Male, neutered

ULTRASONOGRAPHIC EXAMINATION OF THE ABDOMEN

Urinary System

The urinary bladder is distended. The wall is normal in thickness with a smooth mucosal surface. Gravity-dependent mineralized sand +/- tiny calculi are observed within the lumen. Some mineralized debris is also suspected within the proximal urethra. The visible portion of the urethra is not overtly dilated.

AGE

2/17/2013

The prostate is normal in size (0.87 cm in width) and shape. Parenchyma is homogenous. The prostatic urethra appears normal without evidence of dilation or obstruction.

WEIGHT

3.9 kg.

The left kidney is normal in size (3.72 cm in length) with a normal shape, architecture and smooth peripheral margins. There is a normal 1:3 cortex to medulla ratio with mild loss of corticomedullary distinction. A few small non-obstructive mineralized foci are visualized. There is no evidence of pyelectasia, infarcts or hydroureter.

INTERPRETED BY

Andrea Nicastro, DVM,
Diplomate ACVIM
(Small Animal Internal
Medicine)

The right kidney is normal in size (3.91 cm in length) with a normal shape, architecture and smooth peripheral margins. There is a normal 1:3 cortex to medulla ratio with mild to moderate loss of corticomedullary distinction. A few small non-obstructive mineralized foci are visualized. There is no evidence of pyelectasia, infarcts or hydroureter.

HOSPITAL NAME

Banfield Pet Hospital
Towson

Adrenal Glands

The left adrenal gland is mildly enlarged (0.54 cm at cranial pole) (0.57 cm at caudal pole) with a normal shape and homogenous parenchyma. The glandular echogenicity and detail are unremarkable. Capsule, cortex, and medullary definition are normal. The phrenicoabdominal vein and surrounding vasculature are normal.

REFERRING VET

Dr. Manning

The right adrenal gland is mildly enlarged (0.42 cm at cranial pole) (0.57 cm at caudal pole) with a normal shape and homogenous parenchyma. The glandular echogenicity and detail are unremarkable. Capsule, cortex, and medullary definition are normal. The phrenicoabdominal vein and surrounding vasculature are normal.

INVOICE

13432

Spleen

The spleen is normal in size (1.12 cm in width at the level of the hilus) with a normal capsular contour. There is appropriate echogenicity and echotexture. No focal lesions are observed. Splenic vasculature is normal.

Liver

The liver is subjectively enlarged with swollen peripheral contours. The parenchyma is isoechoic relative to the spleen and subtly heterogeneous in appearance with several ill-defined hyperechoic nodules throughout the organ, one of the nodules measuring 1.6 cm in its longest dimension. Vascular and biliary tracts are of normal volume with no evidence of congestion.

The gall bladder is distended. The wall is normal in thickness. A large amount of aggregated, echogenic, partially dependent to suspended sludge is observed within the lumen. The cystic and common bile ducts are normal/not seen.

Gastrointestinal

The gastric lumen is not distended. The gastric wall and pylorus are normal in thickness with a normal layering pattern. The pyloric outflow tract is patent. The small intestinal lumen is not dilated. The small intestinal wall is normal in thickness with a normal layering pattern and appropriate mural detail. Discreet masses are not identified. The colonic wall is normal. There is no evidence of an obstructive pattern.

Pancreas

The right limb of the pancreas is visible with normal curvilinear peripheral contours. The parenchyma is largely isoechoic relative to surrounding omental fat and slightly mottled in appearance. The pancreatic duct is visible but not overtly dilated. There is no evidence of peripancreatic inflammation or effusion.

Lymph nodes

The abdominal lymph nodes are normal/not visible.

Free Abdomen

The peritoneal cavity is normal. There is no evidence of inflammation or effusion.

ULTRASONOGRAPHIC FINDINGS

Primary Findings:

- The gallbladder changes are consistent with a developing mucocele.
- The diffuse hepatic changes are most consistent with vacuolar hepatopathy (i.e., endocrine, idiopathic) with a lower possibility of inflammatory disease, infiltrative neoplasia, or other hepatopathy. The hyperechoic hepatic nodules trend toward the benign (i.e., regenerative nodules, meylolipomas) with a lower possibility of more insidious hepatic pathology (i.e., inflammatory lesions, neoplasia).
- Urinary bladder/urethral sand +/- tiny cystic calculi

Secondary Findings:

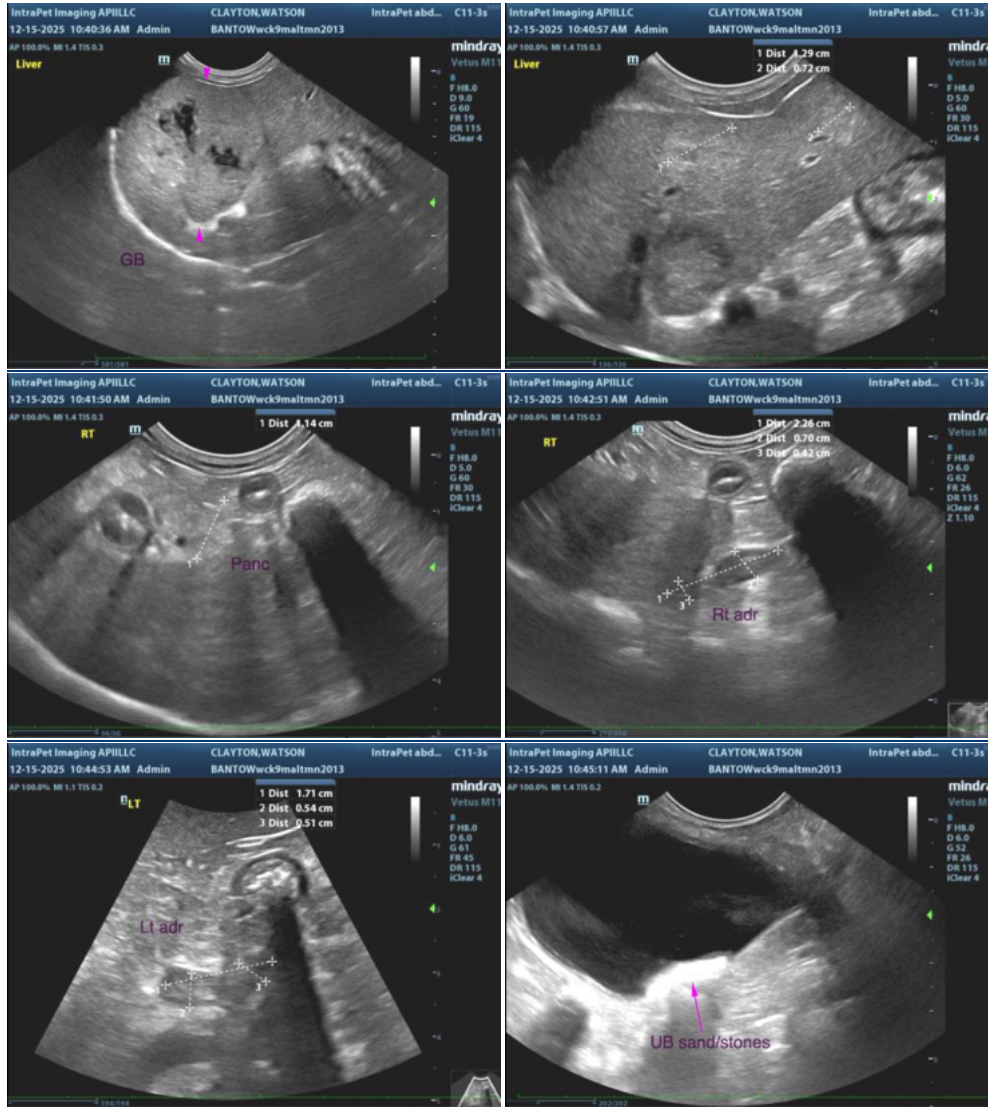
- Borderline bilateral adrenomegaly
- The pancreatic changes are most consistent with age-related parenchymal remodeling, potentially secondary to a prior inflammatory episode, early fibrosis or chronic pancreatitis.
- Bilateral nonspecific, age-related renal changes with non-obstructive nephrolithiasis

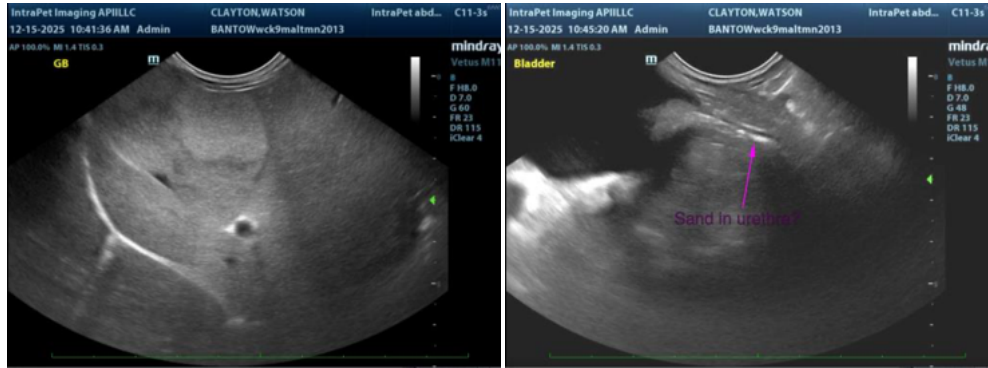INTERPRETATION OF THE FINDINGS & FURTHER RECOMMENDATIONS

1. Regarding the hepatobiliary changes, if an aggressive approach is desired consider a cholecystectomy with submission of the gallbladder for histopathology and cultures. Liver biopsies should also be obtained at the time of surgery. If a more conservative approach is desired, continuation of Ursodiol therapy is recommended along with serial sonographic monitoring (i.e., every 4-6 weeks) to assess for progression to a fully formed mucocele. Hepatic antioxidants are also recommended. Serial

monitoring (i.e., every 2-3 months) of the patient's liver values should also be performed to assess progression.

- Regarding the urinary bladder sand (+/- calculi), consider a cystotomy with stone removal, analysis and culture. Otherwise, an attempt at medical dissolution can be considered.





The information and recommendations provided are based on the images presented by the referring veterinarian/sonographer. No evaluation can be communicated regarding pathology that was not visible in the image/video clips provided.

Thank you for this referral. If the clinical or image interpretation does not parallel your findings or if I can be of any further assistance please contact me.

Andrea Nicastro, MPH, DVM, Diplomate DACVIM (Small Animal Internal Medicine) info@SonoPath.com