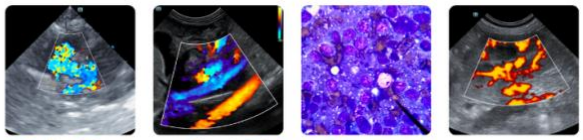

Clinical Sonography & Telecytology
Educational Teleconsultation Services™

PATIENT
Steve Guerriero

SPECIES
Feline

BREED
DSH

SEX
Neutered Male

AGE
12

WEIGHT
14.5 lbs

INTERPRETED BY
Andrea Nicastro DVM
Diplomate ACVIM
(Sm Animal Internal Med)

IMAGING PERFORMED BY
Shari Reffi, CVT

HOSPITAL NAME
Newton VH

REFERRING VET
Dr. Chabora

INVOICE
22268

DATE
12-15-25

PRESENTING CLINICAL SIGNS

History: Azotemia, decreased appetite, possibly thickened, firm bladder.
Meds: IVF, Cerenia, Unasyn, Baytril (Alfaxalone for scan)
Abnormal PE/Chem/CBC/UA Results: Bun 104.4; Cr 4.9; USG: 1.012; few RBCs, wbcs, cocci. Transitional cells

ULTRASONOGRAPHIC EXAMINATION OF THE ABDOMEN

Urinary System

The urinary bladder wall is normal in thickness. The mucosal surface is smooth. The bladder is moderately distended. Luminal contents are mostly anechoic. No cystic calculi are observed. The region of the trigone and visible portion of the proximal urethra are normal.

The left kidney is small in size (2.45 cm in length) with slightly irregular shape. The cortex is hyperechoic relative to the spleen and variably thickened. There is moderate to severe loss of corticomedullary distinction. A few, small, mineralized foci are visualized. Severe pyelectasia is present (0.49 cm) in the longitudinal plane. The ureter is slightly dilated (0.19 cm in diameter), hyperechoic and irregular. The ureter can be followed for several centimeters, after which it is no longer visible. The ureteral wall appears thickened, hyperechoic, and irregular. Renal perfusion appears reduced.

The right kidney is enlarged (5.18 cm in length) with swollen peripheral contours. The cortex is thickened. There is moderate loss of corticomedullary distinction. Severe pyelectasia is present (0.45 cm in the transverse plane). Hyperechoic shadowing diverticular foci are visualized. There is no evidence of infarcts. The right proximal ureter is mildly distended. Renal vasculature is normal. The mesentery surrounding the kidney is hyperechoic.

Adrenal Glands

The left adrenal gland is normal size (0.30 cm width). Normal shape and glandular echogenicity. The phrenicoabdominal vein and surrounding vasculature are normal.

The right adrenal gland is normal size (0.37 cm width). Normal shape and glandular echogenicity. The phrenicoabdominal vein and surrounding vasculature are normal.

Spleen

The spleen is normal in size (0.84 cm in width at the level of the hilus) with a normal capsular contour. There is appropriate echogenicity and echotexture. No focal lesions are observed. Splenic vasculature is normal.

Liver

The liver is subjectively normal in size with normal curvilinear peripheral contours. The parenchyma is isoechoic relative to the spleen and diffusely homogeneous in appearance. No distinct focal lesions are observed. Vascular and biliary tracts are of normal volume with no evidence of congestion.

The gallbladder is of normal contours and contains some dependent echogenic debris. The wall is normal in thickness. No choleliths are observed. The cystic and common bile ducts are normal.

Gastrointestinal

The stomach and intestine are free of stasis and exhibit normal peristaltic activity. The gastric lumen is not distended. The gastric wall and pylorus are normal in thickness with a normal layering pattern. The pyloric outflow tract is patent. The small intestinal lumen is not dilated. The small intestinal wall thickness is normal. There is disruption in the normal 1:3 muscularis: mucosal ratio in most segments. Discreet masses

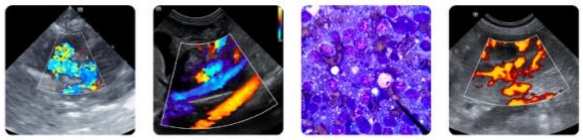

PATIENT
Steve Guerriero

SPECIES
Feline

BREED
DSH

SEX
Neutered Male

AGE
12

WEIGHT
14.5 lbs

INTERPRETED BY
Andrea Nicastro DVM
Diplomate ACVIM
(Sm Animal Internal Med)

IMAGING PERFORMED BY
Shari Reffi, CVT

HOSPITAL NAME
Newton VH

REFERRING VET
Dr. Chabora

INVOICE
22268

DATE
12-15-25

are not identified. The ileocecal colic junction and colonic wall are normal. The proximal colonic lumen contains soft, liquid-appearing fecal material. There is no obvious evidence of an obstructive pattern.

Pancreas
The left limb of the pancreas is visible with normal curvilinear peripheral contours. The parenchyma is largely isoechoic relative to surrounding omental fat and slightly mottled in appearance. The pancreatic duct is visible but not overtly dilated. There is no evidence of peripancreatic inflammation or effusion.

Lymph Nodes
The abdominal lymph nodes are normal/not visible.

Free Abdomen
There is no obvious evidence of free fluid.

Other
In the left mid- to caudal abdomen, a 1.4 cm shadowing structure is visualized within the mesentery.

ULTRASONOGRAPHIC FINDINGS

Primary Findings

- Bilateral chronic renal changes with left renal atrophy. There is evidence of diffuse left ureteritis. Right cranial retroperitonitis is present. The right renomegaly may be secondary to compensatory hypertrophy, interstitial nephrosis/nephritis, or less likely, infiltrative neoplasia. The bilateral pyelectasia may be secondary to pyelonephritis, parenchymal remodeling, PU/PD (if applicable), ureteral obstructions (i.e., stricture, stones, inflammation, tumors, other).

Secondary Findings

- The small intestinal could be consistent with inflammatory bowel disease or may be a normal variant for this older feline patient. Correlation with the patient's long-term clinical history is recommended.
- The pancreatic changes are most consistent with age-related parenchymal remodeling, potentially secondary to a prior inflammatory episode, early fibrosis or chronic pancreatitis.
- The shadowing structure within the mesentery in the mid- to caudal abdomen likely represents a Bate's body. These are typically mineralized foci within the mesenteric fat and are typically a benign incidental finding.

INTERPRETATION OF THE FINDINGS & FURTHER RECOMMENDATIONS

- Given the patient's clinical history and sonographic changes, consider the following:

  1. Urinalysis with culture and sensitivity
  2. UPC if proteinuria is present in the absence of infection
  3. Baseline blood pressure measurement
  4. IV fluid diuresis with serial monitoring of the patient's renal values to assess progression of the azotemia
  5. Three-view thoracic radiographs should also be considered to assess cardiopulmonary status, particularly if the patient is to undergo IV fluid diuresis.
  6. Consider transitioning to a prescription renal diet once the patient is eating normally.

New Jersey Mobile
FUELED BY SONOPATH VETERINARY ULTRASOUND

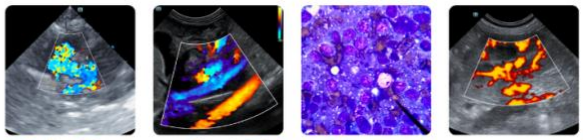

Clinical Sonography & Telecytology
Educational Teleconsultation Services™

SonoPath
FOSTERING THE ART OF VETERINARY MEDICINE™
www.SonoPath.com
info@sonopath.com 800.838.4268

PATIENT

Steve Guerriero

SPECIES

Feline

BREED

DSH

SEX

Neutered Male

AGE

12

WEIGHT

14.5 lbs

INTERPRETED BY

Andrea Nicastro DVM
Diplomate ACVIM
(Sm Animal Internal Med)

IMAGING PERFORMED BY

Shari Reffi, CVT

HOSPITAL NAME

Newton VH

REFERRING VET

Dr. Chabora

INVOICE

22268

DATE

12-15-25

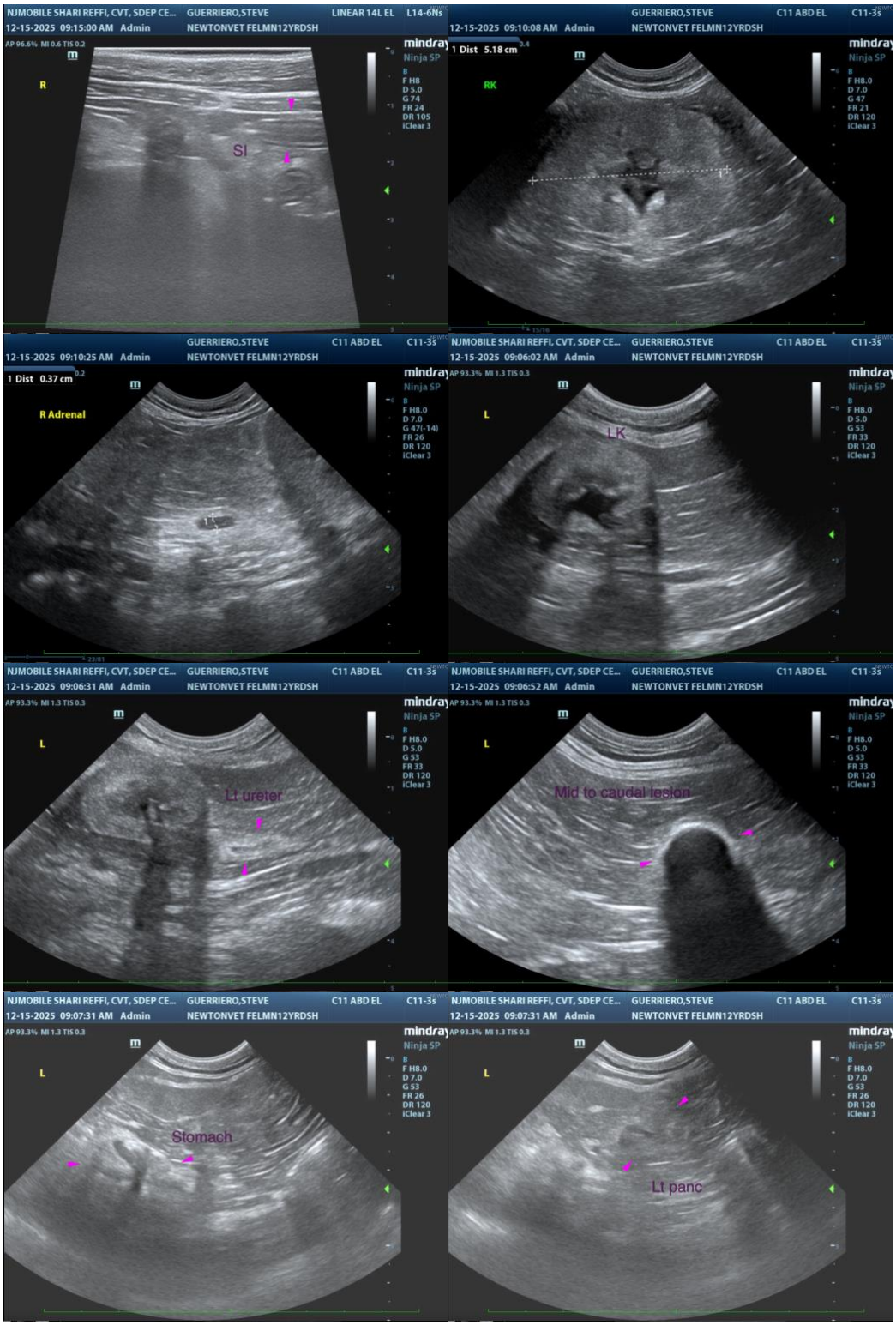

New Jersey Mobile
FUELED BY SONOPATH VETERINARY ULTRASOUND

SonoPath
FOSTERING THE ART OF VETERINARY MEDICINE™
www.SonoPath.com
info@sonopath.com 800.838.4268

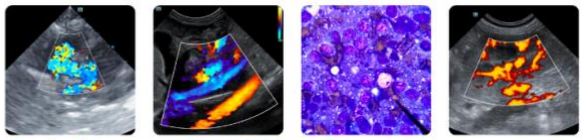

Clinical Sonography & Telecytology
Educational Teleconsultation Services™

PATIENT

Steve Guerriero

SPECIES

Feline

BREED

DSH

SEX

Neutered Male

AGE

12

WEIGHT

14.5 lbs

INTERPRETED BY

Andrea Nicastro DVM
Diplomate ACVIM
(Sm Animal Internal Med)

IMAGING PERFORMED BY

Shari Reffi, CVT

HOSPITAL NAME

Newton VH

REFERRING VET

Dr. Chabora

INVOICE

22268

DATE

12-15-25

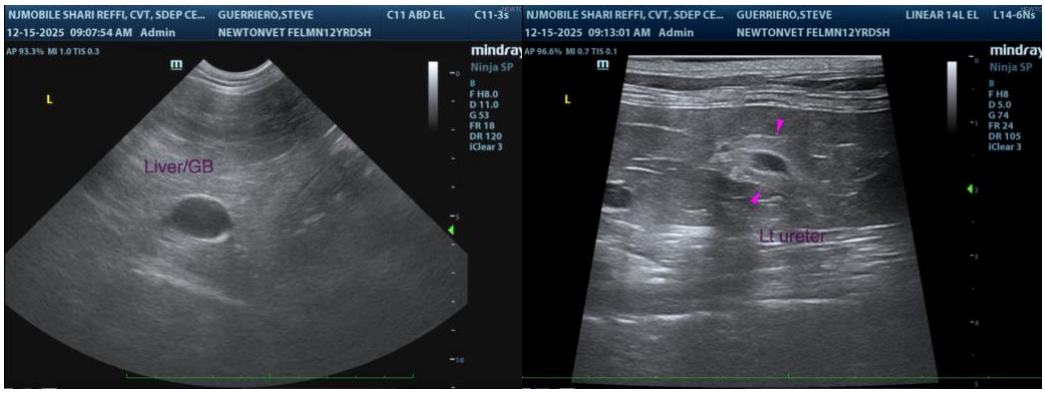

The information and recommendations provided are based on the images presented by the referring veterinarian/sonographer. No evaluation can be communicated regarding pathology that was not visible in the image/video clips provided.

Thank you for this referral. If the clinical or image interpretation does not parallel your findings or if I can be of any further assistance, please contact me.
Andrea Nicastro, MPH, DVM, Diplomate DACVIM (Small Animal Internal Medicine)
info@SonoPath.com