



DATE PRESENTING CLINICAL SIGNS

12/15/25

Patient History: P Presented for progressive weight loss and inappetence over the past several months. October 2024 – Wt 11.6 lbs, July 2025 10.5 lbs, August 9.3 lbs Sept 8.9 lbs. Now 8.02 lbs. P would have occasional intermittent vomiting and would cry for food but then not would eat / only lick gravy, seems to have more of an appetite for fish based foods. Per O p has history of pancreatitis in the past and had previous US that showed mild IBD in 2022. P had a urinary blockage in the past as well and had been on RC SO until appetite started to decline. PE - large amount of gas and increased borborygmi noted on palpation and auscultation of abdomen. PE otherwise unremarkable

PATIENT

Ramis Greaves

SPECIES

Feline

BREED

Domestic shorthair

SEX

Male, neutered

AGE

11/26/2013

WEIGHT

8.02 lbs.

INTERPRETED BY

Andrea Nicastro, DVM,
Diplomate ACVIM
(Small Animal Internal
Medicine)

HOSPITAL NAME

Northwind AH

REFERRING VET

Dr. Repsher

INVOICE

13433

ULTRASONOGRAPHIC EXAMINATION OF THE ABDOMEN

Urinary System

The urinary bladder wall is normal in thickness and the mucosal surface is smooth. The bladder is moderately distended. A small to moderate amount of suspended echogenic debris is observed within the lumen. No cystic calculi are observed. The region of the trigone and the visible portion of the proximal urethra are normal.

The left kidney is normal in size (3.33 cm in length) with a normal shape, architecture and smooth peripheral margins. There is a normal 1:3 cortex to medulla ratio with mild to moderate loss of corticomedullary distinction. There is no evidence of pyelectasia, nephroliths, infarcts or hydroureter. Renal vasculature is normal.

The right kidney is normal in size (3.81 cm in length) with a normal shape, architecture and smooth peripheral margins. There is a normal 1:3 cortex to medulla ratio with mild to moderate loss of corticomedullary distinction. There is no evidence of pyelectasia, nephroliths, infarcts or hydroureter. Renal vasculature is normal.

Adrenal Glands

The left adrenal gland is normal size (0.36 cm width). Normal shape and glandular echogenicity. The phrenicoabdominal vein and surrounding vasculature are normal.

The right adrenal gland is normal size (0.42 cm width). Normal shape and glandular echogenicity. The phrenicoabdominal vein and surrounding vasculature are normal.

Spleen

The spleen is normal in size (0.88 cm in width at the level of the hilus) with a normal capsular contour. There is appropriate echogenicity and echotexture. No focal lesions are observed. Splenic vasculature is normal.

Liver

The liver is subjectively normal in size with normal curvilinear peripheral contours. The parenchyma is isoechoic relative to the spleen and diffusely homogeneous in appearance. No distinct focal lesions are

observed. Vascular and biliary tracts are of normal volume with no evidence of congestion. The portal vein to caudal vena cava ratio is approximately 1:1.

The gall bladder lumen is moderately distended. The wall is thin and smooth. A small amount of suspended echogenic debris is observed within the lumen. The cystic and common bile ducts are normal/not seen.

Gastrointestinal

The stomach and intestine are free of stasis and exhibit normal peristaltic activity. The gastric lumen is not distended. The gastric wall and pylorus are normal in thickness with a normal layering pattern. The pyloric outflow tract is patent. The small intestinal lumen is not dilated. The small intestinal wall is normal to mildly thickened (up to 0.33 cm). There is disruption in the normal 1:3 muscularis: mucosal ratio. Discrete masses are not identified. The ileocecal colic junction and colonic wall are normal. No obstructive disease is noted.

Pancreas

The region of the pancreas is isoechoic relative to surrounding omental fat. No obvious parenchymal abnormalities are observed. There is no evidence of regional inflammation or effusion.

Lymph nodes

A few prominent mesenteric lymph nodes are visualized, one of the nodes measuring 0.98 x 0.35 cm.

Free Abdomen

There is no obvious evidence of free fluid.

ULTRASONOGRAPHIC FINDINGS

Primary Findings:

- The small intestinal wall changes could be consistent with inflammatory bowel disease or emerging small cell lymphoma.
- The prominent abdominal lymph nodes are most consistent with reactive lymphadenitis or lymphoid hyperplasia. Neoplastic infiltration is considered less likely.

Secondary Findings:

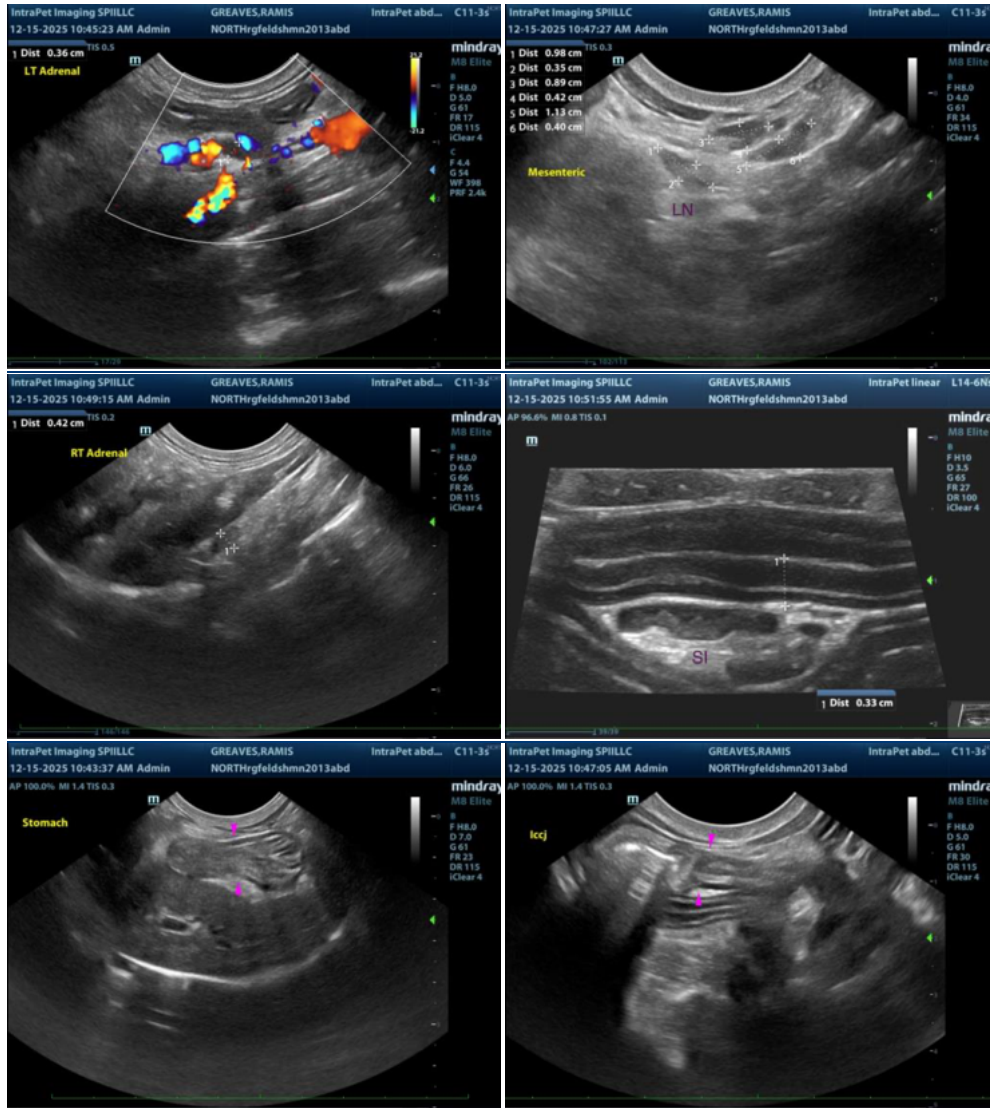
- Bilateral nonspecific, age-related renal changes
- Urinary bladder debris

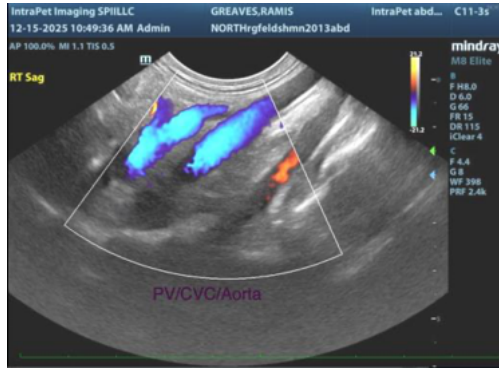
*Overall, changes are similar to the previous sonogram.

INTERPRETATION OF THE FINDINGS & FURTHER RECOMMENDATIONS

1. Consider a fecal evaluation for ova and Giardia along with a GI panel including serum cobalamin, folate, TLI and PLI.
2. Three-view thoracic radiographs are recommended to assess for occult pathology in the chest.
3. A limited antigen or hydrolyzed protein diet is recommended once the patient's appetite has normalized.
4. Ultimately, GI biopsies (i.e., endoscopic or surgical) may be necessary to get a definitive diagnosis. If biopsies are not pursued, consider empirical treatment for inflammatory bowel disease (i.e.,

corticosteroids, limited antigen diet) as long as the client understands the risk of treatment without a definitive diagnosis.





The information and recommendations provided are based on the images presented by the referring veterinarian/sonographer. No evaluation can be communicated regarding pathology that was not visible in the image/video clips provided.

Thank you for this referral. If the clinical or image interpretation does not parallel your findings or if I can be of any further assistance please contact me.

Andrea Nicastro, MPH, DVM, Diplomate DACVIM (Small Animal Internal Medicine) info@SonoPath.com