



## PATIENT PRESENTING CLINICAL SIGNS

Baby Shyda

History: Presenting for acute, profuse vomiting since last night progressing to foamy hematemesis with marked lethargy; owner estimates ~30 episodes overnight. Owner reports chronic vomiting being managed with long-acting steroid shot at primary care. No diagnostics have ever been performed.

### SPECIES

Feline

Abnormal PE/Chem/CBC/UA Results: 8-10% dehydration, intestines palpate thickened and fluid filled  
Bloodwork CBC: WBC 27.07, NEU 24.41, EOS 0.14 CHEM15: CREA 0.6, GGT 18 FPL: 5.4 - in the equivocal range (4.5 - 8.7 U/L), pancreatitis is possible EPOC: PO2 142.3, CSO2 99.1, BE -6.8, LAC 3.95, GLU 169

### BREED

DSH

Radiographs:

### SEX

Female Spayed

- Stomach: The stomach contains a small amount of gas and is void of abnormal intraluminal contents. On the left lateral projection, there is adequate gas opacification of the pyloric antrum, highlighting no abnormalities at the pyloroduodenal junction. The stomach is not overdistended.
- Small intestine: The small intestine is mostly homogeneously soft tissue opaque and is diffusely normal in diameter.

### AGE

14

## ULTRASONOGRAPHIC EXAMINATION OF THE ABDOMEN

### WEIGHT

4.61 kg

#### Urinary System

The urinary bladder wall is normal in thickness. The mucosal surface is smooth. The bladder is distended. A moderate amount of suspended echogenic debris is observed within the lumen. No cystic calculi are observed. The region of the trigone and visible portion of the proximal urethra are normal.

### INTERPRETED BY

Andrea Nicastro, DVM,  
Diplomate ACVIM  
(Small Animal Internal  
Medicine)

The left kidney is normal in size (3.48 cm in length) with a normal shape, smooth peripheral margins, and normal internal architecture. There is mild loss of corticomedullary distinction. Several hyperechoic shadowing diverticular foci are observed. Trace pyelectasia is present. There is no evidence of infarcts or hydronephrosis. Renal vasculature is normal.

### IMAGING PERFORMED BY

Lindsay Powell, CVT

The right kidney is normal in size (3.53 cm in length) with a normal shape, smooth peripheral margins, and normal internal architecture. There is mild to moderate loss of corticomedullary distinction. Several hyperechoic shadowing diverticular foci are observed. Trace pyelectasia is present (0.11 cm in the longitudinal plane). There is no evidence of infarcts or hydronephrosis. Renal vasculature is normal.

### HOSPITAL NAME

Hershey AEC

#### Adrenal Glands

The left adrenal gland is normal size (0.36 cm width). Normal shape and glandular echogenicity. The phrenicoabdominal vein and surrounding vasculature are normal.

### REFERRING VET

Dr. Brittany Lang

The right adrenal gland is normal size (0.36 cm width). Normal shape and glandular echogenicity. The phrenicoabdominal vein and surrounding vasculature are normal.

### INVOICE

22266

#### Spleen

The spleen is normal in size (0.95 cm in width at the level of the hilus) with a normal capsular contour. There is appropriate echogenicity and echotexture. No focal lesions are observed. Splenic vasculature is normal.

### DATE

12-15-25

#### Liver

The liver is subjectively normal in size with normal curvilinear peripheral contours. The parenchyma is isoechoic relative to the spleen and diffusely homogeneous in appearance. No distinct focal lesions are observed. Vascular and biliary tracts are of normal volume with no evidence of congestion.



## PATIENT

Baby Shyda

The gallbladder lumen is moderately distended. The wall is thin and smooth. Luminal contents are mostly anechoic. The cystic and common bile ducts are normal. The duodenal papilla is normal-in-size (0.23 cm in width).

## SPECIES

Feline

### *Gastrointestinal*

The gastric lumen is minimally fluid-distended. The gastric wall and pylorus are normal in thickness with a normal layering pattern. The pyloric outflow tract is patent. The small intestinal lumen is not dilated. The small intestinal wall is normal in thickness. There is slight disruption in the normal 1:3 muscularis: mucosal ratio in some segments. In one jejunal segment, the mesentery effacing the serosal surface is hyperechoic. The ileocecolic junction and colonic wall are normal. There is no obvious evidence of an obstructive pattern.

## BREED

DSH

## SEX

Female Spayed

### *Pancreas*

The left limb of the pancreas surrounding is visible with normal curvilinear peripheral contours. The parenchyma is largely isoechoic relative to omental fat and slightly mottled in appearance. The pancreatic duct is visible but not overtly dilated. There is no evidence of peripancreatic inflammation or effusion.

## AGE

14

### *Lymph Nodes*

The abdominal lymph nodes are normal/not visible.

## WEIGHT

4.61 kg

### *Free Abdomen*

There is no obvious evidence of free fluid.

## INTERPRETED BY

Andrea Nicastro, DVM,  
Diplomate ACVIM  
(Small Animal Internal  
Medicine)

## ULTRASONOGRAPHIC FINDINGS

### Primary Findings

- The small intestinal wall changes could be consistent with inflammatory bowel disease or may be a normal variant for this older feline patient. Emerging small cell lymphoma is also possible. There is evidence of mild peritonitis associated with one jejunal segment.

## IMAGING PERFORMED BY

Lindsay Powell, CVT

### Secondary Findings

- Bilateral nonspecific age-related renal changes. The bilateral trace pyelectasia could be consistent with parenchymal remodeling, pyelonephritis, PU/PD (if applicable), or some combination thereof.
- The urinary bladder could be consistent with cells, crystals, exfoliated material, mucus, and/or lipid droplets.
- The pancreatic changes are most consistent with age-related parenchymal remodeling, potentially secondary to a prior inflammatory episode, early fibrosis or chronic pancreatitis.

## HOSPITAL NAME

Hershey AEC

## REFERRING VET

Dr. Brittany Lang

## INTERPRETATION OF THE FINDINGS & FURTHER RECOMMENDATIONS

## INVOICE

22266

The following diagnostic/treatment recommendations can be considered:

## DATE

12-15-25

1. Serum cobalamin, folate, PLI and TLI
2. A fecal evaluation for ova/Giardia
3. 3-4-week limited antigen or hydrolyzed protein diet trial to assess for food allergies when the patient's clinical status has stabilized.
4. Initiation with a probiotic may also prove beneficial.



**PATIENT**

Baby Shyda

**SPECIES**

Feline

**BREED**

DSH

**SEX**

Female Spayed

**AGE**

14

**WEIGHT**

4.61 kg

**INTERPRETED BY**

Andrea Nicastro, DVM,  
Diplomate ACVIM  
(Small Animal Internal  
Medicine)

**IMAGING  
PERFORMED BY**

Lindsay Powell, CVT

**HOSPITAL NAME**

Hershey AEC

**REFERRING VET**

Dr. Brittany Lang

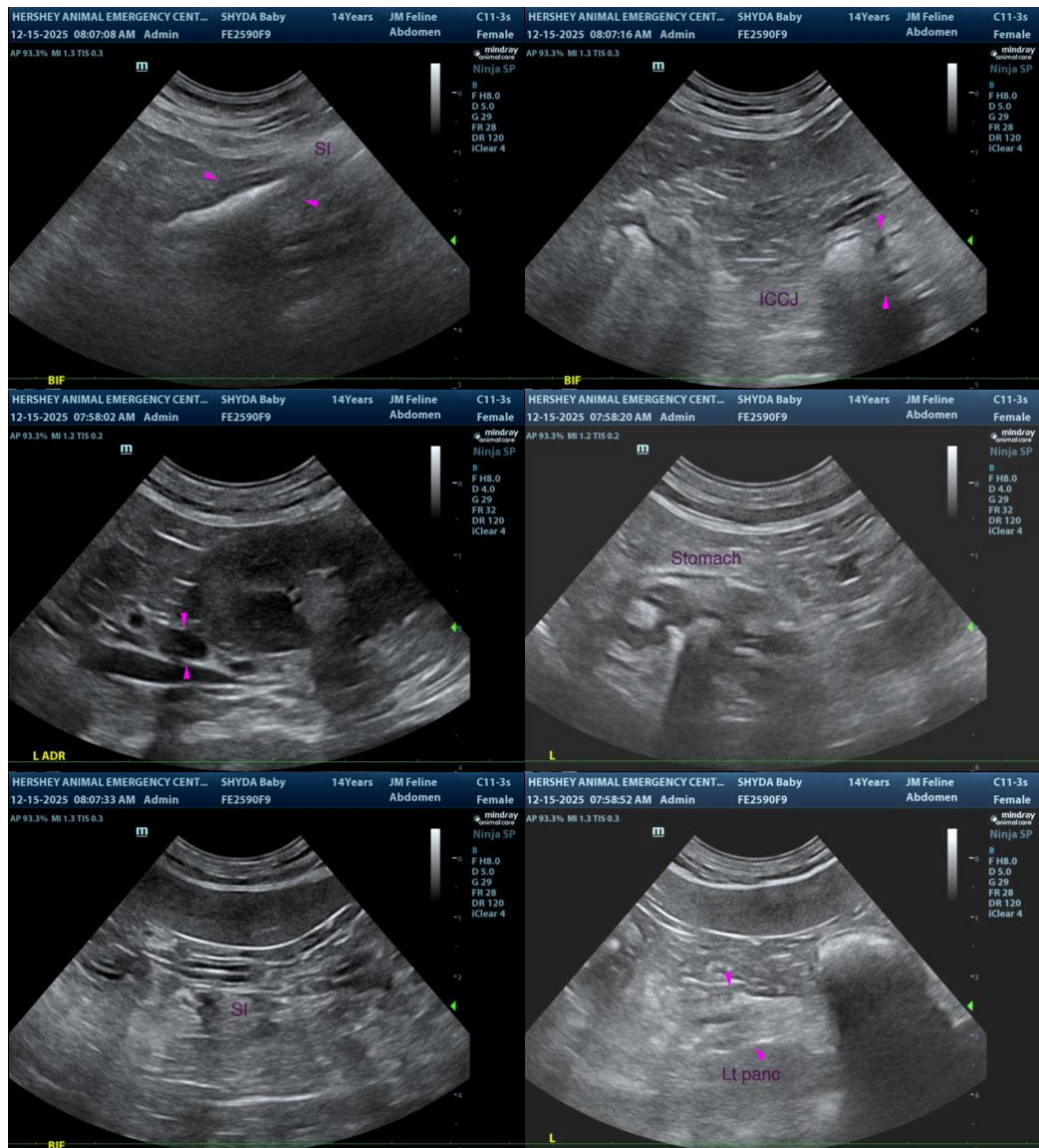
**INVOICE**

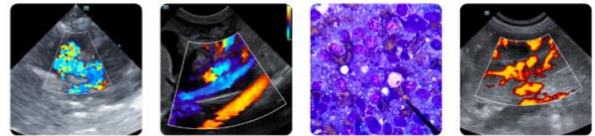
22266

**DATE**

12-15-25

5. If the above diagnostics/therapeutics are inconclusive, endoscopic or surgical gastrointestinal biopsies may be warranted. Thoracic radiographs are recommended prior to anesthesia.
6. For patients where chronic vomiting is present but additional diagnostics are not to be performed, consider empirical treatment for Helicobacter gastritis, which includes a 14–21-day course of amoxicillin, metronidazole, clarithromycin and an acid blocker (i.e., omeprazole or famotidine)
7. In the meantime, symptomatic care, including empirical treatment for gastric ulceration, is recommended.





**PATIENT**

Baby Shyda

**SPECIES**

Feline

**BREED**

DSH

**SEX**

Female Spayed

**AGE**

14

**WEIGHT**

4.61 kg

**INTERPRETED BY**

Andrea Nicastro, DVM,  
Diplomate ACVIM  
(Small Animal Internal  
Medicine)

**IMAGING  
PERFORMED BY**

Lindsay Powell, CVT

**HOSPITAL NAME**

Hershey AEC

**REFERRING VET**

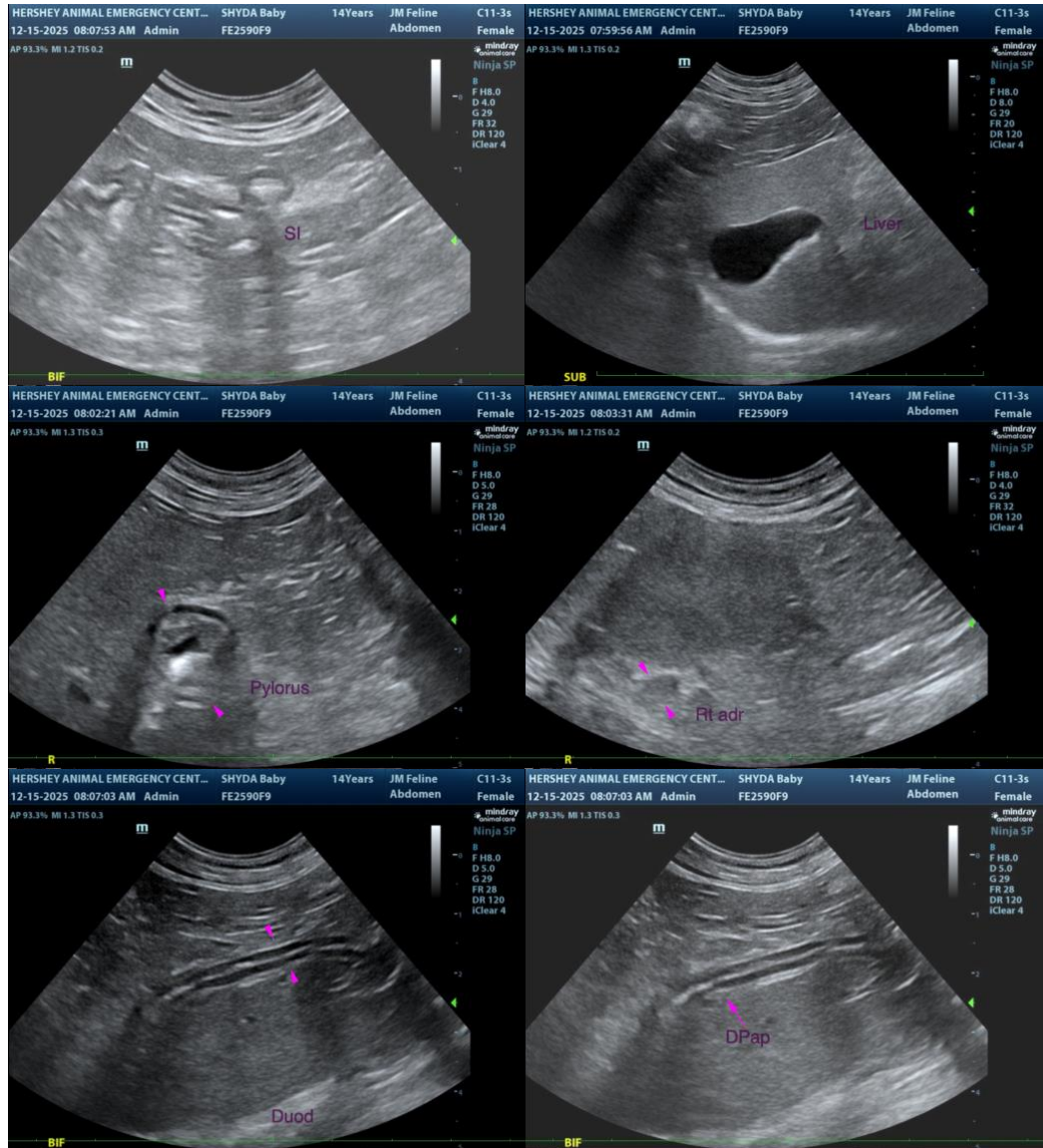
Dr. Brittany Lang

**INVOICE**

22266

**DATE**

12-15-25



The information and recommendations provided are based on the images presented by the referring veterinarian/sonographer. No evaluation can be communicated regarding pathology that was not visible in the image/video clips provided.

Thank you for this referral. If the clinical or image interpretation does not parallel your findings or if I can be of any further assistance, please contact me.

**Andrea Nicastro, MPH, DVM, Diplomate DACVIM (Small Animal Internal Medicine)**  
[info@SonoPath.com](mailto:info@SonoPath.com)