


**PATIENT PRESENTING CLINICAL SIGNS**

<b>PATIENT</b>	Elmo Morales
<b>SPECIES</b>	Canine
<b>BREED</b>	Cocker Spaniel
<b>SEX</b>	Neutered Male
<b>AGE</b>	13 years
<b>WEIGHT</b>	30 lbs
<b>INTERPRETED BY</b>	Andrea Nicastro, DVM, Diplomate ACVIM ( <i>Small Animal Internal Medicine</i> )
<b>IMAGING PERFORMED BY</b>	Dr. Ferrer DVM
<b>HOSPITAL NAME</b>	Paseos VC
<b>REFERRING VET</b>	Dra. Maricarmen Vega
<b>INVOICE</b>	11851
<b>DATE</b>	12.15.22

History: Presented as a referral for an abdominal ultrasound to evaluate elevated liver enzymes and hematuria. PT presented with a history of an episode of hematuria 2 weeks ago. Went to EC clinic and radiographs were taken and no major abnormalities were noticed. Pt relapsed and developed hematuria again and responded to oral antibiotics that were given at the EC clinic. Differential diagnosis Mass or stones no visible on radiographs or antibiotics-resistant cystitis. Currently on Enrofloxacin, Galliprant and Denamarin.

Abnormal PE/Chem/CBC/UA Results: No PE information provided. Chemistry on November 16th, 2022, showed ALP (575).

Chemistry December 5th: ALT (130), ALP (1,286), GGT (13)

**ULTRASONOGRAPHIC EXAMINATION OF THE ABDOMEN**
**Urinary System**

The urinary bladder wall is normal in thickness and the mucosal surface is smooth. The bladder lumen is moderately distended with anechoic urine. No masses, inflammatory changes or calculi are observed. Ureteral papillae and visualized portion of the proximal urethra, visible to a depth of 2 cm, are normal.

The prostate is normal in size (1.17 cm in width) and shape. Parenchyma is homogenous. The prostatic urethra appears normal without evidence of dilation or obstruction.

The left kidney is normal size (6.08 cm in length) with a normal shape, architecture and smooth peripheral margins. There is a normal 1:3 cortex to medulla ratio with minimal to mild loss of corticomedullary distinction. There is no evidence of pyelectasia, nephroliths, infarcts or hydroureter.

The right kidney is normal size (6.26 cm in length) with a normal shape, architecture and smooth peripheral margins. There is a normal 1:3 cortex to medulla ratio with minimal to mild loss of corticomedullary distinction. There is no evidence of pyelectasia, nephroliths, infarcts or hydroureter.

**Adrenal Glands**

The left adrenal gland is mildly enlarged (0.68 cm at cranial pole) (0.82 cm at caudal pole) (2.80 cm in length) with a slightly irregular shape and homogenous parenchyma. The glandular echogenicity and detail are unremarkable. Capsule, cortex, and medullary definition are normal. The phrenicoabdominal vein and surrounding vasculature are normal.

The right adrenal gland is normal size (0.80 cm at cranial pole) (0.62 cm at caudal pole) (2.66 cm in length) with a normal shape and homogenous parenchyma. The glandular echogenicity and detail are unremarkable. Capsule, cortex, and medullary definition are normal. The phrenicoabdominal vein and surrounding vasculature are normal.

**Spleen**

The spleen is normal in size (1.66 cm in width at the level of the hilus) with a normal capsular contour. The parenchyma is subtly mottled in appearance. No focal lesions are observed. Splenic vasculature is normal.

**Liver**

The liver is normal to slightly prominent in size with normal curvilinear peripheral contours. The parenchyma is isoechoic relative to the spleen and diffusely homogeneous in appearance. No distinct focal lesions are observed. Vascular and biliary tracts are of normal volume with no evidence of congestion.

The gall bladder is distended. The wall is normal in thickness. A moderate to large amount of organized suspended sludge, in a stellate pattern is observed within the lumen, along with a moderate amount of gravity dependent suspended debris. The cystic and common bile ducts are normal/not seen. The mesentery surrounding the gall bladder is mildly hyperechoic.

### ***Gastrointestinal***

The stomach and intestine are free of stasis and exhibit normal peristaltic activity. The gastric lumen is not distended. The gastric wall and pylorus are normal in thickness with a normal layering pattern. The pyloric outflow tract is patent. The small intestinal lumen is not dilated. The small intestinal wall thickness is normal with a normal layering pattern and appropriate mural detail. Discreet masses are not identified. The colonic wall is normal. There is no evidence of an obstructive pattern.

### ***Pancreas***

The region of the pancreas is isoechoic relative to surrounding omental fat. No obvious parenchymal abnormalities are observed. There is no evidence of regional inflammation or effusion.

### ***Free Abdomen***

There is no evidence of free fluid. One to two prominent mesenteric lymph nodes are visualized, the largest measuring 1.63 cm in length.

## **ULTRASONOGRAPHIC FINDINGS**

### **Primary Findings**

- The gall bladder changes are consistent with a fully-formed mucocele. Adjacent peritonitis is present. Concurrent cholecystitis may be present.
- Nonspecific diffuse hepatopathy. Differentials include inflammatory disease (i.e., bacterial cholangiohepatitis, chronic hepatitis), vacuolar hepatopathy (i.e., endocrine, idiopathic), hepatotoxicosis (i.e., copper), other hepatopathy.

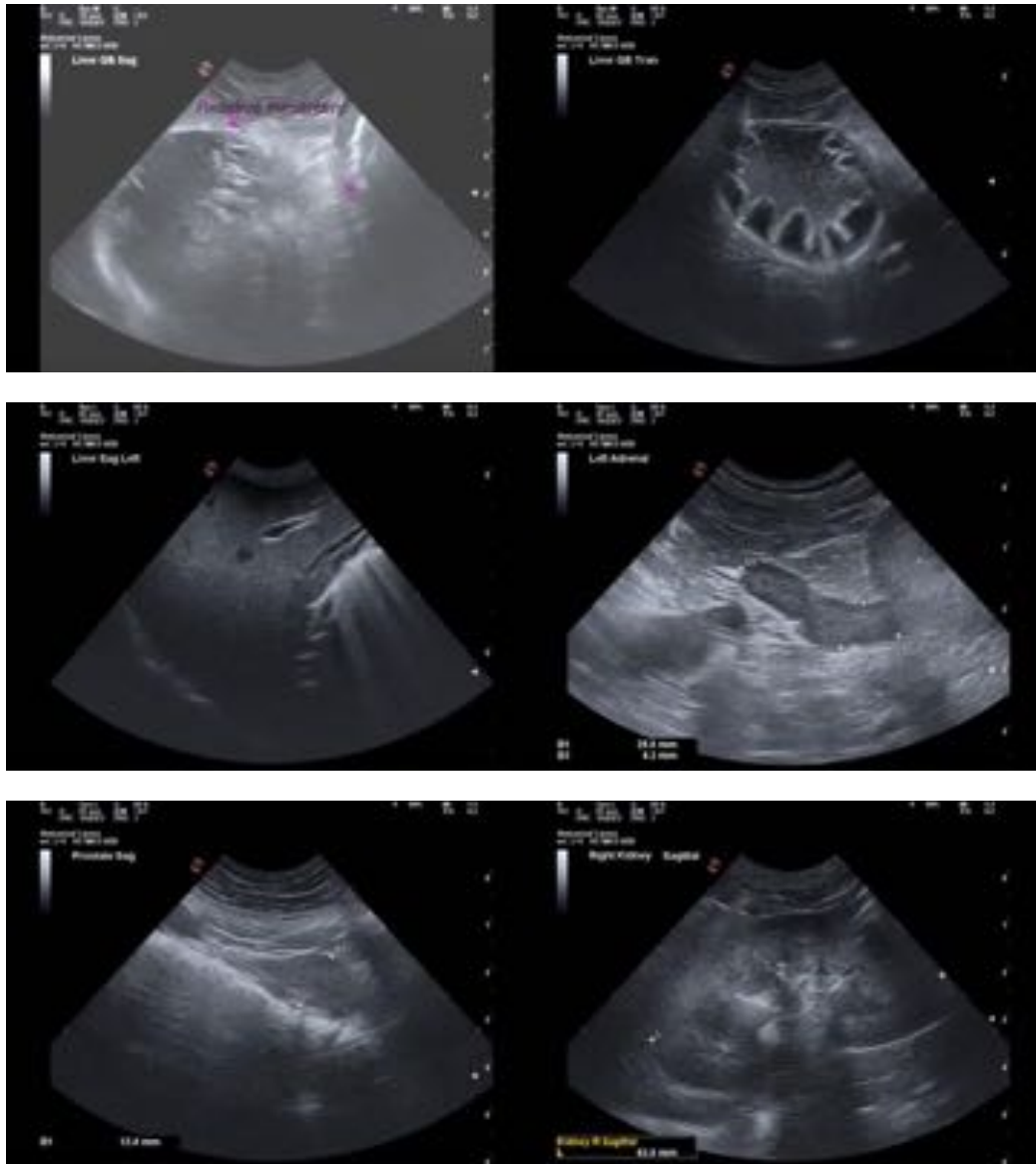
### **Secondary Findings**

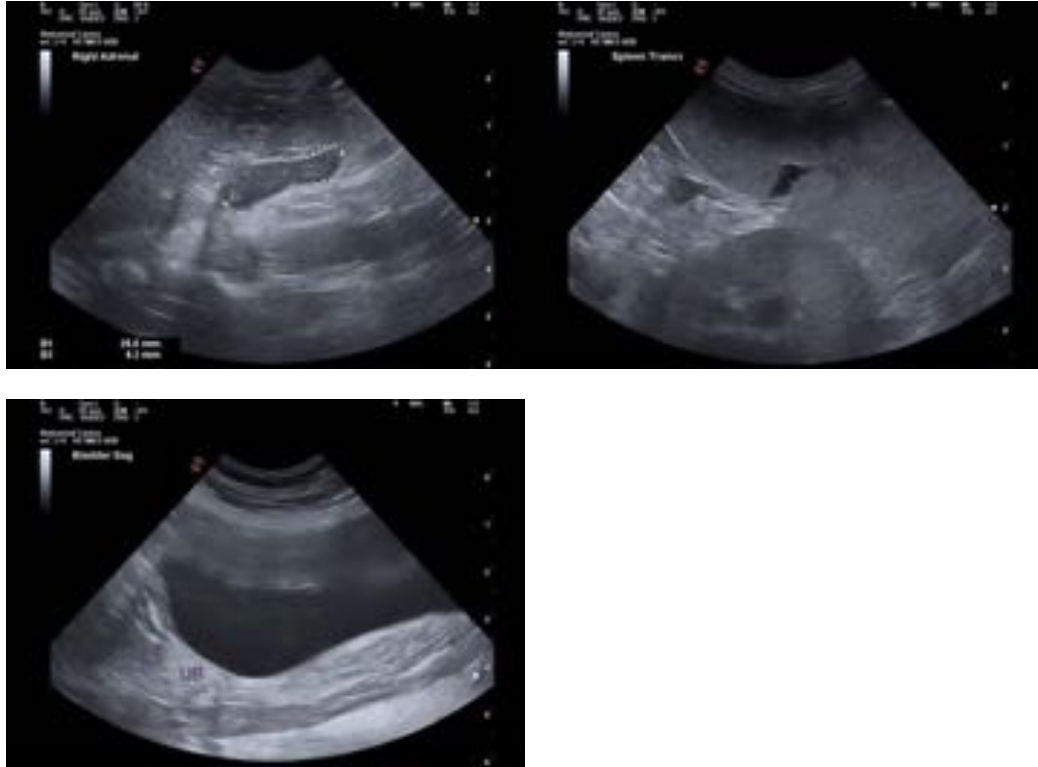- Mild left adrenomegaly
- Minor bilateral age-related renal changes
- The mesenteric lymphadenopathy is most likely reactive, with a lower possibility of emerging neoplasia.
- The splenic parenchymal changes are most consistent with a benign process such as lymphoid hyperplasia, extramedullary hematopoiesis, splenitis or antigenic stimulation with a low possibility of infiltrative neoplasia (i.e., lymphoma, mast cell neoplasia).

## **INTERPRETATION OF THE FINDINGS & FURTHER RECOMMENDATIONS**

- Consider a prophylactic cholecystectomy given the potential risk of gall bladder rupture with subsequent bile/septic peritonitis. If pursued, a liver biopsy should be performed at the time of surgery. If surgery is not pursued at this time, initiation of Ursodiol therapy along with broad-spectrum antibiotics and hepatic antioxidants are recommended, along with close sonographic monitoring (i.e., every 3-4 weeks) of the gall bladder to assess for progression/rupture. Three-view thoracic radiographs and clotting times (i.e., PT/PTT) are recommended prior to anesthesia.

- Consider testing for hyperadrenocorticism with a low-dose dexamethasone suppression test or ACTH stimulation test if clinical signs (i.e., PU/PD) develop in the future.
- Regarding the hematuria, a urine culture and sensitivity is recommended, preferably 5-7 days after the last dose of antibiotics.





The information and recommendations provided are based on the images presented by the referring veterinarian/sonographer. No evaluation can be communicated regarding pathology that was not visible in the image/video clips provided.

Thank you for this referral. If the clinical or image interpretation does not parallel your findings or if I can be of any further assistance, please contact me.

**Andrea Nicastro, MPH, DVM, Diplomate DACVIM (Small Animal Internal Medicine)**  
[info@SonoPath.com](mailto:info@SonoPath.com)