

**DATE PRESENTING CLINICAL SIGNS**

12/15/21

History: Acute abdominal pain, history of pancreatitis. Abdominal mass noted on radiographs.

PATIENT

Lab Results: HCT 33.45%, PLT 118.

Radiographs: abdominal mass.

Date of Previous IntraPet Ultrasound: No previous IntraPet scans.

Bailey Hall

Sedation: Not required for a full diagnostic ultrasound.

Stat Report: requested.

SPECIES

Canine

BREED

Mixed breed

SEX

Female, spayed

AGE

5/29/2010

WEIGHT

85 lbs.

INTERPRETED BY

Andrea Nicastro, DVM,
 Diplomate ACVIM
 (Small Animal Internal
 Medicine)

IMAGING PERFORMED BY

Stephanie Pearce
 RDCS, RVT

HOSPITAL NAME

Warm & Fuzzy VC

REFERRING VET

Dr. Urie

INVOICE

12719

ULTRASONOGRAPHIC EXAMINATION OF THE ABDOMEN**Urinary System**

The urinary bladder, trigone, and pelvic urethra are normal in thickness and the mucosal surface is smooth. The bladder lumen is moderately distended with anechoic urine. No masses, inflammatory changes or calculi are observed. Ureteral papillae and visualized portion of the proximal urethra, visible to a depth of 2 cm, are normal.

The left kidney is normal in size (6.48 cm in length) with a normal shape, smooth peripheral margins and normal internal architecture. There is minimal loss of corticomedullary distinction. Several hyperechoic shadowing diverticular foci are observed. There is no evidence of pyelectasia, infarcts or hydronephrosis. Renal vasculature is normal.

The right kidney is normal in size (7.32 cm in length) with a normal shape, smooth peripheral margins and normal internal architecture. There is minimal loss of corticomedullary distinction. Several hyperechoic shadowing diverticular foci are observed. A 0.49 cm mineralized focus is observed in the cortex at the caudal pole. There is no evidence of pyelectasia, infarcts or hydronephrosis. Renal vasculature is normal.

Adrenal Glands

The left adrenal gland is normal size (0.65 cm at cranial pole) (0.80 cm at caudal pole) (2.61 cm in length); normal shape; homogenous parenchyma. The glandular echogenicity and detail are unremarkable. Capsule, cortex, and medullary definition are normal. The phrenicoabdominal vein and surrounding vasculature are normal.

The right adrenal gland is normal size (0.86 cm at cranial pole) (0.70 cm at caudal pole) (2.02 cm in length); normal shape; homogenous parenchyma. The glandular echogenicity and detail are unremarkable. Capsule, cortex, and medullary definition are normal. The phrenicoabdominal vein and surrounding vasculature are normal.

Spleen

The spleen is enlarged with irregular peripheral contours. A >8 cm irregular heterogeneous cavitated mass is arising from the parenchyma. At least 1-2 additional masses are seen in the remainder of the spleen. Surrounding mesentery is hyperechoic. The splenic vasculature appears normal with no evidence of thrombosis.

Liver

The liver is subjectively normal in size with normal curvilinear peripheral contours. The parenchyma is hypoechoic relative to surrounding omental fat and subtly mottled in appearance. No distinct focal lesions

are observed. Vascular and biliary tracts are of normal volume with no evidence of congestion. The gallbladder is of normal contours and contains some dependent echogenic debris. The wall is normal in thickness. No choleliths are observed. The cystic and common bile ducts are normal.

Gastrointestinal

The stomach and intestine are free of stasis and exhibit normal peristaltic activity. The gastric lumen is mildly to moderately distended with soft shadowing material, ingesta and gas. The gastric wall and pylorus are normal in thickness with a normal layering pattern. The pyloric outflow tract is patent. The small intestinal lumen is segmentally dilated with chyme. The small intestinal wall thickness is normal with a normal layering pattern and appropriate mural detail. Discreet masses are not identified. The colonic wall is normal. No obstructive disease is noted.

Pancreas

The region of the pancreas is isoechoic relative to surrounding omental fat. No obvious parenchymal abnormalities are observed. There is no evidence of regional inflammation or effusion.

Free Abdomen

A small amount of free fluid is present. The mesentery in the cranial abdomen, between the liver lobes and surrounding spleen, is hyperechoic. The abdominal lymph nodes are normal/not visible.

Other

A 1.64 x 0.96 cm echogenic lesion is observed in a vessel just dorsal to the urinary bladder.

A brief echocardiogram reveals no evidence of pericardial effusion or obvious right atrial/auricular mass.

ULTRASONOGRAPHIC FINDINGS

Primary Findings:

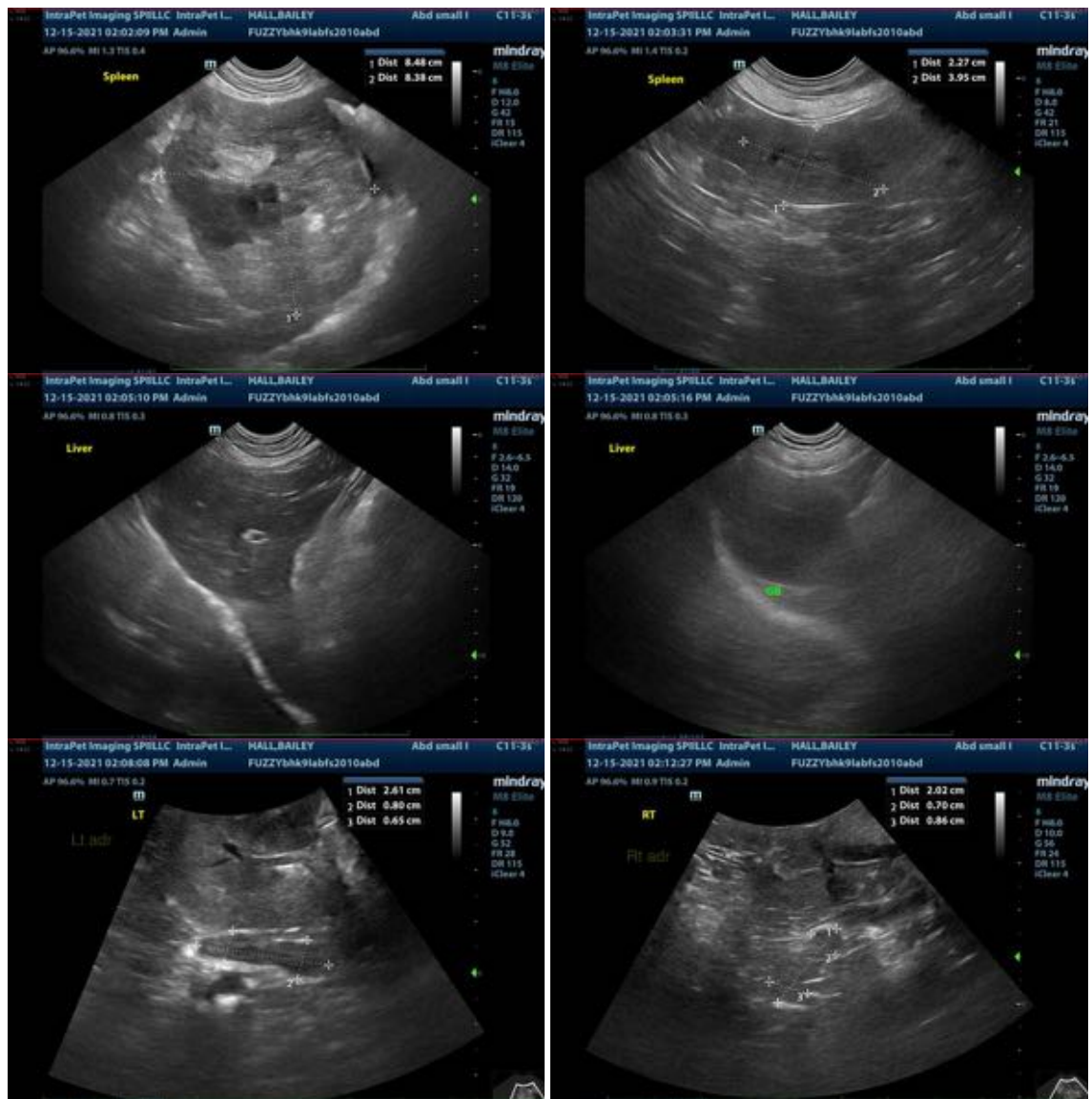- Splenic masses. Neoplasia (i.e., hemangiosarcoma, hemangioma) is considered likely with a lower possibility of benign pathology.
- Cranial abdominal peritonitis is present, likely secondary to the splenic mass.
- The hepatic parenchymal changes are non-specific and are most consistent with age-related pathology. However, micrometastatic disease cannot be completely excluded.
- The echogenic lesion in the vessel dorsal to the urinary bladder may represent a thrombus, artifact, other.

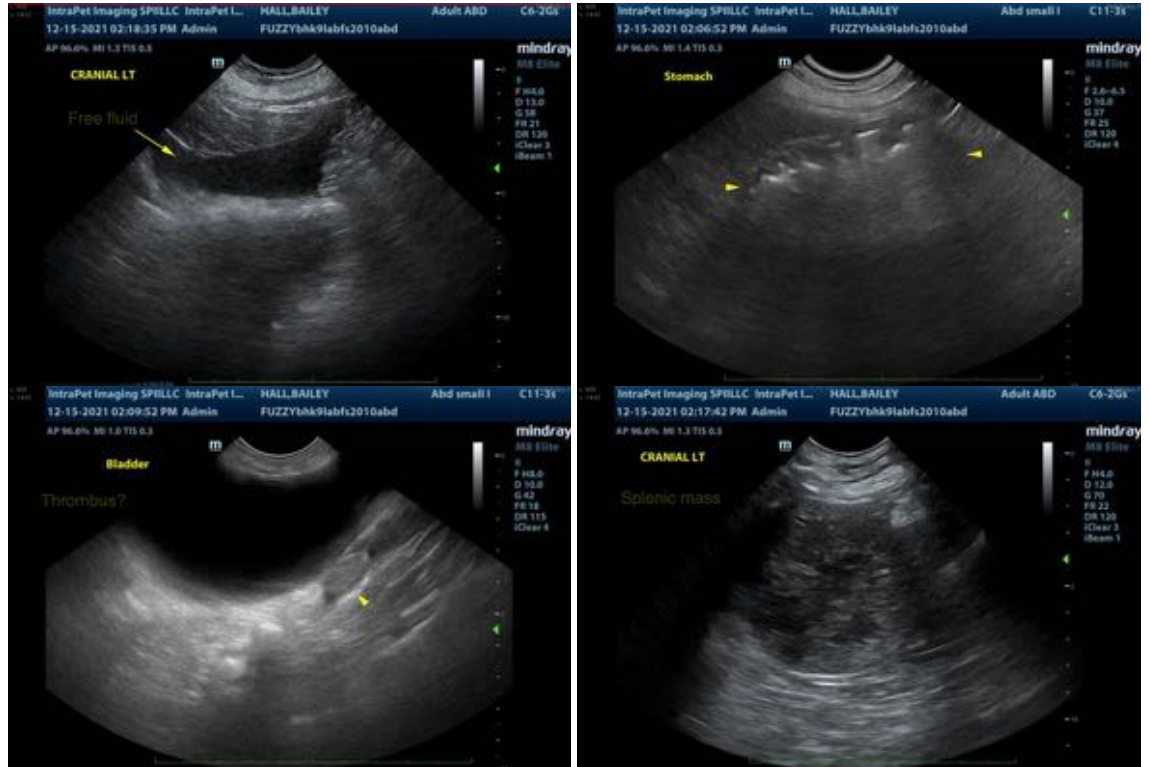
Secondary Findings:

- Gallbladder debris- incidental.
- The gastric contents may represent ingesta and/or foreign material. Correlation with clinical findings is recommended.
- Bilateral minor age-related renal changes with dystrophic mineralization.

INTERPRETATION OF THE FINDINGS & FURTHER RECOMMENDATIONS

- Three-view thoracic radiographs are recommended to assess for pulmonary metastases.
- If there is no evidence of pulmonary metastatic disease a splenectomy with submission for the spleen for histopathology is recommended. A liver biopsy should also be obtained at the time of surgery to assess for micrometastatic disease.
- Consider a recheck ultrasound in 2-3 weeks to reassess caudal abdominal vasculature for the presence of a thrombus.





The information and recommendations provided are based on the images presented by the referring veterinarian. No evaluation can be communicated regarding pathology that was not visible in the image/video clips provided.

Thank you for this referral. If the clinical or image interpretation does not parallel your findings or if I can be of any further assistance please contact me.

Andrea Nicastro, DVM, Diplomate ACVIM (*Small Animal Internal Medicine*)
Andrea.nicastro@sonopath.com