

**DATE**

12/14/21

PRESENTING CLINICAL SIGNS

History: Grade 2/6 HM, Cushing's dz with hx of enlarged adrenal glands, elevated liver enzymes with hx of liver changes on last US, hyperthyroidism, seizures not occurring on phenobarb.

PATIENT

Rachel Ray Antal

Current Medications: Thyrosyn 0.4 mg q24h, Vetoryl 60 mg 1 PO Q24h, Phenobarbital 32.4 mg 1/2 every 12 hours, SamELQ (Denamarin).

Lab Results: Stable Acth on Vetoryl Post 5.6, Stable Thyroid on thyrosyn 3.8, elevated Alt 142, alp 1718, mild elevation in K 5.6, m low Cl 106, low phenobarb levels.

SPECIES

Canine

Date of Previous IntraPet Ultrasound: 10-23-2020.

Sedation: Not required to complete full diagnostic ultrasound.

Stat Report: Not requested.

BREED

Boston

ULTRASONOGRAPHIC EXAMINATION OF THE ABDOMEN**Urinary System**

The urinary bladder, trigone, and pelvic urethra are normal in thickness and the mucosal surface is smooth. The bladder lumen is moderately distended with anechoic urine. No masses, inflammatory changes or calculi are observed. Ureteral papillae and visualized portion of the proximal urethra, visible to a depth of 2 cm, are normal.

AGE

9/26/2007

The left kidney is normal size (5.60 cm in length); normal shape and architecture with smooth peripheral margins. There is a normal 1:3 cortex to medulla ratio with minimal to mild loss of corticomedullary distinction. Moderate pyelectasia is present (0.72 cm in the transverse plane). There is no evidence of nephroliths, infarcts or hydronephrosis. Renal vasculature is normal.

WEIGHT

30 lbs.

The right kidney is normal in size (5.71 cm in length) with a normal shape, smooth peripheral margins and normal internal architecture. There is mild to moderate loss of corticomedullary distinction. Several hyperechoic shadowing diverticular foci are observed. There is no evidence of pyelectasia, infarcts or hydronephrosis. Renal vasculature is normal.

INTERPRETED BY

Andrea Nicastro, DVM,
Diplomate ACVIM
(Small Animal Internal
Medicine)

Adrenal Glands

The left adrenal gland is enlarged (1.06 cm at cranial pole) (0.90 cm at caudal pole) (3.04 cm in length) with a slightly irregular shape. The parenchyma is hypoechoic with some loss of glandular detail. No focal lesions are observed. The phrenicoabdominal vein and surrounding vasculature appear normal.

IMAGING PERFORMED BY

Stephanie Pearce,
RDCS, RVT

The right adrenal gland is enlarged (0.77 cm at cranial pole) (0.84 cm at caudal pole) (2.42 cm in length) with a slightly irregular shape. The parenchyma is hypoechoic with some loss of glandular detail. No focal lesions are observed. The phrenicoabdominal vein and surrounding vasculature appear normal.

HOSPITAL NAME

Aberdeen VC

Spleen

The spleen is normal in size (1.57 cm in width at the level of the hilus) with a normal capsular contour. A 2.84 x 2.76 cm irregularly, hyperechoic nodule/mass is observed within the parenchyma. The lesion causes slight capsular expansion. Several smaller hyperechoic nodules are observed throughout the organ. Splenic vasculature is normal with no evidence of thrombosis.

REFERRING VET

Dr. Fritz

Liver**INVOICE**

12710

The liver is subjectively prominent in size with slightly swollen peripheral contours. The parenchyma is isoechoic relative to the spleen and diffusely heterogeneous in appearance. A 3.72 x 2.18 cm hyperechoic to heterogeneous mass is observed deep mid-liver adjacent to the diaphragm. Vascular and biliary tracts are of normal volume with no evidence of congestion. The gall bladder lumen is moderately distended. The wall is thin and smooth. A small to moderate amount of echogenic debris, some of which is gravity-dependent and some of which is suspended, is observed within the lumen. The cystic and common bile ducts are normal/not seen.

Gastrointestinal

The stomach and intestine are free of stasis and exhibit normal peristaltic activity. The gastric lumen is mildly distended with ingesta. The gastric wall and pylorus are normal in thickness with a normal layering pattern. The pyloric outflow tract is patent. The small intestinal lumen is segmentally dilated with chyme. The small intestinal wall thickness is normal with a normal layering pattern and appropriate mural detail. Discreet masses are not identified. The colonic wall is normal. No obstructive disease is noted.

Pancreas

The left and right limbs of the pancreas are visible with normal curvilinear peripheral contours. The parenchyma is largely isoechoic relative to surrounding omental fat and slightly mottled in appearance. The pancreatic duct is visible but not overtly dilated. There is no evidence of peripancreatic inflammation or effusion.

Free Abdomen

There is no evidence of free fluid. The abdominal lymph nodes are normal/not visible.

ULTRASONOGRAPHIC FINDINGS

Primary Findings:

- The previously observed liver nodule/mass is similar in size to slightly larger compared to the previous sonogram. Differentials include benign pathology (i.e., regenerative nodule) vs neoplasia (i.e., adenoma, adenocarcinoma). The diffuse hepatic parenchymal changes are non-specific and are likely secondary to benign age-related change (i.e., vacuolar hepatopathy, regenerative nodular hyperplasia and/or age-related remodeling).
- The bilateral adrenomegaly is consistent with a previous diagnosis of pituitary-dependent hyperadrenocorticism. Adrenal changes are similar to the previous sonogram.
- The hyperechoic splenic lesions adjacent are most consistent with myelolipomas. Although a neoplastic process within the spleen cannot be excluded, it is considered unlikely in this patient. Changes are similar to the previous sonogram.

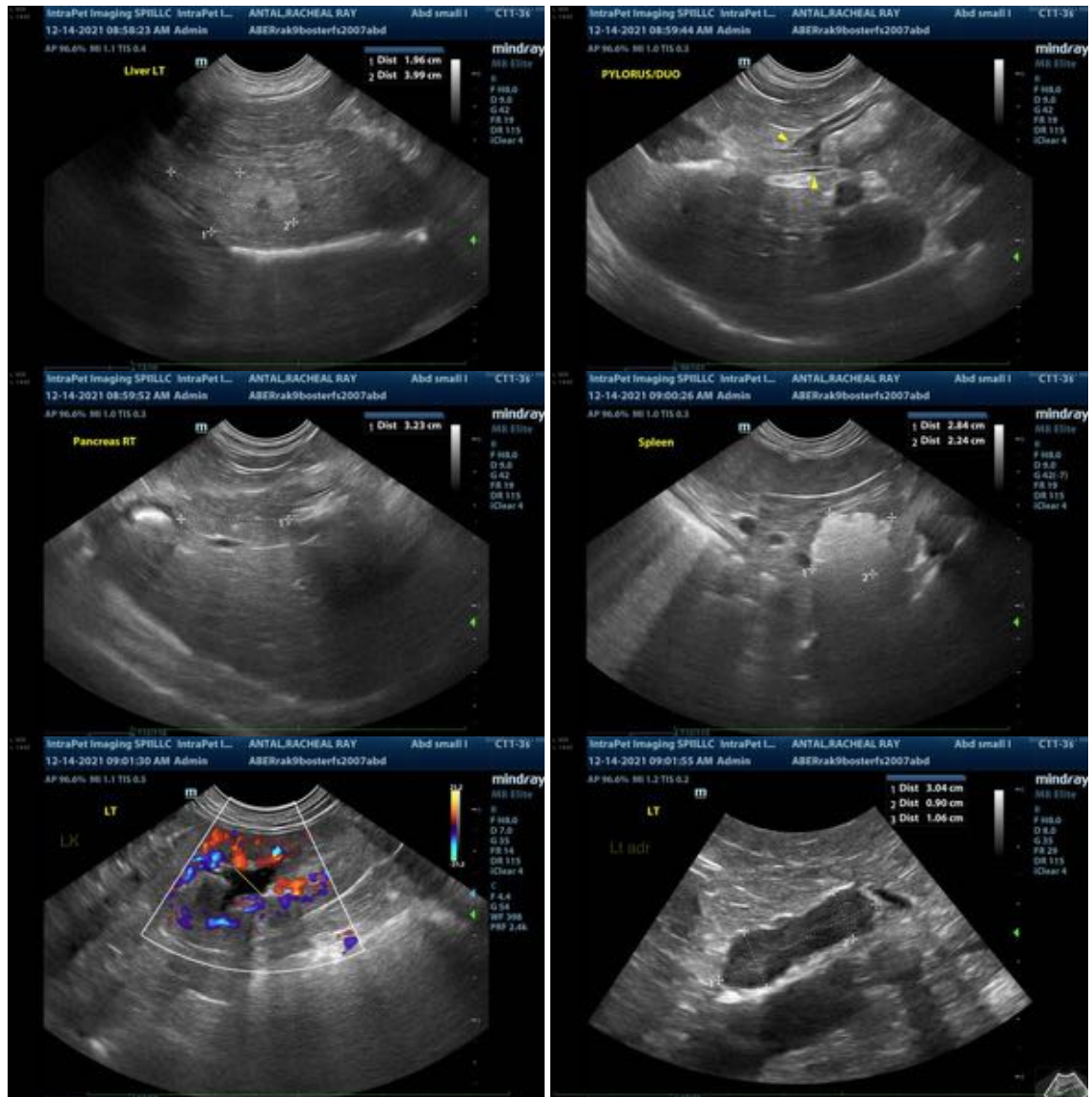
Secondary Findings:

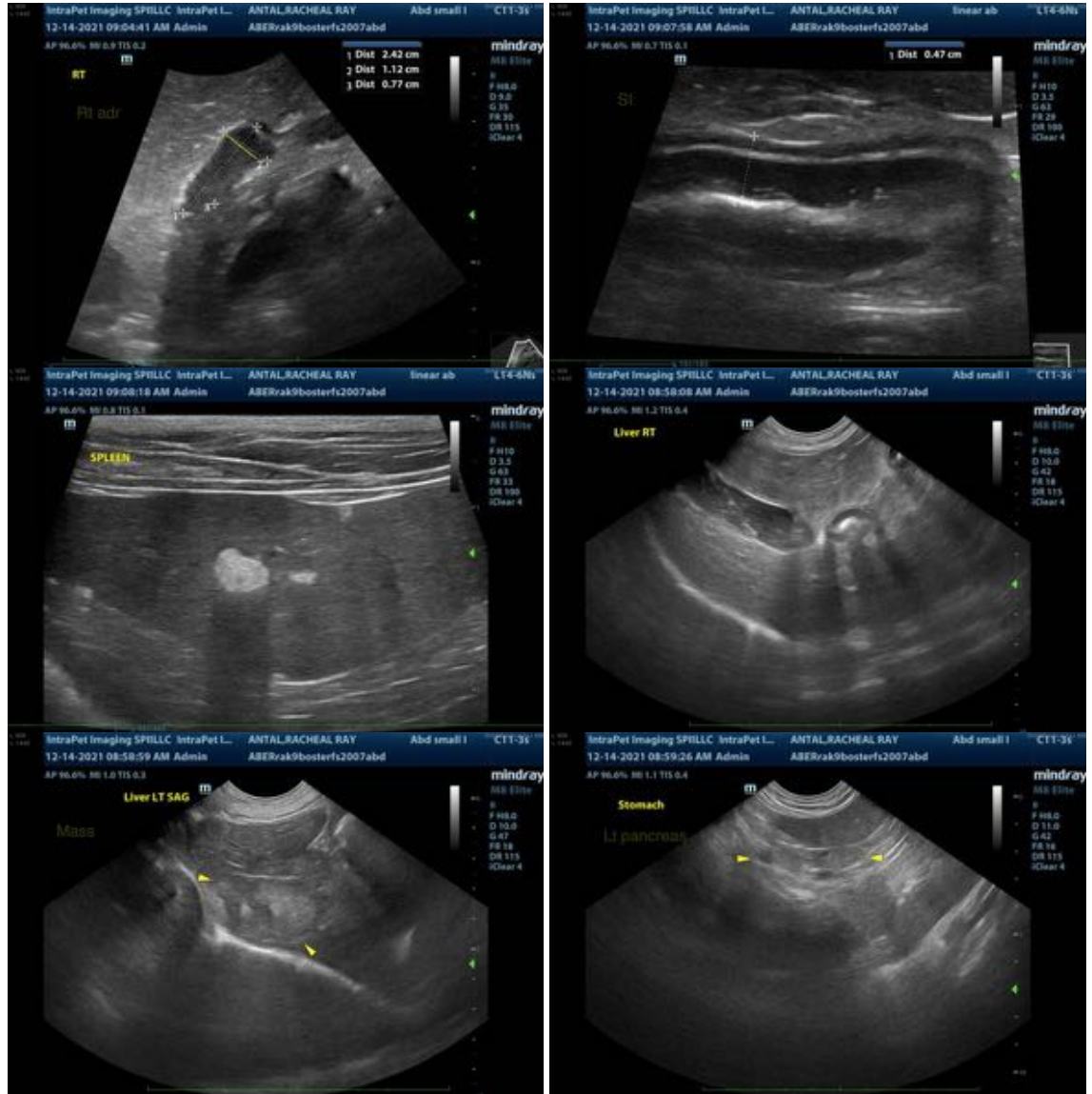- Gallbladder debris, non-mucocele.
- Age-related pancreatic remodeling +/- fibrosis. Changes are similar to the previous sonogram.
- Bilateral age-related renal changes. The left pyelectasia has progressed since the previous

sonogram. Differentials include pyelonephritis, age-related remodeling, PU/PD (if applicable), partial ureteral obstruction, other.

INTERPRETATION OF THE FINDINGS & FURTHER RECOMMENDATIONS

- Given the hepatic nodule/mass, three-view thoracic radiographs are recommended to assess for pulmonary metastatic disease. If accessible, a fine needle aspirate of the hepatic lesion can be considered (if clotting status is appropriate). If an aggressive approach is desired, consider mass removal with submission for histopathology. If a more conservative approach is desired, consider repeat ultrasound in 2-3 months to assess for progression.
- Regarding the left pyelectasia, a urinalysis +/- urine culture and sensitivity should be considered.





The information and recommendations provided are based on the images presented by the referring veterinarian. No evaluation can be communicated regarding pathology that was not visible in the image/video clips provided.

Thank you for this referral. If the clinical or image interpretation does not parallel your findings or if I can be of any further assistance please contact me.

Andrea Nicastro, DVM, Diplomate ACVIM (Small Animal Internal Medicine)
 Andrea.nicastro@sonopath.com