

PATIENT PRESENTING CLINICAL SIGNS

Gedney Monroe
SPECIES Feline
BREED Scottish Fold

History: Presented on 10/11 for vomiting/regurgitation, minor weight loss, decreased appetite. Reported throat clearing very often, non-productive. Blood work showed hypercalcemia 13.1, could not do other diagnostics then, switched to RC HP/urinary (housemate needs urinary diet). Per O housemate showing similar signs but less extend Presented on 11/29 recheck, after 1m of diet change, unable to introduce psyllium husk since P refused to eat it, hypercalcemia resolved. However, P's appetite still went down over the past 1-2 weeks, lost 1.4lb since Oct 11. Vomiting episode decreased to twice monthly, gagging/throat clearing episode reduced significantly as well with new diet.

Abnormal lab-work values: 10/11 - Ca 13.1 11/29 - all normal
Current Medications Gabapentin 100mg as needed for anxiety. RC HP/Urinary diet

SEX Neutered Male
ULTRASONOGRAPHIC EXAMINATION OF THE ABDOMEN

Urinary System

The urinary bladder wall is normal in thickness. The mucosal surface is smooth. The bladder is mildly to moderately distended. A small amount of suspended echogenic debris is observed within the lumen. No cystic calculi are observed. The region of the trigone and the proximal urethra, visible to a depth of 2 cm, are normal.

The left kidney is normal in size (4.15 cm in length) with a normal shape, architecture and smooth peripheral margins. There is a normal 1:3 cortex to medulla ratio with minimal loss of corticomedullary distinction. There is no evidence of pyelectasia, nephroliths, infarcts or hydroureter. Renal vasculature is normal.

The right kidney is normal in size (4.47 cm in length) with a normal shape, architecture and smooth peripheral margins. There is a normal 1:3 cortex to medulla ratio with minimal loss of corticomedullary distinction. There is no evidence of pyelectasia, nephroliths, infarcts or hydroureter. Renal vasculature is normal.

Adrenal Glands

The left adrenal gland is normal size (0.34 cm width) with a normal shape. Hyperechoic foci are observed within the parenchyma. Glandular echogenicity and detail are otherwise normal. The phrenicoabdominal vein and surrounding vasculature are normal.

The region of the right adrenal gland is evaluated. No obvious pathology is observed in this region.

Spleen

The spleen is normal in size (0.63 cm in width at the level of the hilus) with a normal capsular contour. There is appropriate echogenicity and echotexture. No focal lesions are observed. Splenic vasculature is normal.

Liver

The liver is subjectively normal in size with normal contours and structure. There is appropriate echogenicity and echotexture. No overt structural evidence of inflammatory, infiltrative, or regenerative pathology is evident. Vascular and biliary tracts are of normal volume with no evidence of congestion.

The gallbladder lumen is moderately distended. The wall is thin and smooth. A small amount of suspended echogenic debris is observed within the lumen. The cystic and common bile ducts are normal/not seen.

Gastrointestinal

The gastric lumen is minimally distended with ingesta. The gastric wall and pylorus are normal in thickness with a normal layering pattern. The pyloric outflow tract is patent. The small intestinal lumen is not

INTERPRETED BY

Andrea Nicastro DVM
Diplomate ACVIM
(Sm Animal Internal Med)

IMAGING PERFORMED BY

Sara Hansen

HOSPITAL NAME

Dr Johnson

REFERRING VET

The Veterinary Hospital

INVOICE

22248

DATE

12-11-25



PATIENT Gedney Monroe
 dilated. The small intestinal wall is normal in thickness with a normal layering pattern and appropriate mural detail. Discreet masses are not identified. The colonic wall is normal. There is no evidence of an obstructive pattern.

SPECIES *Pancreas*
 Feline
 The region of the pancreas is isoechoic relative to surrounding omental fat. No obvious parenchymal abnormalities are observed. There is no evidence of regional inflammation or effusion.

BREED *Lymph Nodes*
 Scottish Fold
 The abdominal lymph nodes are normal/not visible.

SEX *Free Abdomen*
 Neutered Male
 The peritoneal cavity is normal. There is no evidence of inflammation or effusion.

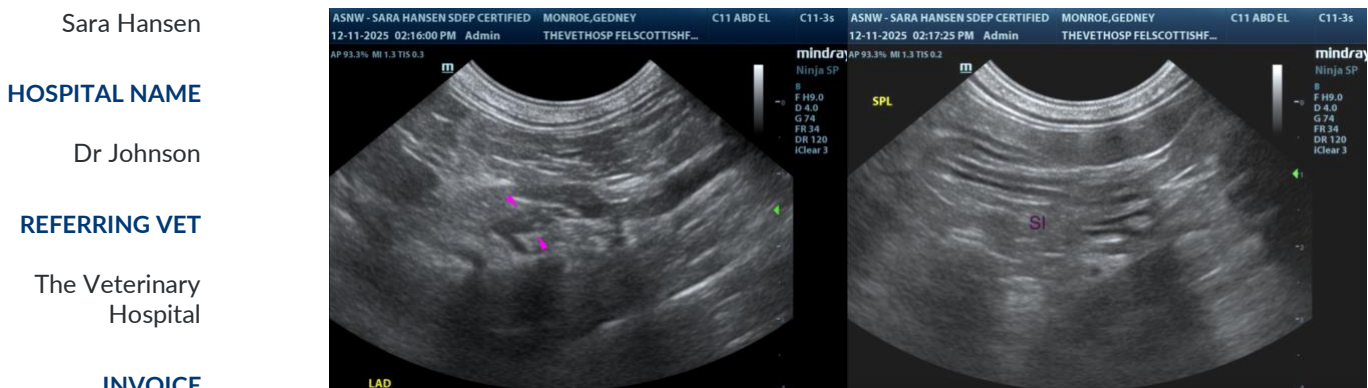
ULTRASONOGRAPHIC FINDINGS

AGE 4
 The mineralized foci with the left adrenal gland parenchyma likely represent a benign incidental finding.

WEIGHT 9 lbs
 *An obvious cause for the patient's clinical signs is not definitively identified in this study. Considerations include a primary enteropathy (i.e., food allergy/intolerance, inflammatory bowel disease, infectious/parasitic disease, esophageal dysfunction), underlying metabolic issue, other.

INTERPRETATION OF THE FINDINGS & FURTHER RECOMMENDATIONS

- INTERPRETED BY** Andrea Nicastro DVM
 Diplomate ACVIM
 (Sm Animal Internal Med)
- A GI panel including serum cobalamin and folate, TLI and PLI, along with a fecal evaluation for ova and Giardia are recommended.
 - Three-view thoracic radiographs are also recommended to assess for occult esophageal disease. If regurgitation is still present, consider a barium esophagram, preferably via fluoroscopy, to assess for esophageal dysfunction.
 - Ultimately, an upper GI endoscopic or surgical with biopsies may be indicated.
- IMAGING PERFORMED BY** Sara Hansen



INVOICE

22248

DATE

12-11-25



PATIENT

Gedney Monroe

SPECIES

Feline

BREED

Scottish Fold

SEX

Neutered Male

AGE

4

WEIGHT

9 lbs

INTERPRETED BY

Andrea Nicastro DVM
 Diplomate ACVIM
 (Sm Animal Internal Med)

IMAGING PERFORMED BY

Sara Hansen

HOSPITAL NAME

Dr Johnson

REFERRING VET

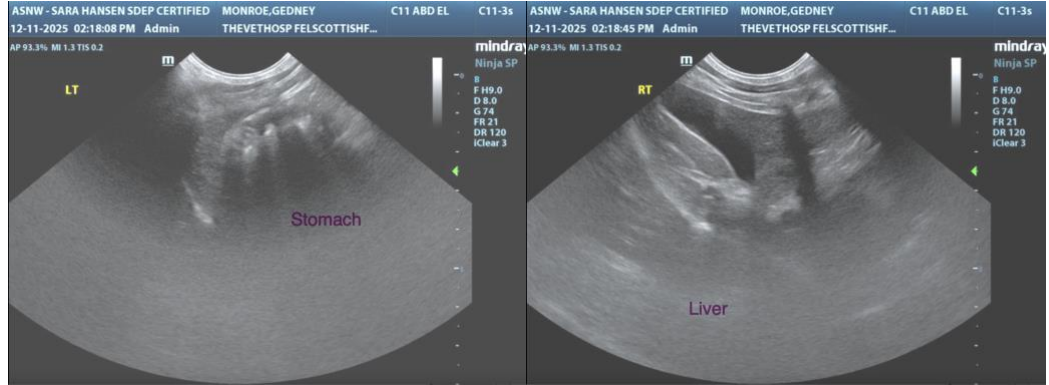
The Veterinary Hospital

INVOICE

22248

DATE

12-11-25



The information and recommendations provided are based on the images presented by the referring veterinarian/sonographer. No evaluation can be communicated regarding pathology that was not visible in the image/video clips provided.

Thank you for this referral. If the clinical or image interpretation does not parallel your findings or if I can be of any further assistance, please contact me.

Andrea Nicastro, MPH, DVM, Diplomate DACVIM (Small Animal Internal Medicine)
info@SonoPath.com