



PATIENT PRESENTING CLINICAL SIGNS

Sunshine Petrucelli History: lethargy anorexia vomiting has vaccines on 11/25. Sibling of Simba.

SPECIES ULTRASONOGRAPHIC EXAMINATION OF THE ABDOMEN

Feline *Urinary System*

The urinary bladder wall is normal in thickness. The mucosal surface is smooth. The bladder is moderately distended. Luminal contents are anechoic. No cystic calculi are observed. The region of the trigone is normal.

BREED

DSH

The left kidney is normal in size (3.10 cm in length) with a normal shape, architecture and smooth peripheral margins. There is a normal 1:3 cortex to medulla ratio with normal corticomedullary distinction. There is no evidence of pyelectasia, nephroliths, infarcts or hydroureter. Renal vasculature is normal.

SEX

Female

The right kidney is normal in size (3.29 cm in length) with a normal shape, architecture and smooth peripheral margins. There is a normal 1:3 cortex to medulla ratio with normal corticomedullary distinction. There is no evidence of pyelectasia, nephroliths, infarcts or hydroureter. Renal vasculature is normal.

AGE

4 mos

Adrenal Glands

The left adrenal gland is normal size (0.33 cm width). Normal shape and glandular echogenicity. The phrenicoabdominal vein and surrounding vasculature are normal.

WEIGHT

4

The region of the right adrenal gland is evaluated. No obvious pathology is observed in this region.

INTERPRETED BY

Andrea Nicastro DVM
Diplomate ACVIM
(Sm Animal Internal Med)

Spleen

The spleen is not definitively visualized in the available images.

Liver

The liver is subjectively normal in size with normal contours and structure. There is appropriate echogenicity and echotexture. No overt structural evidence of inflammatory, infiltrative, or regenerative pathology is evident. Vascular and biliary tracts are of normal volume with no evidence of congestion.

IMAGING PERFORMED BY

Jenn

The gallbladder lumen is moderately distended. The wall is thin and smooth. Luminal contents are anechoic. The cystic and common bile ducts are normal/not seen.

HOSPITAL NAME

Rockaway AH

Gastrointestinal

The gastric lumen is not distended. The gastric wall and pylorus are normal in thickness with a normal layering pattern. The pyloric outflow tract is patent. The small intestinal lumen is not dilated. The small intestinal wall is normal in thickness with a normal layering pattern and appropriate mural detail. Discreet masses are not identified. The ileoceocolic junction and colonic wall are normal. The colonic lumen contains liquid-appearing fecal material. There is no obvious evidence of an obstructive pattern.

REFERRING VET

Dr Maniar

Pancreas

The region of the pancreas is isoechoic relative to surrounding omental fat. No obvious parenchymal abnormalities are observed. There is no evidence of regional inflammation or effusion.

INVOICE

22208

DATE

12-1-25

Lymph Nodes

A few prominent mesenteric lymph nodes are visualized (one measuring 2.10 x 0.45 cm).

Free Abdomen



PATIENT There is no obvious evidence of free fluid.

Sunshine Petrucelli

ULTRASONOGRAPHIC FINDINGS

SPECIES

- The abdominal lymphadenopathy could be consistent with immunologic immaturity, reactive lymphadenitis or lymphoid hyperplasia. Infiltrative neoplasia is possible but considered unlikely.

Feline

- Diarrhetic stool

BREED

DSH

*An obvious cause for the patient's clinical signs is not definitively identified in this study. Considerations include a primary enteropathy (i.e., infectious/parasitic disease, dietary indiscretion, toxicity, food allergy/intolerance, inflammatory bowel disease), underlying metabolic issue (i.e., recent vaccination, other).

SEX

Female

INTERPRETATION OF THE FINDINGS & FURTHER RECOMMENDATIONS
Symptomatic care is recommended. If clinical signs persist despite medical management, a more comprehensive GI work-up (i.e., fecal evaluation for ova and Giardia, GI panel including serum cobalamin and folate, TLI and PLI, three-view thoracic radiographs, +/- endoscopic or surgical GI biopsies) may be indicated.

AGE

4 mos

WEIGHT

4

INTERPRETED BY

Andrea Nicastro DVM
Diplomate ACVIM
(Sm Animal Internal Med)

IMAGING PERFORMED BY

Jenn

HOSPITAL NAME

Rockaway AH

REFERRING VET

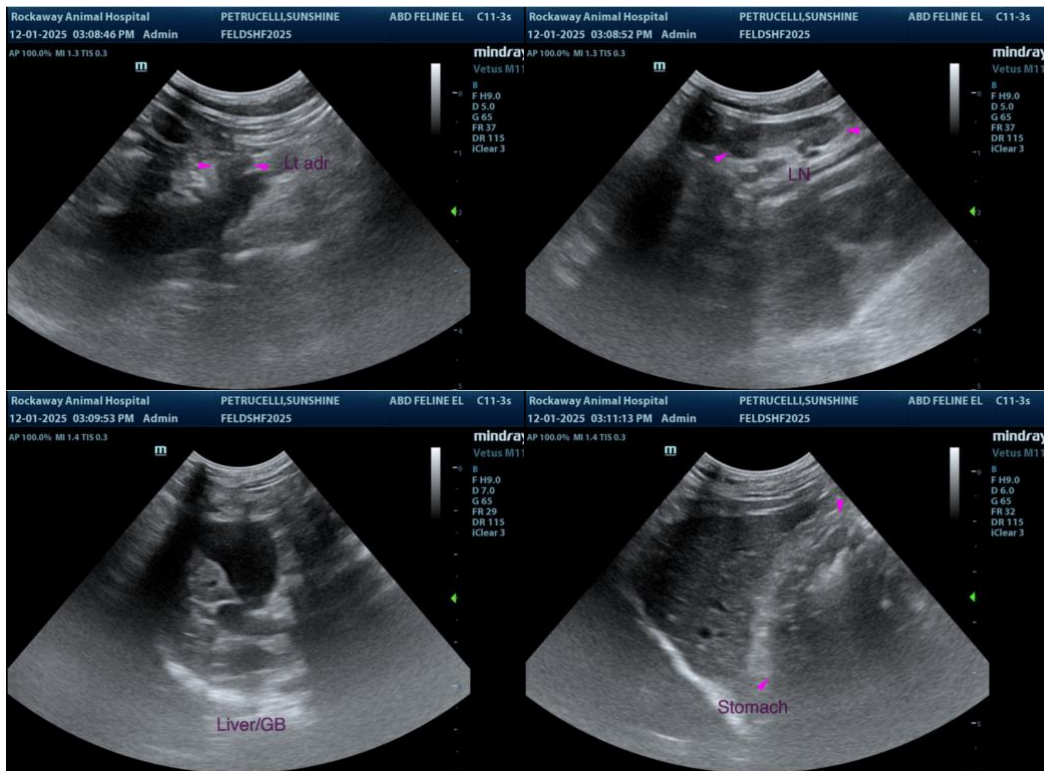
Dr Maniar

INVOICE

22208

DATE

12-1-25





PATIENT

Sunshine Petrucelli

SPECIES

Feline

BREED

DSH

SEX

Female

AGE

4 mos

WEIGHT

4

INTERPRETED BY

Andrea Nicastro DVM
Diplomate ACVIM
(Sm Animal Internal Med)

IMAGING PERFORMED BY

Jenn

HOSPITAL NAME

Rockaway AH

REFERRING VET

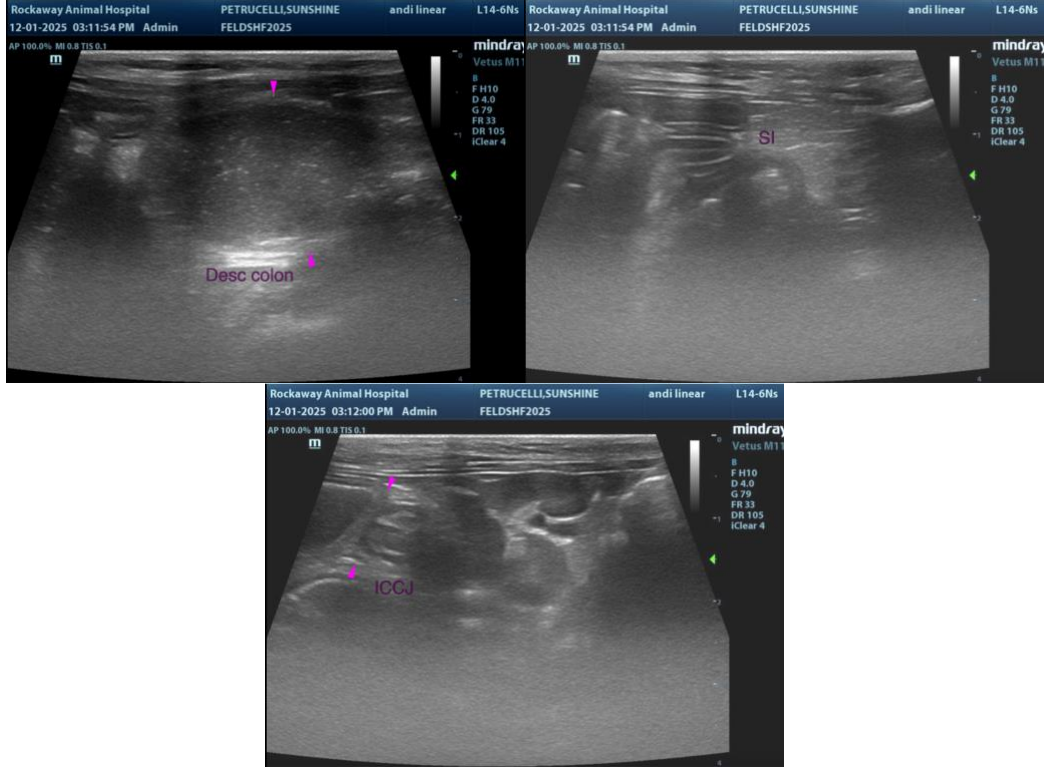
Dr Maniar

INVOICE

22208

DATE

12-1-25



The information and recommendations provided are based on the images presented by the referring veterinarian/sonographer. No evaluation can be communicated regarding pathology that was not visible in the image/video clips provided.

Thank you for this referral. If the clinical or image interpretation does not parallel your findings or if I can be of any further assistance, please contact me.

Andrea Nicastro, MPH, DVM, Diplomate DACVIM (Small Animal Internal Medicine)
info@SonoPath.com