



PATIENT PRESENTING CLINICAL SIGNS

Oliver McKinley Abnormal PE/Chem/CBC/UA Results: ALP 63. Hematocrit 27% nonregenerative. White count 2.9 with a neutropenia. USG 1.051. 2+ proteinuria. Inactive Sediment.

SPECIES
Feline Weight loss, anemia and variable appetite does not appear to relate to previous dental issue, concern for organomegally and possible IBD, X-rays Lateral and VD Body - wispy pulmonary opacity right dorsal lungs, air/gas in stomach, hepatomegaly and splenomegaly.

BREED ULTRASONOGRAPHIC EXAMINATION OF THE ABDOMEN

DSH

Urinary System

The urinary bladder, trigone, and pelvic urethra are normal in thickness and the mucosal surface is smooth. The bladder lumen is moderately distended. A small amount of suspended, echogenic debris is observed within the lumen. No masses, inflammatory changes or calculi are observed. The region of the trigone is normal.

SEX

Neutered Male

AGE

12 years

The left kidney is normal size (4.20 cm in length); normal shape and architecture with smooth peripheral margins. There is a normal 1:3 cortex to medulla ratio with minimal loss of corticomedullary distinction. There is no evidence of pyelectasia, nephroliths, infarcts or hydroureter

WEIGHT

8 lbs

The right kidney is normal size (4.33 cm in length); normal shape and architecture with smooth peripheral margins. There is a normal 1:3 cortex to medulla ratio with minimal loss of corticomedullary distinction. There is no evidence of pyelectasia, nephroliths, infarcts or hydroureter

Adrenal Glands

The region of the left adrenal gland is evaluated. No obvious pathology is observed.

INTERPRETED BY

Andrea Nicastro,
DVM, Diplomate
ACVIM (Small Animal
Internal Medicine)

The right adrenal gland is normal size (0.40 cm width). Normal shape and glandular echogenicity. The phrenicoabdominal vein and surrounding vasculature are normal.

Spleen

The spleen is enlarged (0.70 cm in width at the level of the hilus) with swollen peripheral contours. The parenchyma is of appropriate echogenicity and echotexture. No focal lesions are observed. Splenic vasculature appears normal with no evidence of thrombosis.

IMAGING PERFORMED BY

Amy Mayhew LVT

Liver

The liver is subjectively prominent in size with normal curvilinear peripheral contours. The parenchyma is hypoechoic relative to the spleen and homogenous in appearance. A 1.34 x 0.87 cm hyperechoic to heterogenous multiseptated cystic nodule is observed in the caudate process. Hepatic vasculature and intrahepatic biliary tracts are of normal volume with no evidence of congestion.

HOSPITAL NAME

SVS Imaging Michigan

The gall bladder is distended. The wall is normal in thickness. A bilobed conformation is suspected. A small amount of echogenic debris is suspended within the lumen. A 0.31 cm choledocolith is observed in the cystic/proximal common bile duct. In this region, the common bile duct is borderline dilated (0.41 cm in diameter). Distal to this region, the common bile duct is normal in diameter.

REFERRING VET

Oxford VH

Gastrointestinal

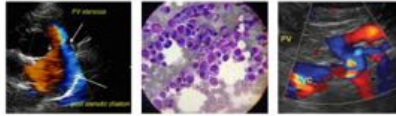
The stomach and intestine are free of stasis and exhibit normal peristaltic activity. The gastric lumen is minimally fluid-distended. The gastric wall and pylorus are normal in thickness with a normal layering pattern. The pyloric outflow tract is patent. The small intestinal lumen is not dilated. The small intestinal wall thickness is normal with a normal layering pattern and appropriate mural detail. Discreet masses are not identified. The ileocecolic junction and colonic wall are normal. There is no evidence of an obstructive pattern.

INVOICE

11990

DATE

11.9.22



PATIENT

Oliver McKinley

Pancreas

The base and limbs of the pancreas are visible with normal curvilinear peripheral contours. The parenchyma is largely isoechoic relative to surrounding omental fat and slightly mottled in appearance. The pancreatic duct is visible but not overtly dilated. There is no evidence of peripancreatic inflammation or effusion.

SPECIES

Feline

Free Abdomen

Trace free fluid is observed. Numerous enlarged (up to 2.60 cm) rounded, hypoechoic lymph nodes are observed adjacent to ileocecolic junction and at the mesenteric root. Surrounding mesentery is hyperechoic.

BREED

DSH

ULTRASONOGRAPHIC FINDINGS

Primary Findings

SEX
Neutered Male

- The splenomegaly and abdomen lymphadenopathy are concerning for infiltrative neoplasia. Lymphoma is the top differential. However, a benign process (i.e., lymphoid hyperplasia or an inflammatory process) cannot be completely excluded.

AGE

12 years

- The mild hepatomegaly may be a normal variant for this patient or may be secondary to emerging neoplasia, inflammatory disease, or other hepatopathy. The right cystic hepatic nodule is consistent with a biliary cystadenoma with a lower possibility of cystadenocarcinoma.

WEIGHT

8 lbs

- Choledocolith, partially obstructive
- Suspected bilobed gall bladder – incidental
- The trace ascites is likely secondary to splenic and lymph node pathology.

INTERPRETED BY

Andrea Nicastro,
DVM, Diplomate
ACVIM (Small Animal
Internal Medicine)

Secondary Findings

- The pancreatic changes are most consistent with age-related parenchymal remodeling, potentially secondary to a prior inflammatory episode, early fibrosis or chronic pancreatitis.

IMAGING PERFORMED BY

Amy Mayhew LVT

INTERPRETATION OF THE FINDINGS & FURTHER RECOMMENDATIONS

- Fine-needle aspirates of the spleen and large abdominal lymph nodes +/- liver, are recommended if clotting status is appropriate. If cytology results are inconclusive, more advanced testing (i.e., flow cytometry, PARR, or biopsies) may be necessary to get a definitive diagnosis.

HOSPITAL NAME

SVS Imaging Michigan

REFERRING VET

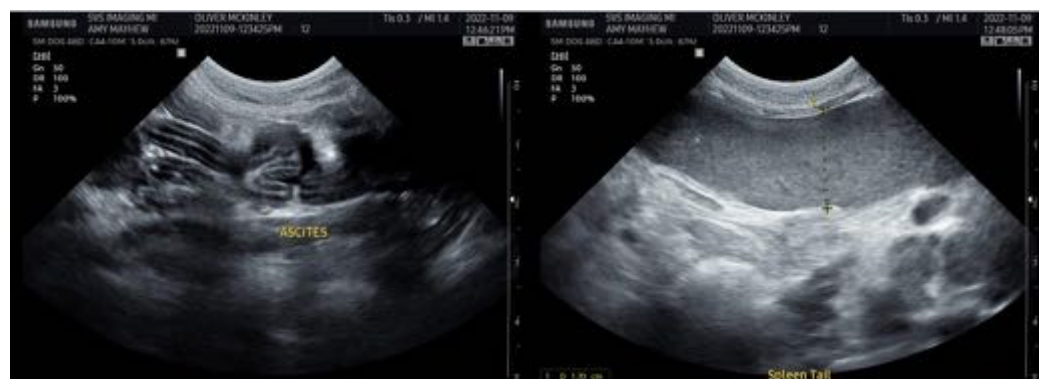Oxford VH

INVOICE

11990

DATE

11.9.22





PATIENT

Oliver McKinley

SPECIES

Feline

BREED

DSH

SEX

Neutered Male

AGE

12 years

WEIGHT

8 lbs

INTERPRETED BY

Andrea Nicastro,
DVM, Diplomate
ACVIM (Small Animal
Internal Medicine)

**IMAGING
PERFORMED BY**

Amy Mayhew LVT

HOSPITAL NAME

SVS Imaging Michigan

REFERRING VET

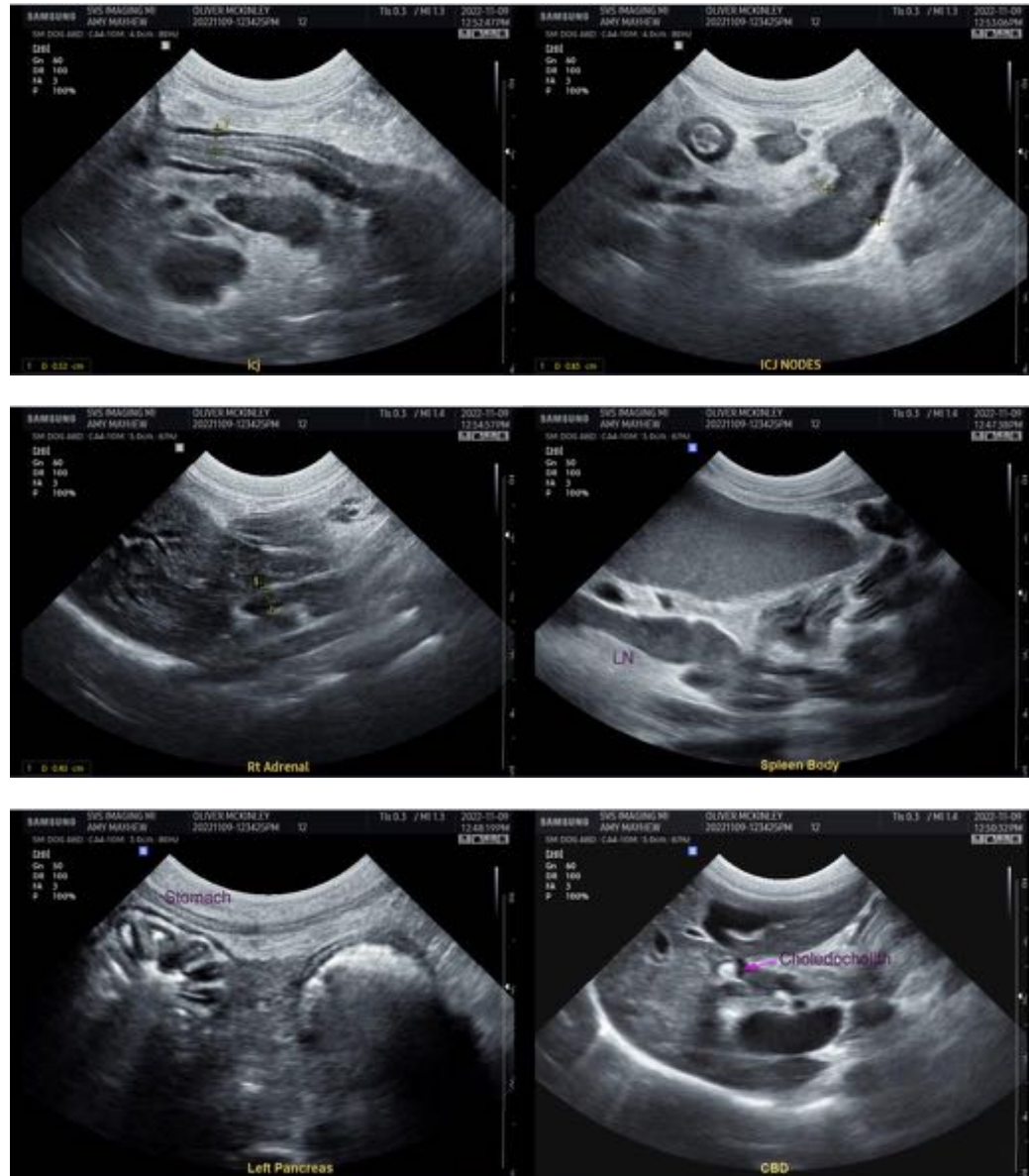
Oxford VH

INVOICE

11990

DATE

11.9.22



The information and recommendations provided are based on the images presented by the referring veterinarian/sonographer. No evaluation can be communicated regarding pathology that was not visible in the image/video clips provided.

Thank you for this referral. If the clinical or image interpretation does not parallel your findings or if I can be of any further assistance, please contact me.

Andrea Nicastro, MPH, DVM, Diplomate DACVIM (Small Animal Internal Medicine)
info@SonoPath.com