



PATIENT PRESENTING CLINICAL SIGNS

Patient: Benzo Nag
Species: Canine
Breed: Lab
Sex: Male, intact
Age: 10 Yrs.
Weight: 68 lbs.

History: Current Medications: Dasuquin Advanced once daily Trazodone premedication for examinations Deracoxib 50 mg SID - owner instructed to discontinue until other cause of vomiting is established Patient History: Owner reports once night of excessive drooling about two weeks ago. Last Thursday and Friday had episodes of vomiting bile and phlegm. No change in appetite of stool.
Abnormal PE/Chem/CBC/UA Results: Mild dental calculus and gingivitis. CBC chem/T4 WNL. USG 1.027 with 2+ proteinuria. Suspected bacteriuria. 4DX negative.

ULTRASONOGRAPHIC EXAMINATION OF THE ABDOMEN

Urinary System

The urinary bladder is mildly to moderately distended. The wall is of appropriate thickness for the level of repletion. The mucosal surface in the region of the apex is slightly irregular. No cystic calculi are observed. The region and the proximal urethra, visible to a depth of 2-3 cm, are normal.

The prostate is enlarged (4.07 cm width) with smooth curvilinear peripheral contours. The parenchyma is hyperechoic relative to surrounding omental fat and slightly heterogeneous in appearance. No distinct focal lesions are observed. The prostatic urethra is not overtly dilated.

The left kidney is normal size (6.79 cm in length); normal shape and architecture with smooth peripheral margins. There is a normal 1:3 cortex to medulla ratio with moderate loss of corticomedullary distinction. There is no evidence of pyelectasia, nephroliths, infarcts or hydroureter.

The right kidney is normal size (6.38 cm in length); normal shape and architecture with smooth peripheral margins. There is a normal 1:3 cortex to medulla ratio with mild loss of corticomedullary distinction. There is no evidence of pyelectasia, nephroliths, infarcts or hydroureter.

Adrenal Glands

The left adrenal gland is normal size (0.66 cm at cranial pole) (0.61 cm at caudal pole); normal shape; homogenous parenchyma. The glandular echogenicity and detail are unremarkable. Capsule, cortex, and medullary definition are normal. The phrenicoabdominal vein and surrounding vasculature are normal.

The right adrenal gland is enlarged (at the caudal pole) (0.63 cm at cranial pole) (1.05 cm at caudal pole) with an irregular shape. A 1.48 x 0.93 cm hyperechoic to slightly heterogeneous nodule is observed at the caudal aspect. The lesion causes slight capsular expansion. The glandular echogenicity and detail at the cranial aspect are unremarkable. The phrenicoabdominal vein and surrounding vasculature are normal.

Spleen

The spleen is normal in size (1.89 cm in width at the level of the hilus) with a normal capsular contour. The parenchyma is subtly mottled in appearance. No focal lesions are observed. Splenic vasculature is normal.

Liver

The liver is subjectively normal in size with normal contours and structure. There is appropriate echogenicity and echotexture. No overt structural evidence of inflammatory, infiltrative or regenerative pathology is evident. Vascular and biliary tracts are of normal volume with no evidence of

INTERPRETED BY

Andrea Nicastro, DVM,
Diplomate ACVIM
(Small Animal Internal
Medicine)

IMAGING PERFORMED BY

Amy Mayhew

HOSPITAL NAME

SVS Imaging Michigan

REFERRING VET

Wixom Family Pet
Practice

INVOICE

14193

DATE

11/8/22



PATIENT

Benzo Nag

congestion. No pathological hepatic lymphadenopathy observed. The gall bladder lumen is moderately distended. The wall is thin and smooth. Luminal contents are anechoic. The cystic and common bile ducts are normal/not seen.

SPECIES

Canine

Gastrointestinal

The stomach and intestine are free of stasis and exhibit normal peristaltic activity. The gastric lumen is mildly gas distended. The gastric wall and pylorus are normal in thickness with a normal layering pattern. The pyloric outflow tract is patent. The small intestinal lumen is not dilated. The small intestinal wall thickness is normal with a normal layering pattern and appropriate mural detail. Discreet masses are not identified. The colonic wall is normal. No obstructive disease is noted.

BREED

Lab

Pancreas

SEX

Male, intact

The region of the pancreas is isoechoic relative to surrounding omental fat. No obvious parenchymal abnormalities are observed. There is no evidence of regional inflammation or effusion.

AGE

10 Yrs.

Free Abdomen

The peritoneal cavity is normal. There is no evidence of inflammation or effusion. The abdominal lymph nodes are normal/not visible.

WEIGHT

68 lbs.

ULTRASONOGRAPHIC FINDINGS

Primary Findings:

- An obvious cause for the patient's clinical signs is not identified in this study. Considerations include food allergy/intolerance, infectious/parasitic disease, inflammatory bowel disease, esophageal disease, underlying metabolic issue, other.

Secondary Findings:

- Bilateral, chronic age-related renal changes.
- The right adrenal nodule trends toward the benign (i.e., nodular hyperplasia). However, an emerging tumor cannot be completely excluded.
- The splenic parenchymal changes trend toward the benign (i.e., lymphoid hyperplasia, extramedullary hematopoiesis or similar with a lower possibility of emerging neoplasia).
- The prostate changes are most consistent with benign prostatic hyperplasia. However, given the presence of bacteriuria, bacterial prostatitis is possible.

INTERPRETED BY

Andrea Nicastro, DVM,
Diplomate ACVIM
(Small Animal Internal
Medicine)

IMAGING PERFORMED BY

Amy Mayhew

HOSPITAL NAME

SVS Imaging Michigan

INTERPRETATION OF THE FINDINGS & FURTHER RECOMMENDATIONS

- Three-view thoracic radiographs are recommended to assess for occult esophageal disease.
- A fecal evaluation for ova/Giardia.
- Consider a 6 week hydrolyzed protein or limited antigen diet trial.
- Also consider a malabsorption panel including serum cobalamin, folate, TLI and PLI to further assess for maldigestion/malabsorption and underlying pancreatic disease.

REFERRING VET

Wixom Family Pet
Practice

INVOICE

14193

DATE

11/8/22



PATIENT

Benzo Nag

SPECIES

Canine

BREED

Lab

SEX

Male, intact

AGE

10 Yrs.

WEIGHT

68 lbs.

INTERPRETED BY

Andrea Nicastro, DVM,
Diplomate ACVIM
(Small Animal Internal
Medicine)

IMAGING PERFORMED BY

Amy Mayhew

HOSPITAL NAME

SVS Imaging Michigan

REFERRING VET

Wixom Family Pet
Practice

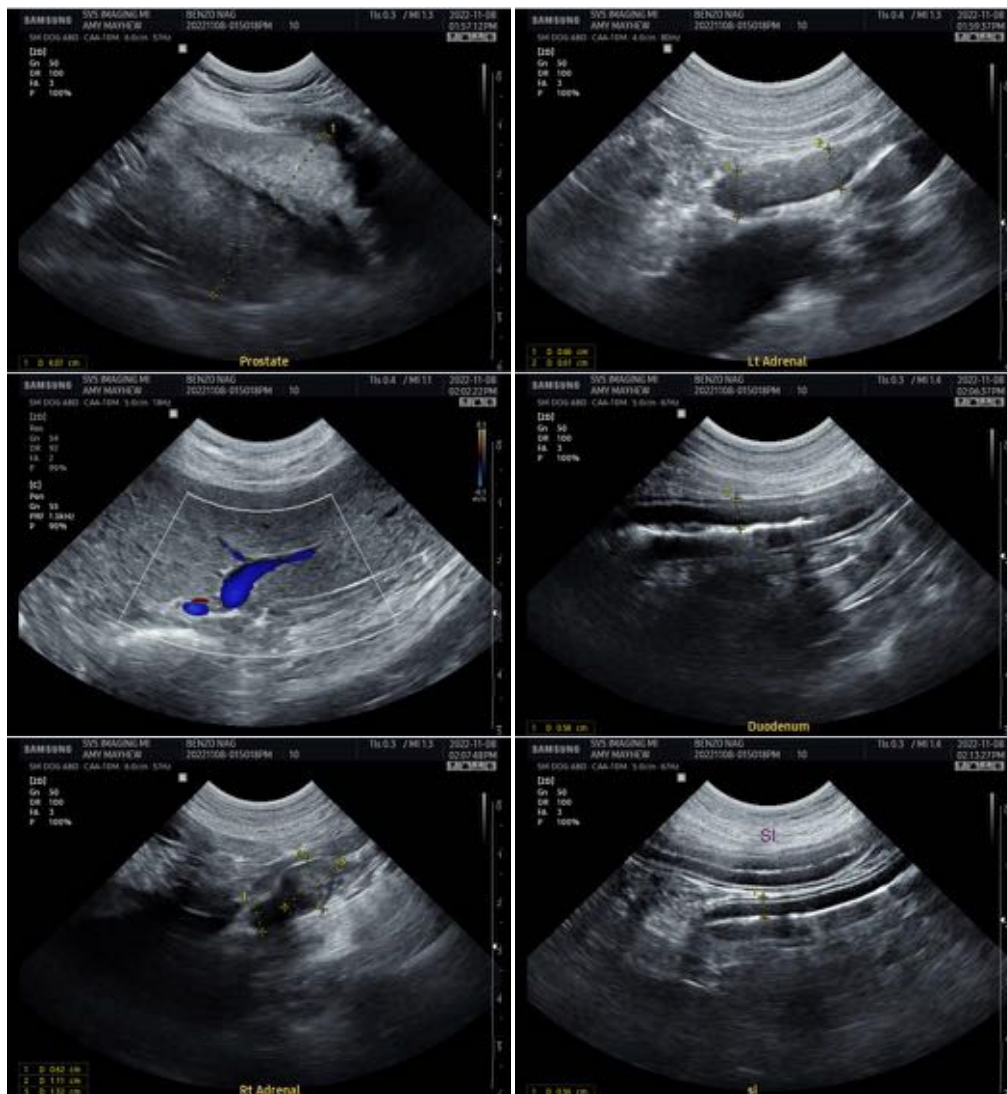
INVOICE

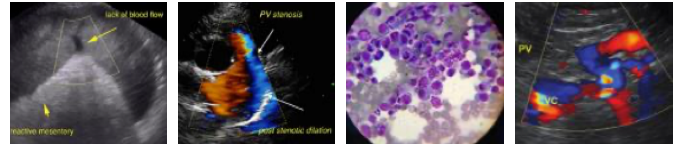
14193

DATE

11/8/22

- A probiotic may prove beneficial.
- A resting cortisol level can be considered to screen for hypoadrenocorticism. However, given the right adrenal changes, this disease is considered less likely.
- Ultimately, GI biopsies may be warranted. An upper GI endoscopy is preferable in this scenario to assess for gastric ulcerations, esophagitis, etc.
- Given the presence of bacteriuria, a urine culture and sensitivity is recommended. While awaiting culture results, consider initiation of a broad spectrum antibiotic (i.e., fluoroquinolone). Castration is also strongly recommended.





PATIENT

Benzo Nag

SPECIES

Canine

BREED

Lab

SEX

Male, intact

AGE

10 Yrs.

WEIGHT

68 lbs.

INTERPRETED BY

Andrea Nicastro, DVM,
Diplomate ACVIM
(*Small Animal Internal
Medicine*)

**IMAGING
PERFORMED BY**

Amy Mayhew

HOSPITAL NAME

SVS Imaging Michigan

REFERRING VET

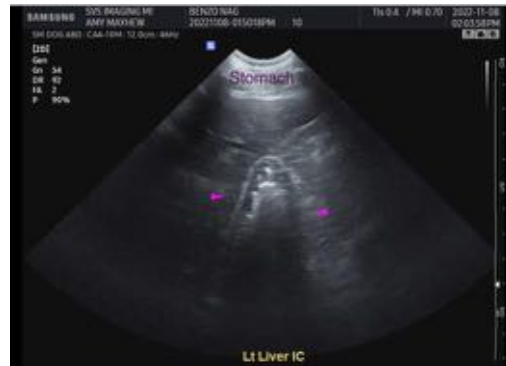Wixom Family Pet
Practice

INVOICE

14193

DATE

11/8/22



The information and recommendations provided are based on the images presented by the referring veterinarian/sonographer. No evaluation can be communicated regarding pathology that was not visible in the image/video clips provided.

Thank you for this referral. If the clinical or image interpretation does not parallel your findings or if I can be of any further assistance please contact me.

Andrea Nicastro, MPH, DVM, Diplomate DACVIM (Small Animal Internal Medicine)
info@SonoPath.com