

PATIENT PRESENTING CLINICAL SIGNS

Lillie Tamerian
SPECIES Canine
BREED Shih Tzu
SEX Female, spayed
AGE 14 Yrs. 10 mo.
WEIGHT 8.3 lbs.

History: P has hx of inc ALP levels. P has been treated for ulcerated ear mass w sec Pseudomonas infection AS. Currently otitis under control w Posatex 3x weekly. P also has hx of organomegaly. Other current meds: Ursodiol started Jan 2020, Denamarin started Feb 2020, Posatex started in Aug 2021, Gabapentin started Aug 2021, Clindamycin 10/29/21, Pred, Omeprazole, Sucralfate started 11/3/2021, Drontal dispensed on same day, added Enrofloxacin on 11/5/2021.

Abnormal PE/Chem/CBC/UA Results: 10/29: CBC: Hct: 19L, spherocytes, polychromasia noted w poikilositosis and slight acanthocytes, moderate anisocytosis w slight rouleaux. thrombocytosis (766HH), Retic ct: 4.5H; Chem: ALT: 144H, ALP: 672H, creat: 1.1, K: 6.3H T4: L, UA: free-catch; SG: 1.018, trace protein, bacteruria, quiet sediment otherwise. Clindamycin started on 10/29 for poss tooth root abscess UA repeated by cysto after 5 days on clindamycin and bacteruria was repeatable, C/S pending, added enrofloxacin to tx Pred started at 1mg/kg while results pending due to presence of spherocytes. Rectal exam was normal, no melena noted, although o reports occasional darker stools (not black). 3/21, bw performed at another AH: ALP: 2065, ALT: 65, no CBC performed 5/1/2020: AUS, by us and interpreted by Sonopath: PLEASE REFERENCE 4/20, same AH: CBC: Hct: 39.9, Chem: ALP 3815, choles: 370H, UA: 1.029, quiet sediment

ULTRASONOGRAPHIC EXAMINATION OF THE ABDOMEN

Urinary System

The urinary bladder is minimally distended with anechoic urine. The wall is thickened (up to 1.05 cm) and irregular, particularly in the region of the apex. No cystic calculi are observed. The region of the trigone is normal.

The left kidney is normal size (3.83 cm in length); normal shape and architecture with smooth peripheral margins. There is a normal 1:3 cortex to medulla ratio with minimal to mild loss of corticomedullary distinction. Trace pyelectasia is present. Tiny nephroliths are visualized. At least 1-2 small cortical cysts are observed. There is no evidence of infarcts or hydroureter.

The right kidney is normal size (2.69 cm in length); normal shape and architecture with smooth peripheral margins. There is a normal 1:3 cortex to medulla ratio with minimal to mild loss of corticomedullary distinction. A few nephroliths are visualized. There is no evidence of pyelectasia, infarcts or hydroureter.

Adrenal Glands

The left adrenal gland is normal size (0.53 cm at cranial pole) (0.40 cm at caudal pole) (1.42 cm in length); normal shape; homogenous parenchyma. The glandular echogenicity and detail are unremarkable. Capsule, cortex, and medullary definition are normal. The phrenicoabdominal vein and surrounding vasculature are normal.

The right adrenal gland is normal size (0.63 cm at cranial pole) (0.49 cm at caudal pole) (1.62 cm in length); normal shape; homogenous parenchyma. The glandular echogenicity and detail are unremarkable. Capsule, cortex, and medullary definition are normal. The phrenicoabdominal vein and surrounding vasculature are normal.

Spleen

The spleen is subjectively enlarged (1.88 cm in width at the level of the hilus) with an irregular undulating medial contour. The parenchyma is diffusely mottled, bordering on a “moth-eaten” appearance. Pinpoint hyperechoic foci are seen throughout the organ. Splenic vasculature appears normal with no evidence of thrombosis.

INTERPRETED BY

Andrea Nicastro, DVM,
Diplomate ACVIM
(Small Animal Internal
Medicine)

IMAGING PERFORMED BY

Dr. Megan Cassels-
Conway

HOSPITAL NAME

Central Broward AH

REFERRING VET

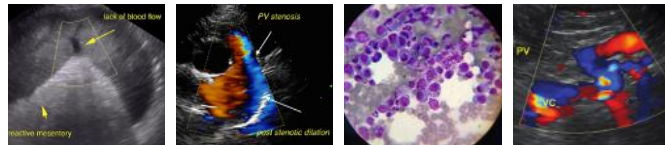
Dr. Janeen Lezcano

INVOICE

12484

DATE

11/8/21



PATIENT

Liver

Lillie Tamerian

The liver is subjectively prominent in size with swollen curvilinear peripheral contours. The parenchyma is isoechoic relative to the spleen and exhibits mild heterogeneity. No distinct focal lesions are observed. Hepatic vasculature and biliary tracts are of normal volume with no evidence of congestion. The gall bladder lumen is moderately distended. The wall is thin and smooth. A moderate amount of aggregated echogenic to mineralized partially dependent to suspended debris/sludge is observed within the lumen. The cystic and common bile ducts are normal/not seen.

SPECIES

Canine

BREED

Shih Tzu

SEX

Female, spayed

AGE

14 Yrs. 10 mo.

WEIGHT

8.3 lbs.

Gastrointestinal

The stomach and intestine are free of stasis and exhibit normal peristaltic activity. The gastric lumen is not distended. The gastric wall and pylorus are normal in thickness with a normal layering pattern. The pyloric outflow tract is patent. The small intestinal lumen is segmentally dilated with chyme. The small intestinal wall thickness is normal with a normal layering pattern and appropriate mural detail. Discreet masses are not identified. The colonic wall is normal. No obstructive disease is noted.

Pancreas

The left limb of the pancreas is visible with normal curvilinear peripheral contours. The parenchyma is largely isoechoic relative to surrounding omental fat and slightly mottled in appearance. The pancreatic duct is visible but not overtly dilated. There is no evidence of peripancreatic inflammation or effusion.

Free Abdomen

There is no evidence of free fluid. The abdominal lymph nodes are normal/not visible.

INTERPRETED BY

Andrea Nicastro, DVM,
Diplomate ACVIM
(*Small Animal Internal
Medicine*)

**IMAGING
PERFORMED BY**

Dr. Megan Cassels-
Conway

HOSPITAL NAME

Central Broward AH

REFERRING VET

Dr. Janeen Lezcano

INVOICE

12484

DATE

11/8/21

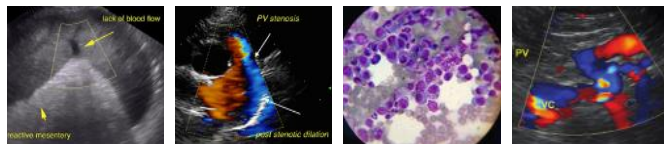
ULTRASONOGRAPHIC FINDINGS

Primary Findings:

- The splenic parenchymal changes are concerning for infiltrative neoplasia (i.e., lymphoma, other round cell tumor) with a lower possibility of benign pathology.

Secondary findings:

- The diffuse hepatic changes are non-specific and could be consistent with vacuolar hepatopathy, regenerative nodular hyperplasia, and/or age-related remodeling. Inflammatory and infiltrative disease are considered less likely. (Changes are similar to the previous sonogram).
- Gallbladder sludge, non-mucocele.
- The pancreatic changes may be a normal variant for this patient or could be consistent with mild, chronic pancreatitis. Correlation with clinical findings is recommended.
- Bilateral age-related renal changes with non-obstructive nephrolithiasis. (Changes similar to previous sonogram).
- The urinary bladder wall changes could be consistent with cystitis or may be artifactual due to lack of full repletion. Correlation with clinical findings is recommended.



PATIENT

Lillie Tamerian

SPECIES

Canine

BREED

Shih Tzu

SEX

Female, spayed

AGE

14 Yrs. 10 mo.

WEIGHT

8.3 lbs.

INTERPRETED BY

Andrea Nicastro, DVM,
Diplomate ACVIM
(Small Animal Internal
Medicine)

IMAGING PERFORMED BY

Dr. Megan Cassels-
Conway

HOSPITAL NAME

Central Broward AH

REFERRING VET

Dr. Janeen Lezcano

INVOICE

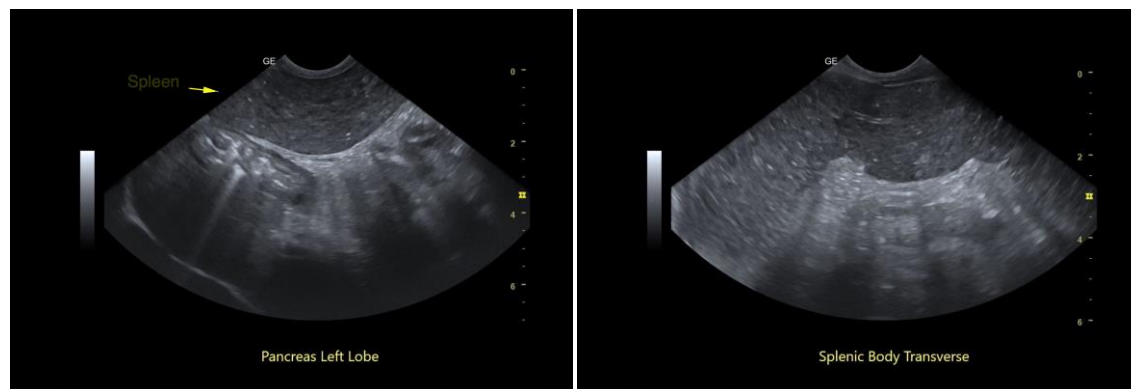
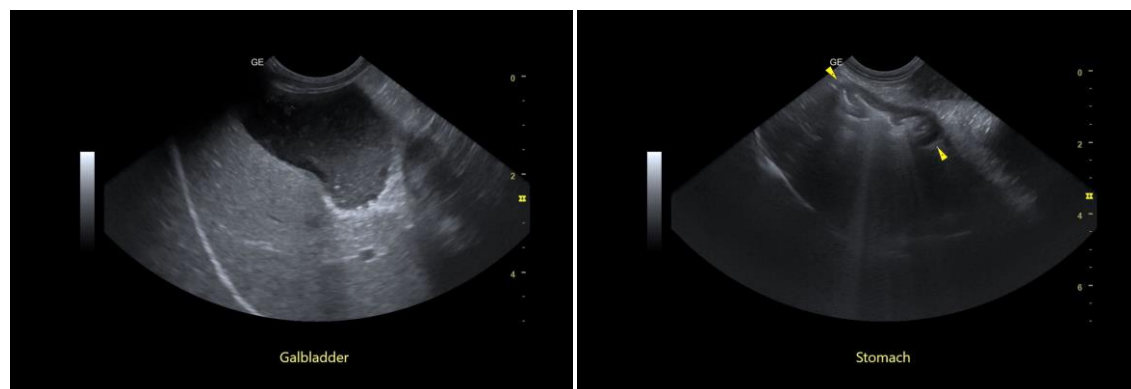
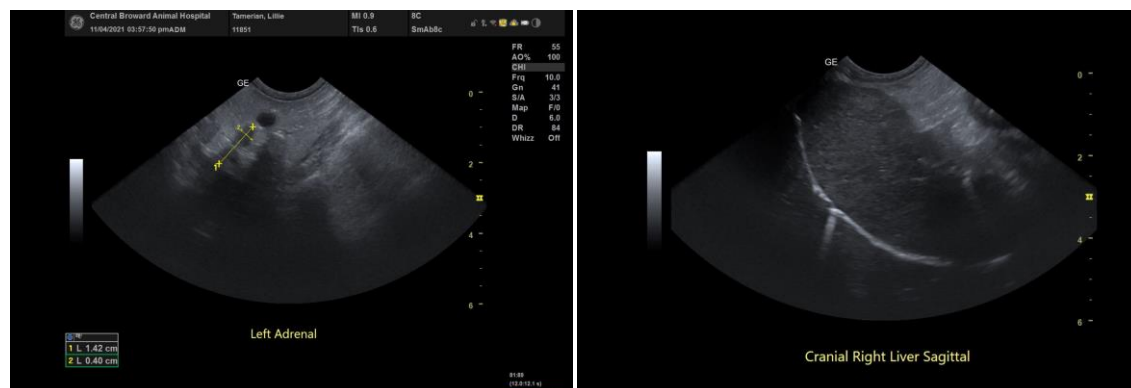
12484

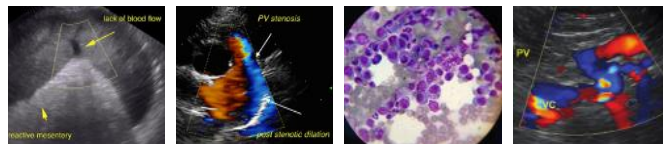
DATE

11/8/21

INTERPRETATION OF THE FINDINGS & FURTHER RECOMMENDATIONS

- Three-view thoracic radiographs are recommended to assess for neoplasia in the chest.
- A fine needle aspirate of the spleen is also recommended if clotting status is appropriate. A 25-gauge needle should be used. If cytologic evaluation is inconclusive, a splenectomy with submission of the spleen for histopathology may be necessary to get a definitive diagnosis.





PATIENT

Lillie Tamerian

SPECIES

Canine

BREED

Shih Tzu

SEX

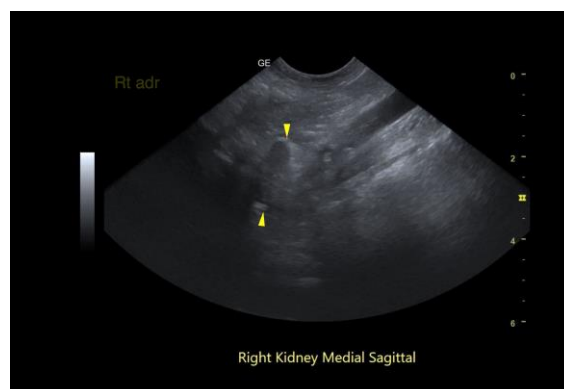
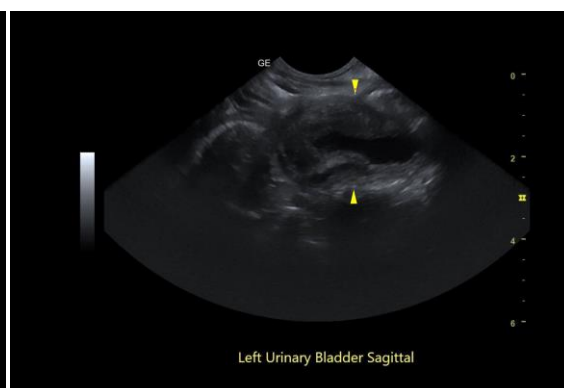
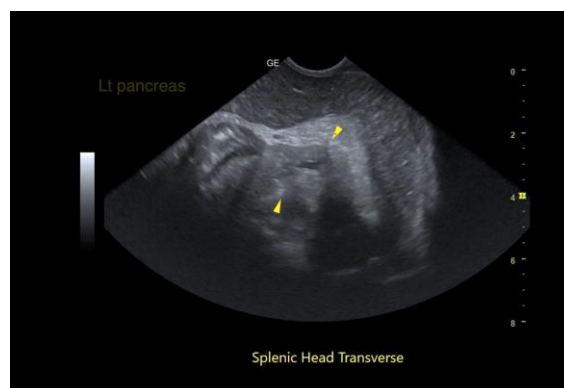
Female, spayed

AGE

14 Yrs. 10 mo.

WEIGHT

8.3 lbs.



INTERPRETED BY

Andrea Nicastro, DVM,
Diplomate ACVIM
(*Small Animal Internal
Medicine*)

The information and recommendations provided are based on the images presented by the referring veterinarian. No evaluation can be communicated regarding pathology that was not visible in the image/video clips provided.

Thank you for this referral. If the clinical or image interpretation does not parallel your findings or if I can be of any further assistance please contact me.

IMAGING PERFORMED BY

Dr. Megan Cassels-
Conway

Andrea Nicastro, DVM, Diplomate ACVIM (*Small Animal Internal Medicine*)

Andrea.nicastro@sonopath.com

HOSPITAL NAME

Central Broward AH

REFERRING VET

Dr. Janeen Lezcano

INVOICE

12484

DATE

11/8/21