



PATIENT	PRESENTING CLINICAL SIGNS
Chase Hamsher	History: Presented at our hospital for potential seizure. O reports that he was on his bed and then started paddling and trying to stand, but then had trouble getting up. O stood him up and pet was off balanced, ataxic, tilting to the right. Urinated and had BM in house. Also vomited bile twice.
SPECIES	Previous Health Concerns: Seizures, skin allergies, chronic diarrhea
Canine	Current Medications/Supplements/OTC: Metronidazole 250mg ½ tab q 12 PRN, had a dose last night. Apoquel 16mg ¼ tab q 12-24 had a dose last night, just started 3 days ago, Diazepam 2mg ½ tab q 12 has last night, O reports he only gives on the days he has more than one seizure in a day. Carprofen 25mg ½- ¾ tab q 12 as needed for pain, has not had in a while per O. Famotidine 10mg ½ tab q 12, has not had in a while per O. Phenobarb 16.2mg q 12- has not had for a couple of weeks, only gives when has more than one seizure in a day
BREED	
Yorkshire Terrier Mix	
SEX	Abnormal PE/Chem/CBC/UA Results:
Neutered Male	Cardiovascular: Localized left sided 2-3/6 holosystolic murmur Abdominal: cranial palpable mass; reactive on palpation Radiographs: cardiomegaly; no pulmonary edema noted; dorsal displacement of stomach with loss of detail and mass effect cranial abdomen- area of liver/spleen; bridging arthritis along spine Chemistry: BUN 59.8 H, Ca 12.6 H, Globulin 3.7 H, Glucose 141 H, Cholesterol 411 H, ALT 139 H, ALP 675 H, GGT 22 H, Amylase 1667 H, Lipase >1000 H CBC: WBC 20.62 H, PMN 12.95 H, Eos 2.61 H Manual PCV/TP: 40/9 EPOC: Lactate 5.06 H, BUN 50 H, Glucose 140 H
AGE	
14 years	
WEIGHT	ULTRASONOGRAPHIC EXAMINATION OF THE ABDOMEN
5.7 kg	Urinary System The urinary bladder, trigone, and pelvic urethra are normal in thickness and the mucosal surface is smooth. The bladder lumen is distended with anechoic urine. No masses, inflammatory changes or calculi are observed. The region of the trigone is normal. The region of the prostate is not visualized due to its pelvic location. The left kidney is normal size (4.66 cm in length); normal shape and architecture with smooth peripheral margins. There is a normal 1:3 cortex to medulla ratio with minimal to mild loss of corticomedullary distinction. A 0.66 cm cortical cyst is observed at the cranial pole. Mild to moderate pyelectasia is present (0.47 cm in the transverse plane). There is no evidence of nephroliths, infarcts or hydroureter. Renal vasculature is normal. The right kidney is normal size (5.23 cm in length); normal shape and architecture with smooth peripheral margins. There is a normal 1:3 cortex to medulla ratio with mild loss of corticomedullary distinction. A few, small cortical cysts are seen. Mild pyelectasia is present (0.26 cm in the transverse plane). There is no evidence of nephroliths, infarcts or hydroureter. Renal vasculature is normal.
INTERPRETED BY	
Andrea Nicastro, DVM, Diplomate ACVIM (<i>Small Animal Internal Medicine</i>)	
IMAGING PERFORMED BY	
Erin Wicks	
HOSPITAL NAME	
Shores Vet Emerg Ctr	
REFERRING VET	Adrenal Glands The left adrenal gland is upper limits of normal size (0.50 cm at cranial pole) (0.56 cm at caudal pole); normal shape; homogenous parenchyma. The glandular echogenicity and detail are unremarkable. Capsule, cortex, and medullary definition are normal. The phrenicoabdominal vein and surrounding vasculature are normal.
Dr Lupole.	
INVOICE	The region of the right adrenal gland is evaluated. No obvious pathology is observed.
11963	
DATE	
11.4.22	

Spleen

The spleen is normal in size (1.55 cm in width at the level of the hilus) with a normal capsular contour. There is appropriate echogenicity and echotexture. No focal lesions are observed. Splenic vasculature is normal.

Liver

The liver is enlarged with swollen, irregular peripheral contours. The parenchyma is isoechoic relative to the spleen and heterogenous with a mass effect, particularly on the left side. Varying-sized, irregular, hyperechoic nodules are observed throughout the organ. Hepatic vasculature and intrahepatic biliary tracts are of normal volume with no evidence of congestion.

The gall bladder is of normal contours and contains some dependent echogenic debris. The wall is normal in thickness. No choleliths are observed. The cystic and common bile ducts are normal/not seen.

Gastrointestinal

The stomach and intestine are free of stasis and exhibit normal peristaltic activity. The gastric lumen is not distended. The gastric wall and pylorus are normal in thickness with a normal layering pattern. The pyloric outflow tract is patent. The small intestinal lumen is not dilated. The small intestinal wall thickness is normal with a normal layering pattern and appropriate mural detail. Discreet masses are not identified. The colonic wall is normal. No obstructive disease is noted.

Pancreas

The base and limbs of the pancreas are visible with normal curvilinear peripheral contours. The parenchyma is largely isoechoic relative to surrounding omental fat and slightly mottled in appearance. The pancreatic duct is visible but not overtly dilated. There is no evidence of peripancreatic inflammation or effusion.

Free Abdomen

There is no evidence of free fluid. The abdominal lymph nodes are normal/not visible.

ULTRASONOGRAPHIC FINDINGS

Primary Findings

- The hepatic changes could be consistent with a benign process (i.e., excessive regenerative nodular hyperplasia and/or vacuolar hepatopathy). Alternatively, neoplasia (i.e., adenocarcinoma, round cell tumor) is possible.

Secondary Findings

- The pancreatic changes are most consistent with age-related parenchymal remodeling, potentially secondary to a prior inflammatory episode, early fibrosis or chronic pancreatitis.
- Bilateral degenerative renal changes with pyelectasia

INTERPRETATION OF THE FINDINGS & FURTHER RECOMMENDATIONS

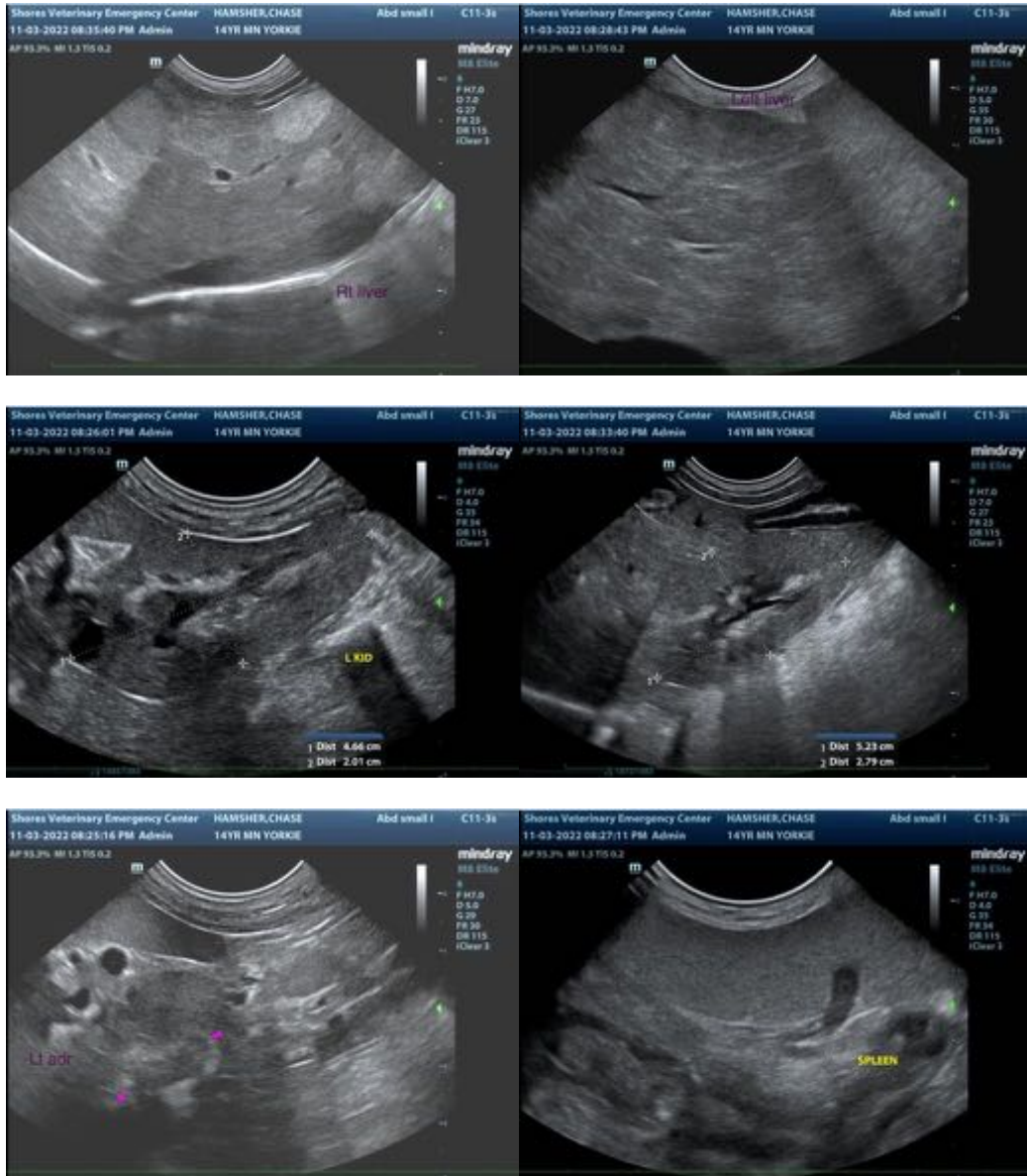
Consider a fine-needle aspirate of the liver, if clotting status is appropriate. A 25-gauge needle should be used. If cytology results are inconclusive, liver biopsies (i.e., laparoscopic, or surgical) may be necessary to get a definitive diagnosis.

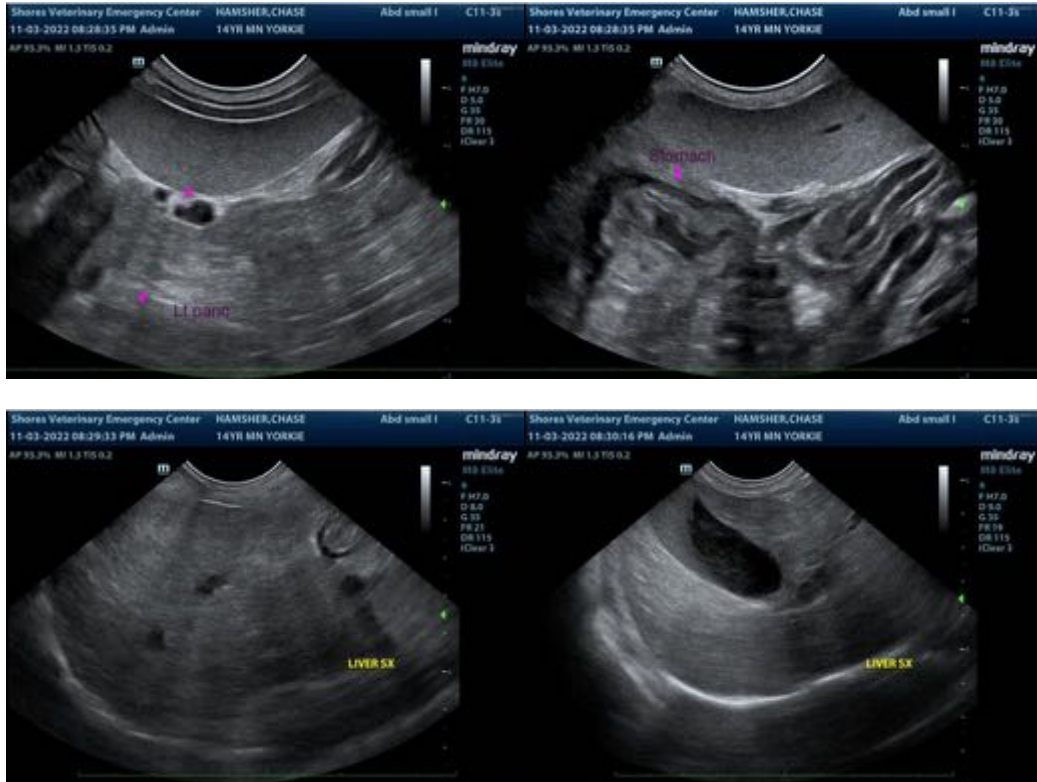
Regarding the renal changes, consider the following:

1. A urine culture and sensitivity is recommended.

2. A UPC is also recommended.
3. Consider a baseline blood pressure measurement

Regarding the hypercalcemia, consider an ionized calcium/PTH/PTHrP, as well as a thorough rectal examination to assess for anal gland masses.





The information and recommendations provided are based on the images presented by the referring veterinarian/sonographer. No evaluation can be communicated regarding pathology that was not visible in the image/video clips provided.

Thank you for this referral. If the clinical or image interpretation does not parallel your findings or if I can be of any further assistance, please contact me.

Andrea Nicastro, MPH, DVM, Diplomate DACVIM (Small Animal Internal Medicine)
info@SonoPath.com