

**DATE PRESENTING CLINICAL SIGNS**

11/4/21 History: intermittent bleeding (frank blood) from penis since 2019 - initial response to antibiotics - recently (10/28/2021) culture negative.

**PATIENT**

Jethro Mahjoub

Current Medications: Carprofen.

Lab Results: Urine culture- neg.

Radiographs: Not provided by the veterinarian.

**SPECIES**

Date of Previous IntraPet Ultrasound: 11-11-2019.

Canine

Sedation: DexDomitor administered prior to scan.

Stat Report: STAT report not requested by the veterinarian.

**BREED**

Pitbull Terrier Mix

**ULTRASONOGRAPHIC EXAMINATION OF THE ABDOMEN****SEX****Urinary System**

The urinary bladder, trigone, and pelvic urethra are normal in thickness and the mucosal surface is smooth. The bladder lumen is moderately distended with mostly anechoic urine. No masses, inflammatory changes or calculi are observed. Ureteral papillae and visualized portion of the proximal urethra, visible to a depth of 2.0 cm, are normal. No obvious abnormalities are observed within the penile urethra.

Neutered Male

**AGE**

11/2/2011

The prostate is normal in size (1.20 cm in width) and shape. Parenchyma is homogenous. The prostatic urethra appears normal without evidence of dilation or obstruction.

**WEIGHT**

62 Pounds

The left kidney was normal in size (6.84 cm in length); normal shape and smooth peripheral contours. There is a normal cortex to medulla ratio. The cortex is heterogeneous in appearance and there is poor corticomedullary distinction. Numerous nephroliths are visualized. Moderate pyelectasia is present (0.34 cm in the longitudinal plane). There is no evidence of hydroureter. Renal vasculature is normal.

**INTERPRETED BY**

Andrea Nicastro, DMV,  
Diplomate DACVIM  
(Small Animal  
Internal Medicine)

The right kidney is normal in size (7.46 cm in length); with a slightly irregular shape. There is a normal 1:3 cortex to medulla ratio with poor corticomedullary distinction. Several small nephroliths are visualized. Mild pyelectasia is present (0.27 cm in the transverse plane). There is no evidence of hydroureter. Renal vasculature is normal.

**HOSPITAL NAME**

Eastern AH

**Adrenal Glands****REFERRING VET**

The left adrenal gland is normal size (0.71 cm at cranial pole) (0.61 cm at caudal pole) (3.10 cm in length); with a slightly irregular shape; homogenous parenchyma. The glandular echogenicity and detail are unremarkable. Capsule, cortex, and medullary definition are normal. The phrenicoabdominal vein and surrounding vasculature are normal.

Dr. Kaufman

**INVOICE**

14182

The right adrenal gland is normal size (0.72 cm at cranial pole) (0.66 cm at caudal pole) (4.07 cm in length); normal shape; homogenous parenchyma. The glandular echogenicity and detail are unremarkable. Capsule, cortex, and medullary definition are normal. The phrenicoabdominal vein and surrounding vasculature are normal.

**Spleen**

The spleen is normal in size (2.89 cm at the level of the hilus) with a normal capsular contour. There is appropriate echogenicity and echotexture. No focal lesions are observed. Splenic vasculature is normal.

### ***Liver***

The liver is subjectively normal in size with normal contours and structure. There is appropriate echogenicity and echotexture. No overt structural evidence of inflammatory, infiltrative or regenerative pathology is evident. Vascular and biliary tracts are of normal volume with no evidence of congestion. No pathological hepatic lymphadenopathy observed.

The gall bladder lumen is moderately distended. The wall is thin and smooth. A small amount of echogenic to slightly mineralized gravity dependent debris is observed within the lumen. The cystic and common bile ducts are normal.

### ***Gastrointestinal***

The stomach and intestine are free of stasis and exhibit normal peristaltic activity. The gastric lumen is not distended. The gastric wall and pylorus are normal in thickness with a normal layering pattern. The small intestinal lumen is not dilated. The small intestinal wall thickness is normal with a normal layering pattern and appropriate mural detail. Discreet masses are not identified. The colonic wall is normal. No obstructive or overt infiltrative disease is noted.

### ***Pancreas***

The region of the pancreas is isoechoic relative to surrounding omental fat. No obvious parenchymal abnormalities are observed. There is no evidence of regional inflammation or effusion.

### ***Free Abdomen***

The peritoneal cavity is normal. There is no evidence of inflammation or effusion. The abdominal lymph nodes are normal/not visible.

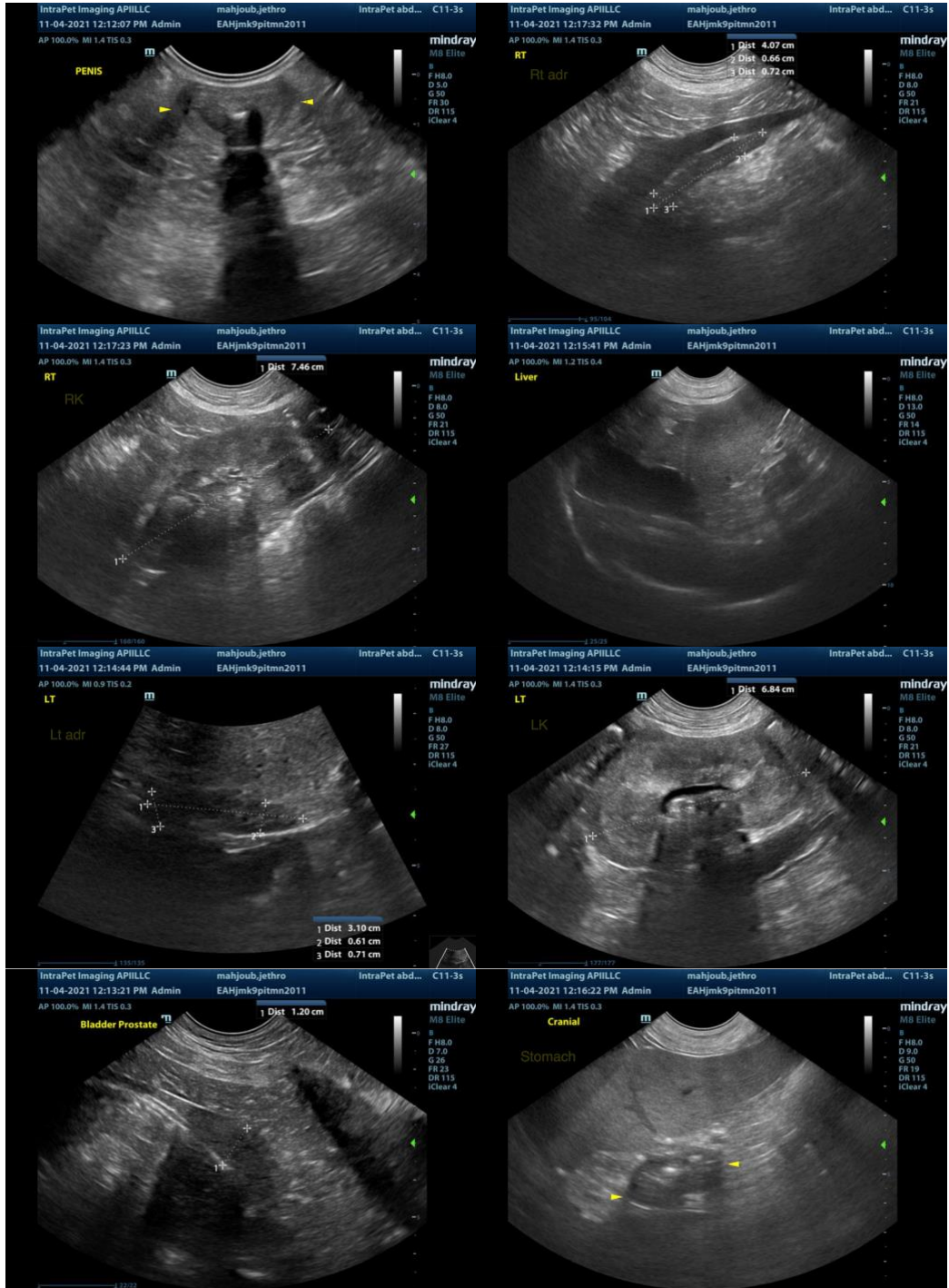
## **ULTRASONOGRAPHIC FINDINGS**

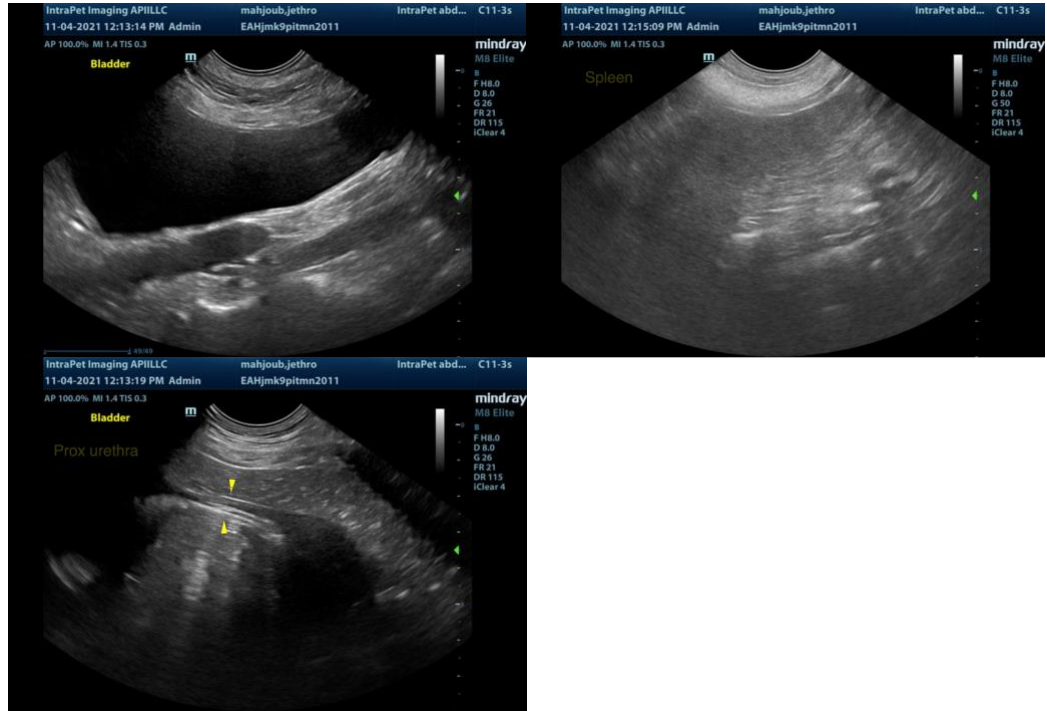
- Bilateral nephropathy with nonobstructive nephrolithiasis and mild pyelectasia

\*An obvious cause for the patients' clinical signs is not identified in the study. Considerations include occult urinary tract infection, renal hematuria, coagulopathy, intermittent passage of urinary stones, microscopic lower urinary tract neoplasia (less likely), other.

## **INTERPRETATION OF THE FINDINGS & FURTHER RECOMMENDATIONS**

- Consider abdominal/pelvic radiographs during episodes to assess for passage of urinary stones.
- Consider assessment of clotting factors, including Von Willebrand factor to assess for underlying coagulopathy.
- Consider a repeat urine culture and sensitivity when the patient is exhibiting clinical signs.
- A urine BRAF test can also be considered to screen for lower urinary tract neoplasia. However, given the chronicity of clinical signs, this differential is considered less likely.





**The information and recommendations provided are based on the images presented by the referring veterinarian. No evaluation can be communicated regarding pathology that was not visible in the image/video clips provided.**

Thank you for this referral. If the clinical or image interpretation does not parallel your findings or if I can be of any further assistance please contact me.

**Andrea Nicastro, DVM, Diplomate DACVIM (Small Animal Internal Medicine)**  
info@SonoPath.com