



## PATIENT PRESENTING CLINICAL SIGNS

Esther Logan

History: Lethargic Weight loss Not eating well. In addition to the above, the owners report they have been battling a flea problem with Esther since the spring. They mentioned using Frontline.

## SPECIES

Feline

Abnormal PE/Chem/CBC/UA Results: Heart Murmur Auscultated, Grade II-III/VI heart murmur, pmi caudal sternum. CBC: Normal WBC count. Significant anemia, RBC 3.06, HCT 13%. Thrombocytopenia, platelets 90k. EPOC: Minimally decreased Na<sup>+</sup> 144 mmol/L, K<sup>+</sup> 3.5 mmol/L, and ionized calcium 0.87 mmol/L. Significantly decreased HCT 12%. (HCT 22% post blood transfusion) Chemistry: All normal, except for a minimally elevated T.bili 0.6 mg/dL. T4 level: 2.5 ug/dL. (normal) FELV/FIV test: Negative/ negative. Normal trachea, heart, and lungs. Normal liver, but the margins are not easily definable. Empty stomach. Prominent/ enlarged spleen. Normal intestines. No obvious GI FB or intestinal obstructive pattern. Minimal feces in the colon. Normal kidneys. Small urinary bladder. Normal spine.

## BREED

DSH

## SEX

Female Spayed

## ULTRASONOGRAPHIC EXAMINATION OF THE ABDOMEN

### AGE *Urinary System*

12

The urinary bladder is moderately distended. The wall is normal in thickness with a smooth mucosal surface. A moderate amount of echogenic to mineralized debris/sand is observed within the lumen. The region of the trigone and visible portion of the proximal urethra are normal.

### WEIGHT

4.37

The left kidney is normal in size (3.75 cm in length) with a normal shape, smooth peripheral margins, and normal internal architecture. There is minimal loss of corticomedullary distinction. Several hyperechoic shadowing diverticular foci are observed. There is no evidence of pyelectasia, infarcts or hydronephrosis. Renal vasculature is normal.

### INTERPRETED BY

Andrea Nicastro, DVM,  
Diplomate ACVIM  
(Small Animal Internal  
Medicine)

The right kidney is normal in size (3.83 in length) with a normal shape, architecture and smooth peripheral margins. There is a normal 1:3 cortex to medulla ratio with minimal loss of corticomedullary distinction. There is no evidence of pyelectasia, nephroliths, infarcts or hydronephrosis. Renal vasculature is normal.

### IMAGING PERFORMED BY

Erin Wicks

### *Adrenal Glands*

The left adrenal gland is normal size (0.33 cm width). Normal shape and glandular echogenicity. The phrenicoabdominal vein and surrounding vasculature are normal.

### HOSPITAL NAME

Shores VEC

The right adrenal gland is normal size (0.39 cm width). Normal shape and glandular echogenicity. The phrenicoabdominal vein and surrounding vasculature are normal.

### REFERRING VET

Lisa Miller

### *Spleen*

The spleen is mildly enlarged (1.10 cm in width at the level of the hilus) with swollen peripheral contours. The parenchyma is subjectively hypoechoic and homogenous in appearance. Splenic vasculature appears normal with no evidence of thrombosis.

### INVOICE

22213

The liver is subjectively normal in size with normal curvilinear peripheral contours. The parenchyma is isoechoic relative to the spleen and diffusely homogeneous in appearance. No distinct focal lesions are observed. Vascular and biliary tracts are of normal volume with no evidence of congestion.

### DATE

11-3-25

The gallbladder is of normal contours and contains some dependent echogenic debris. The wall is normal in thickness. No choleliths are observed. The cystic and common bile ducts are normal.

### *Gastrointestinal*

The gastric lumen is not distended. The gastric wall and pylorus are normal in thickness with a normal



## PATIENT

Esther Logan

layering pattern. The pyloric outflow tract is patent. The small intestinal lumen is not dilated. The small intestinal wall is normal in thickness with a normal layering pattern and appropriate mural detail. Discreet masses are not identified. The colonic wall is normal. There is no evidence of an obstructive pattern.

## SPECIES

Feline

### **Pancreas**

The limb of the pancreas is visible with normal curvilinear peripheral contours. The parenchyma is slightly hypoechoic relative to surrounding omental fat and slightly mottled in appearance. The pancreatic duct is visible but not overtly dilated. There is no evidence of peripancreatic inflammation or effusion.

## BREED

DSH

### **Lymph Nodes**

The abdominal lymph nodes are normal/not visible.

## SEX

Female Spayed

### **Free Abdomen**

Trace free fluid is observed.

## ULTRASONOGRAPHIC FINDINGS

### AGE

12

### Primary Findings

- The splenic parenchymal changes are most consistent with a benign process such as lymphoid hyperplasia, extramedullary hematopoiesis, splenitis or antigenic stimulation with a lower possibility of infiltrative neoplasia (i.e., lymphoma, mast cell neoplasia).
- Trace ascites

### WEIGHT

4.37

### Secondary Findings

- Urinary bladder debris/sand
- Minor dystrophic mineralization in the left kidney
- The pancreatic changes are most consistent with age-related parenchymal remodeling, potentially secondary to a prior inflammatory episode, early fibrosis or chronic pancreatitis.

## INTERPRETED BY

Andrea Nicastro, DVM,  
Diplomate ACVIM  
(Small Animal Internal  
Medicine)

## IMAGING PERFORMED BY

Erin Wicks

## HOSPITAL NAME

Shores VEC

\*An obvious cause for the severe anemia is not definitively identified in this study. Broad considerations include regenerative anemia (i.e., blood loss, hemolysis) vs nonregenerative anemia (i.e., occult neoplasia, chronic disease, other).

## INTERPRETATION OF THE FINDINGS & FURTHER RECOMMENDATIONS

## REFERRING VET

Lisa Miller

- A CBC with a reticulocyte count and clinical pathology review is recommended, along with a slide agglutination test.
- Consider testing for vector-borne disease (i.e., *Mycoplasma haemofelis*) +/- tick-borne diseases.

## INVOICE

22213

- Three-view thoracic radiographs are recommended to assess for occult disease in the chest.

## DATE

11-3-25

- Feline leukemia and FIV testing should also be considered (if not already performed).

- Consider fine-needle aspiration of the spleen to assess for infiltrative neoplasia (i.e., round cell tumor) assuming normal clotting status. A 25-gauge needle should be used.



**PATIENT**

Esther Logan

- Depending on the results of the above diagnostics, a bone marrow aspirate may be indicated. If pursued, a feline leukemia immunofluorescence assay should be performed on a marrow sample.

**SPECIES**

Feline

**BREED**

DSH

**SEX**

Female Spayed

**AGE**

12

**WEIGHT**

4.37

**INTERPRETED BY**

Andrea Nicastro, DVM,  
Diplomate ACVIM  
(Small Animal Internal  
Medicine)

**IMAGING PERFORMED BY**

Erin Wicks

**HOSPITAL NAME**

Shores VEC

**REFERRING VET**

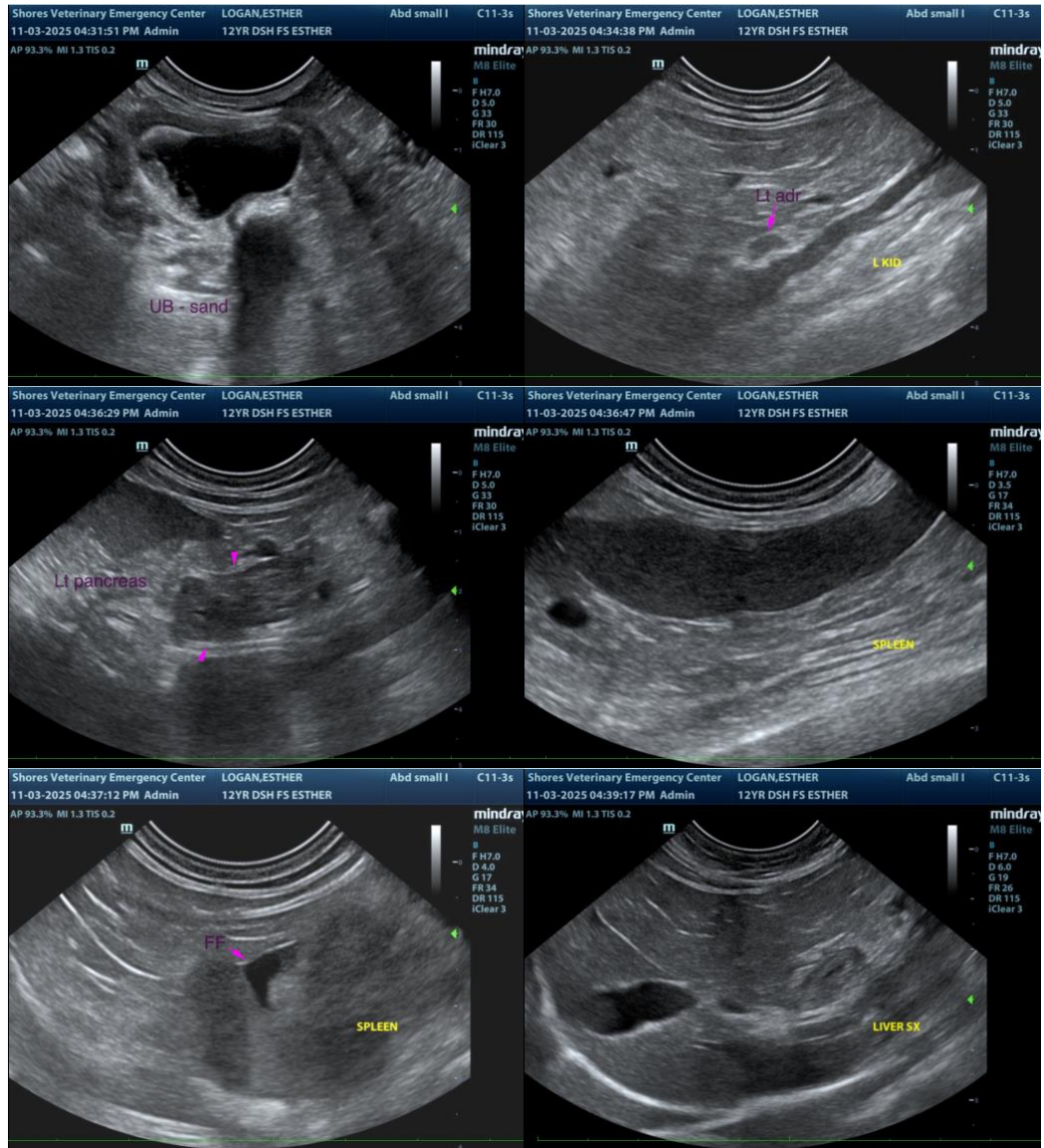
Lisa Miller

**INVOICE**

22213

**DATE**

11-3-25





## PATIENT

Esther Logan

## SPECIES

Feline

## BREED

DSH

## SEX

Female Spayed

## AGE

12

## WEIGHT

4.37

## INTERPRETED BY

Andrea Nicastro, DVM,  
Diplomate ACVIM  
(Small Animal Internal  
Medicine)

## IMAGING PERFORMED BY

Erin Wicks

## HOSPITAL NAME

Shores VEC

## REFERRING VET

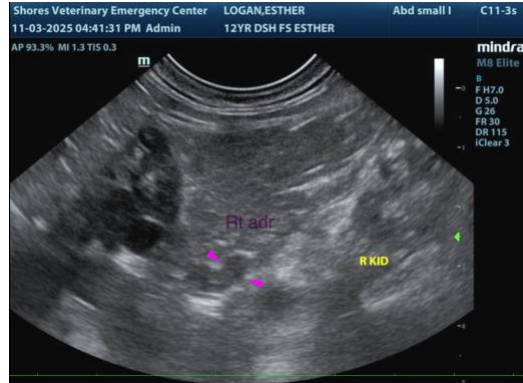Lisa Miller

## INVOICE

22213

## DATE

11-3-25



The information and recommendations provided are based on the images presented by the referring veterinarian/sonographer. No evaluation can be communicated regarding pathology that was not visible in the image/video clips provided.

Thank you for this referral. If the clinical or image interpretation does not parallel your findings or if I can be of any further assistance, please contact me.

**Andrea Nicastro, MPH, DVM, Diplomate DACVIM (Small Animal Internal Medicine)**  
[info@SonoPath.com](mailto:info@SonoPath.com)