



**DATE PRESENTING CLINICAL SIGNS**

11/3/25

**Patient History:** CC: 9/30/25 lethargic. History: nothing significant except new kitten in house a few weeks prior. PE: Fever of 104.5. 1.75# weight loss in 4 months.

**PATIENT**

Cooper Quinn

**Current Medications:** Cerenia: 40 mg SID as needed, Mirataz: 1 mg SID as needed

**Labwork Results:** Labwork attached, reported as: No obvious problems detected. CBC: WNL. CHEM: WNL T4: 2.3. spec FPL: 0.9 (normal). proBNP: normal ...low 20's. FELV/FIV: negative/negative

**Date of Previous IntraPet Ultrasound:** No previous.

**SPECIES**

Feline

**Sedation:** IM.

**Stat Report:** Not requested.

**Imaging Performed by:** Rachel Brillhart, RDMS.

**BREED**

Domestic shorthair

**ULTRASONOGRAPHIC EXAMINATION OF THE ABDOMEN**

**SEX**

Male, neutered

**Urinary System**

The urinary bladder wall is normal in thickness and the mucosal surface is smooth. The bladder is moderately distended. Luminal contents are anechoic. No cystic calculi are observed. The region of the trigone and the visible portion of the proximal urethra are normal.

**AGE**

4/17/2019

The left kidney is normal in size (4.22 cm in length) with a normal shape, architecture and smooth peripheral margins. There is a normal 1:3 cortex to medulla ratio with minimal loss of corticomedullary distinction. There is no evidence of pyelectasia, nephroliths, infarcts or hydroureter. Renal vasculature is normal.

**WEIGHT**

14.25 lbs.

The right kidney is normal in size (4.31 cm in length) with a normal shape, architecture and smooth peripheral margins. There is a normal 1:3 cortex to medulla ratio with minimal loss of corticomedullary distinction. There is no evidence of pyelectasia, nephroliths, infarcts or hydroureter. Renal vasculature is normal.

**INTERPRETED BY**

**Adrenal Glands**

The left adrenal gland is normal size (0.48 cm width). Normal shape and glandular echogenicity. The phrenicoabdominal vein and surrounding vasculature are normal.

The right adrenal gland is normal size (0.41 cm width). Normal shape and glandular echogenicity. The phrenicoabdominal vein and surrounding vasculature are normal.

**Spleen**

The spleen is normal in size (0.77 cm in width at the level of the hilus) with a normal capsular contour. There is appropriate echogenicity and echotexture. A 0.34 cm ill-defined hyperechoic nodule is observed within the parenchyma near the caudal aspect. Splenic vasculature is normal.

**Liver**

The liver is subjectively normal in size with normal contours and structure. There is appropriate echogenicity and echotexture. No overt structural evidence of inflammatory, infiltrative, or regenerative pathology is evident. Vascular and biliary tracts are of normal volume with no evidence of congestion.

The gall bladder lumen is moderately distended. The wall is normal to borderline thickened (up to 0.10 cm). A scant amount of echogenic debris is observed within the lumen. The cystic and common bile ducts are normal/not seen.

**INVOICE**

13297

Andrea Nicastro, DVM,  
Diplomate ACVIM  
(Small Animal Internal  
Medicine)

**HOSPITAL NAME**

Harborside Mobile VC

**REFERRING VET**

Dr. Hawkins

### ***Gastrointestinal***

The stomach and intestine are free of stasis and exhibit normal peristaltic activity. The gastric lumen is not distended. The gastric wall and pylorus are normal in thickness with a normal layering pattern. The pyloric outflow tract is patent. The small intestinal lumen is not dilated. The small intestinal wall is normal to mildly thickened (up to 0.30 cm). There is disruption in the normal 1:3 muscularis: mucosal ratio in several segments. Discreet masses are not identified. The ileocecal colic junction and colonic wall are normal. No obstructive disease is noted.

### ***Pancreas***

The left limb of the pancreas is visible with normal curvilinear peripheral contours. The parenchyma is largely isoechoic relative to surrounding omental fat and slightly mottled in appearance. The pancreatic duct is visible but not overtly dilated. There is no evidence of peripancreatic inflammation or effusion.

### ***Lymph nodes***

A 0.53 x 0.34 cm gastric lymph node is visualized. A few prominent mesenteric lymph nodes are also seen adjacent to the ileocecolic junction, one of the nodes measuring 0.76 x 0.41 cm.

### ***Free Abdomen***

There is no obvious evidence of free fluid.

## **ULTRASONOGRAPHIC FINDINGS**

### **Primary Findings:**

- The pancreatic changes are most consistent with age-related parenchymal remodeling, potentially secondary to a prior inflammatory episode, early fibrosis or chronic pancreatitis.
- The small intestinal wall changes could be consistent with inflammatory bowel disease or may be a normal variant for this patient. Correlation with the patient's long term clinical history is recommended.
- The prominent abdominal lymph nodes are most consistent with reactive lymphadenitis or lymphoid hyperplasia. Neoplastic infiltration is considered less likely.

### **Secondary Findings:**

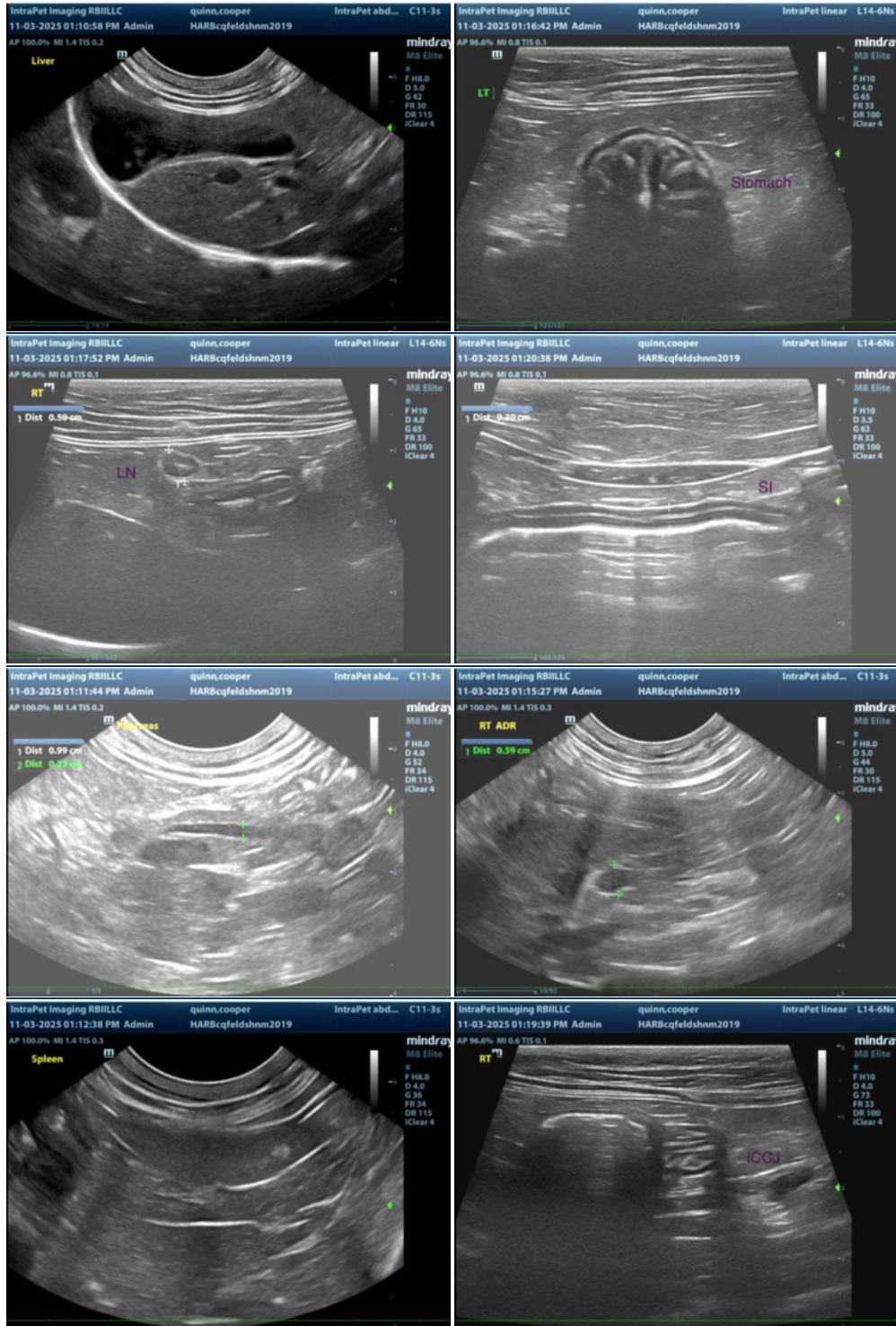
- The hyperechoic splenic nodule likely represents a benign meylolipoma with a low possibility of a more insidious splenic pathology.

\*An obvious cause for the patient's clinical signs is not definitively identified in this study. Broad considerations include maldigestion/malabsorption, occult neoplasia, underlying metabolic issue, orthopedic or neurologic disease, other.

## **INTERPRETATION OF THE FINDINGS & FURTHER RECOMMENDATIONS**

1. Orthopedic and neurologic examinations are recommended.
2. Three-view thoracic radiographs should be considered to assess for occult pathology in the chest.
3. Consider a GI panel including serum cobalamin, folate, TLI and PLI to assess for maldigestion/malabsorption, pancreatic disease.
4. A fecal evaluation for ova/Giardia should also be considered.
5. Given the fever, a comprehensive fever of unknown origin infectious disease panel is also recommended.

6. While awaiting test results, symptomatic care should be initiated.



**The information and recommendations provided are based on the images presented by the referring veterinarian/sonographer. No evaluation can be communicated regarding pathology that was not visible in the image/video clips provided.**

Thank you for this referral. If the clinical or image interpretation does not parallel your findings or if I can be of any further assistance please contact me.

Andrea Nicastro, MPH, DVM, Diplomate DACVIM (Small Animal Internal Medicine) [info@SonoPath.com](mailto:info@SonoPath.com)