

**DATE**

11.3.2022

PATIENT

Bohdi Williams

SPECIES

Canine

BREED

Coonhound

SEX

Neutered Male

AGE

5/1/2017

WEIGHT

57.2lbs

INTERPRETED BY

Andrea Nicastro, DMV,
 Diplomate DACVIM
 (Small Animal
 Internal Medicine)

HOSPITAL NAME

Fullerton AH

REFERRING VET

Dr. Levine

INVOICE

11965

PRESENTING CLINICAL SIGNS

Follow up to monitor any changes to spleen- 9/21 p had a negative abdominal exploratory given concerns about a GI foreign body at the time. Grossly, nodule on the spleen was noted then. Elected not to splenectomize at that time. Ultrasound to determine whether there are any ongoing changes in the abdomen. P was seen on 10-21-22 for vaccines, had edema that had started resolving over the right hind limb.

Current Medications: None.

Radiographs: hind limb showed signs of soft tissue edema.

Date of Previous IntraPet Ultrasound: 10/25/21. See attached.

Sedation: Not required to complete full diagnostic ultrasound.

Stat Report: Not requested.

Imaging Performed By: Rachel Brillhart, RDMS.

ULTRASONOGRAPHIC EXAMINATION OF THE ABDOMEN**Urinary System**

The **urinary bladder** wall is normal in thickness and the mucosal surface is smooth. The bladder lumen is moderately distended with anechoic urine. No masses, inflammatory changes or calculi are observed. Ureteral papillae and visualized portion of the proximal urethra, visible to a depth of 2 cm, are normal.

The **prostate** is normal in size (1.23 cm in width) and shape. Parenchyma is homogenous. The prostatic urethra appears normal without evidence of dilation or obstruction.

The **left kidney** is normal size (5.93 cm in length); normal shape and architecture with smooth peripheral margins. There is a normal 1:3 cortex to medulla ratio with normal corticomedullary distinction. There is no evidence of pyelectasia, nephroliths, infarcts or hydronephrosis. Renal vasculature is normal.

The **right kidney** is normal size (6.02 cm in length); normal shape and architecture with smooth peripheral margins. There is a normal 1:3 cortex to medulla ratio with normal corticomedullary distinction. There is no evidence of pyelectasia, nephroliths, infarcts or hydronephrosis. Renal vasculature is normal.

Adrenal Glands

The **left adrenal gland** is normal size (0.52 cm at cranial pole) (0.54 cm at caudal pole) (2.55 cm in length); normal shape; homogenous parenchyma. The glandular echogenicity and detail are unremarkable. Capsule, cortex, and medullary definition are normal. The phrenicoabdominal vein and surrounding vasculature are normal.

The **right adrenal gland** is normal size (0.65 cm at cranial pole) (0.69 cm at caudal pole) (2.63 cm in length); normal shape; homogenous parenchyma. The glandular echogenicity and detail are unremarkable. Capsule, cortex, and medullary definition are normal. The phrenicoabdominal vein and surrounding vasculature are normal.

Spleen

The **spleen** is subjectively normal in size (1.89 cm in width at the level of the hilus). Just medial to the hilus, an approximately 2.22 cm isoechoic swelling is visualized. The parenchyma is homogenous. Splenic vasculature is normal with no evidence of thrombosis.

Liver

The **liver** is subjectively normal in size with normal contours and structure. There is appropriate echogenicity and echotexture. No overt structural evidence of inflammatory, infiltrative, or regenerative pathology is evident. Vascular and biliary tracts are of normal volume with no evidence of congestion. No pathological hepatic lymphadenopathy observed.

The gall bladder lumen is moderately distended. The wall is thin and smooth. A small to moderate amount of gravity dependent to partially dependent echogenic debris is observed within the lumen. The cystic and common bile ducts are normal/not seen.

Gastrointestinal

The **gastric lumen** is not distended. The gastric wall is normal in thickness with a normal layering pattern. The small intestinal lumen is not dilated. The small intestinal wall thickness is normal with a normal layering pattern and appropriate mural detail. Discreet masses are not identified. The colonic wall is normal. There is no evidence of an obstructive pattern.

Pancreas

The region of the **pancreas** is isoechoic relative to surrounding omental fat. No obvious parenchymal abnormalities are observed. There is no evidence of regional inflammation or effusion.

Free Abdomen

The **peritoneal cavity** is normal. There is no evidence of inflammation or effusion. The abdominal **lymph nodes** are normal/not visible.

Other

A **brief echocardiogram** reveals no evidence of pericardial effusion or obvious right atrial/auricular mass.

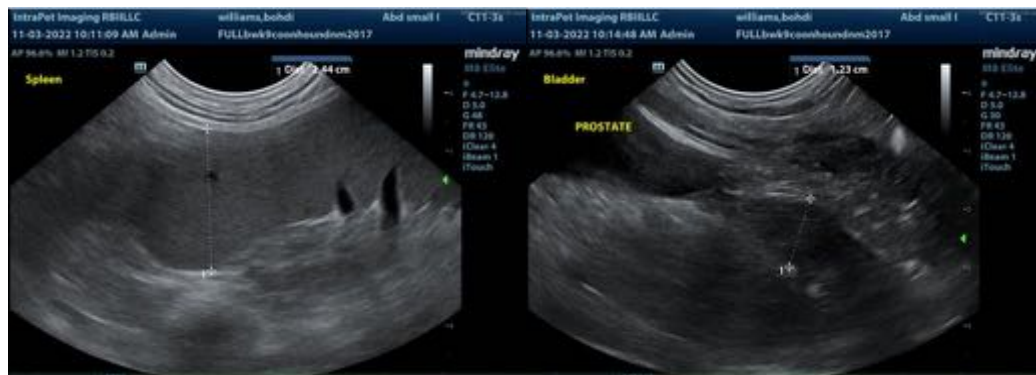ULTRASONOGRAPHIC FINDINGS

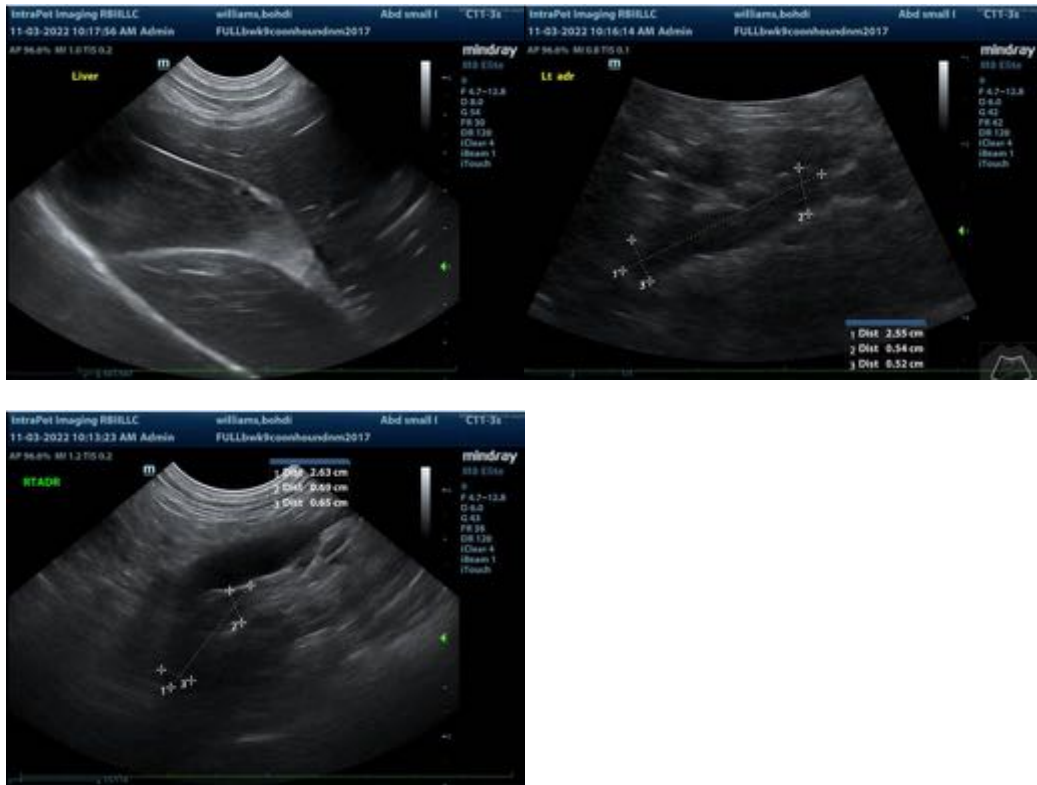
Primary Findings

- The splenic swelling is similar/unchanged compared to the previous sonogram. This finding may be a normal variant for this patient or may represent lymphoid hyperplasia, extramedullary hematopoiesis or other benign process. Infiltrative neoplasia is possible but considered less likely, particularly given the lack of growth since the sonogram performed one year ago.

INTERPRETATION OF THE FINDINGS & FURTHER RECOMMENDATIONS

Aspiration of the splenic swelling can be considered if more information is desired. Otherwise, continued sonographic monitoring (i.e., every 6 months) can be considered.





The information and recommendations provided are based on the images presented by the referring veterinarian/sonographer. No evaluation can be communicated regarding pathology that was not visible in the image/video clips provided.

Thank you for this referral. If the clinical or image interpretation does not parallel your findings or if I can be of any further assistance, please contact me.

Andrea Nicastro, MPH, DVM, Diplomate DACVIM (Small Animal Internal Medicine)
info@SonoPath.com