



PATIENT

Scout Nakata

SPECIES

Canine

BREED

Coton De Tulear

SEX

Female

AGE

12 Years

WEIGHT

9 Lbs.

INTERPRETED BY

Andrea Nicastro, DMV,
Diplomate DACVIM
(Small Animal
Internal Medicine)

IMAGING PERFORMED BY

Saum Hadi

HOSPITAL NAME

Bethany Family PC

REFERRING VET

Dr. Saum Hadi

INVOICE

12707

DATE

11/28/21

PRESENTING CLINICAL SIGNS

History: P was diagnosed with a 4x2x2 cm mast cell tumor on the ventral abdominal region. AUS performed today to evaluate for metastasis before surgical referral.

Abnormal PE/Chem/CBC/UA Results: CBC/Chem pending.

ULTRASONOGRAPHIC EXAMINATION OF THE ABDOMEN

Urinary System

The urinary bladder, trigone, and pelvic urethra are normal in thickness and the mucosal surface is smooth. The bladder lumen is moderately distended with anechoic urine. No masses, inflammatory changes or calculi are observed. Ureteral papillae and visualized portion of the proximal urethra, visible to a depth of 2.0 cm, are normal.

The left kidney presented normal size (3.60 cm in length); normal shape and architecture with smooth peripheral margins. There is a normal 1:3 cortex to medulla ratio with minimal loss of corticomedullary distinction. There is no evidence of pyelectasia, nephroliths, infarcts or hydroureter. Renal vasculature is normal.

The right kidney presented normal size (3.89 cm in length); normal shape and architecture with smooth peripheral margins. There is a normal 1:3 cortex to medulla ratio with minimal loss of corticomedullary distinction. There is no evidence of pyelectasia, nephroliths, infarcts or hydroureter. Renal vasculature is normal.

Adrenal Glands

The left adrenal gland is normal size (0.42 cm at cranial pole) (0.48 cm at caudal pole) (1.59 cm in length); normal shape; homogenous parenchyma. The glandular echogenicity and detail are unremarkable. Capsule, cortex, and medullary definition are normal. The phrenicoabdominal vein and surrounding vasculature are normal.

The right adrenal gland is normal size (0.33 cm at cranial pole) (0.41 cm at caudal pole) (1.56 cm in length); normal shape; homogenous parenchyma. The glandular echogenicity and detail are unremarkable. Capsule, cortex, and medullary definition are normal. The phrenicoabdominal vein and surrounding vasculature are normal.

Spleen

The spleen is normal in size (1.20 cm at the level of the hilus) with a normal capsular contour. There is appropriate echogenicity and echotexture. No focal lesions are observed. Splenic vasculature is normal.

Liver

The liver is subjectively normal in size with normal curvilinear peripheral contours. The parenchyma is hypoechoic relative to the spleen with minor changes consistent with age-related remodeling. No focal lesions are observed. Hepatic vasculature and biliary tracts are of normal volume with no evidence of congestion.

The gall bladder lumen is moderately distended. The wall is thin and smooth. Luminal contents are mostly anechoic. The cystic and common bile ducts are normal.



PATIENT

Scout Nakata

SPECIES

Canine

BREED

Coton De Tulear

SEX

Female

AGE

12 Years

WEIGHT

9 Lbs.

INTERPRETED BY

Andrea Nicastro, DMV,
Diplomate DACVIM
(Small Animal
Internal Medicine)

IMAGING PERFORMED BY

Saum Hadi

HOSPITAL NAME

Bethany Family PC

REFERRING VET

Dr. Saum Hadi

INVOICE

12707

DATE

11/28/21

Gastrointestinal

The stomach and intestine are free of stasis and exhibit normal peristaltic activity. The gastric lumen is mildly fluid distended. The gastric wall and pylorus are normal in thickness with a normal layering pattern. The small intestinal lumen is not dilated. The small intestinal wall thickness is normal (xxx cm) with a normal layering pattern and appropriate mural detail. Discreet masses are not identified. The colonic wall is normal. No obstructive or overt infiltrative disease is noted.

Pancreas

The left limb of the pancreas is visible with normal curvilinear peripheral contours. The parenchyma is largely isoechoic relative to surrounding omental fat and slightly mottled in appearance. The pancreatic duct is visible but not overtly dilated. There is no evidence of peripancreatic inflammation or effusion.

Free Abdomen

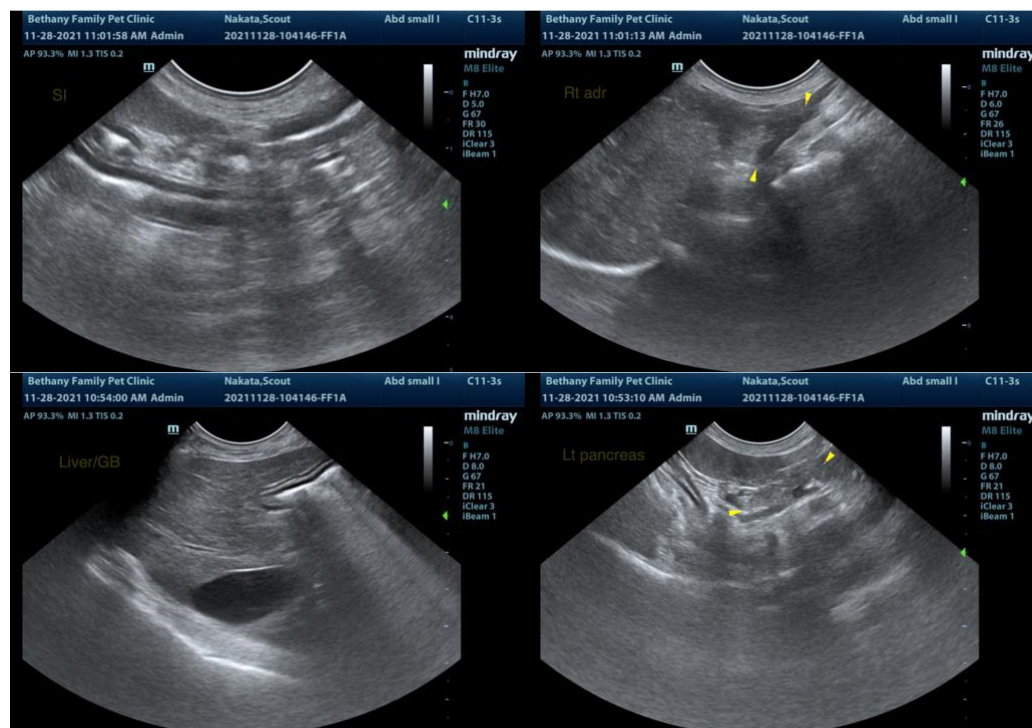
The peritoneal cavity is normal. There is no evidence of inflammation or effusion. The abdominal lymph nodes are normal/not visible.

ULTRASONOGRAPHIC FINDINGS

- Minor changes consistent with a geriatric abdomen.
- There is no obvious evidence of metastatic disease within the abdominal cavity.

INTERPRETATION OF THE FINDINGS & FURTHER RECOMMENDATIONS

- Three-view thoracic radiographs are recommended to complete the metastatic check.





PATIENT

Scout Nakata

SPECIES

Canine

BREED

Coton De Tulear

SEX

Female

AGE

12 Years

WEIGHT

9 Lbs.

INTERPRETED BY

Andrea Nicastro, DMV,
Diplomate DACVIM
(Small Animal
Internal Medicine)

**IMAGING
PERFORMED BY**

Saum Hadi

HOSPITAL NAME

Bethany Family PC

REFERRING VET

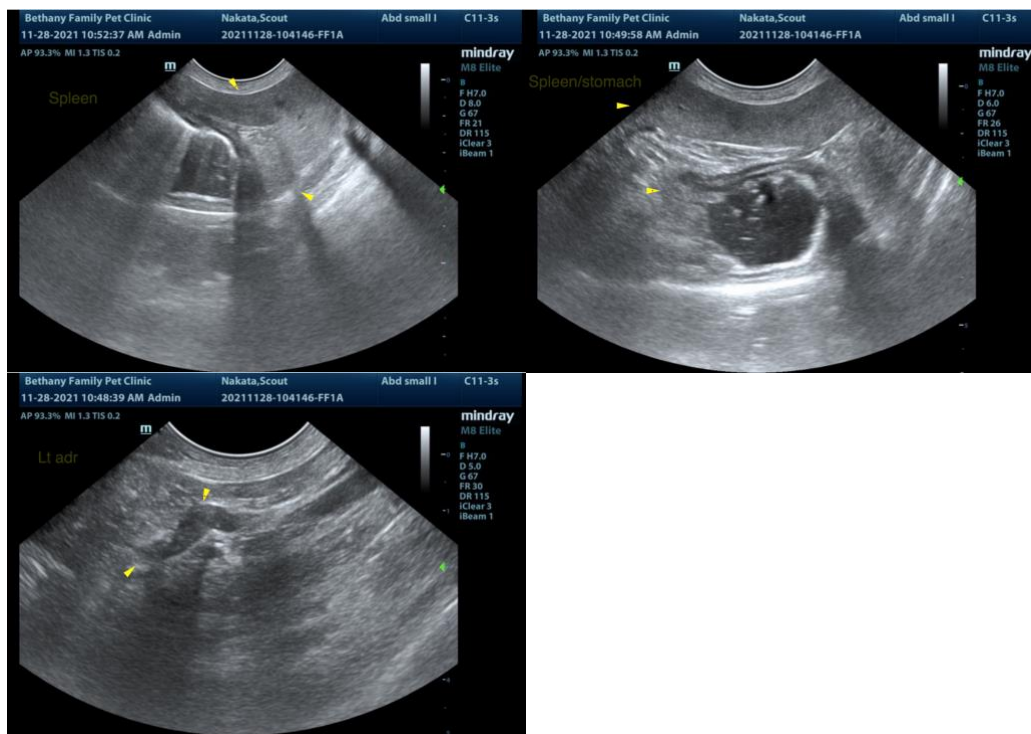
Dr. Saum Hadi

INVOICE

12707

DATE

11/28/21



The information and recommendations provided are based on the images presented by the referring veterinarian. No evaluation can be communicated regarding pathology that was not visible in the image/video clips provided.

Thank you for this referral. If the clinical or image interpretation does not parallel your findings or if I can be of any further assistance please contact me.

Andrea Nicastro, DVM, Diplomate DACVIM (Small Animal Internal Medicine)
info@SonoPath.com