



PATIENT

Spike Wabrick

SPECIES

Canine

BREED

Chihuahua

SEX

Male, neutered

AGE

5 Yrs.

WEIGHT

9.6 lbs.

INTERPRETED BY

Andrea Nicastro, DVM,
Diplomate ACVIM
(Small Animal Internal
Medicine)

IMAGING PERFORMED BY

Nicole Hession

HOSPITAL NAME

Atlantic Animal
Hospital Port Orange

REFERRING VET

Dr. DeBiasio

INVOICE

13380

DATE

11/25/25

PRESENTING CLINICAL SIGNS

History: Previous AUS 7/22/25- mineralized UB sediment, renal mineralization, adrenomegaly, hepatopathy, emerging GB mucocele, and hyperechoic remodeled pancreas. AUS today to recheck previous findings. P was tested for cushings and was in the grey zone. P was started on trilostane because he was clinical. O has discontinued giving trilostane and ursodiol. Abnormal PE/Chem/CBC/UA Results: BW 9/19/25- CBC: PLT 515 (120-412), otherwise NSF. Chem: Crea 0.4 (0.5-1.5), K 5.6 (4-5.4), Na:K ratio 26 (28-37), Cl 97 (108-119), Anion Gap 27 (11-26), ALT 140 (18-121), ALP 342 (5-160), GGT 46 (0-13), CHOL 770 (131-345), Creatine Kinase 410 (10-200). T4-normal. TBILI normal.

ULTRASONOGRAPHIC EXAMINATION OF THE ABDOMEN

Urinary System

The urinary bladder wall is normal in thickness and the mucosal surface is smooth. The bladder is moderately distended. A 0.18 cm cystic calculus is observed in the lumen along with a scant amount of echogenic debris. The region of the trigone and the visible portion of the proximal urethra are normal.

The prostate is normal in size (0.96 cm in width) with smooth peripheral contours. A 0.32 x 0.27 cm hyperechoic nodule is observed at the periphery on the left side. The remaining parenchyma is homogenous. The prostatic urethra appears normal without evidence of dilation or obstruction.

The left kidney is normal in size (4.09 cm in length) with a normal shape, smooth peripheral margins and normal internal architecture. There is mild loss of corticomedullary distinction. Several hyperechoic shadowing diverticular foci are observed. A few small non-obstructive mineralized foci are visualized. There is no evidence of pyelectasia, infarcts or hydroureter. Renal vasculature is normal.

The right kidney is normal in size (4.19 cm in length) with a normal shape, smooth peripheral margins and normal internal architecture. There is mild loss of corticomedullary distinction. Several hyperechoic shadowing diverticular foci are observed. At least one small cortical cyst is observed. Several small non-obstructive mineralized foci are visualized. There is no evidence of pyelectasia, infarcts or hydroureter. Renal vasculature is normal.

Adrenal Glands

The left adrenal gland is enlarged (0.82 cm at cranial pole) (1.02 cm at caudal pole) with swollen peripheral contours. A 0.15 cm hyperechoic focus is observed in the caudal pole. The remaining glandular echogenicity and detail are unremarkable. The phrenicoabdominal vein and surrounding vasculature are normal.

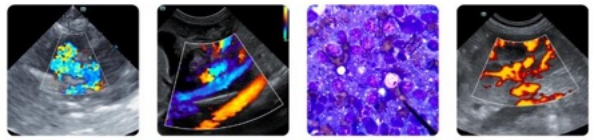
The right adrenal gland is enlarged (0.73 cm at cranial pole) (0.84 cm at caudal pole) with swollen peripheral contours. The glandular echogenicity and detail are unremarkable. The phrenicoabdominal vein and surrounding vasculature are normal.

Spleen

The spleen is normal in size (0.94 cm in width at the level of the hilus) with a normal capsular contour. There is appropriate echogenicity and echotexture. Pinpoint hyperechoic to mineralized foci are observed throughout the organ. Splenic vasculature is normal.

Liver

The liver is subjectively normal in size with normal contours and structure. There is appropriate echogenicity and echotexture. The liver is slightly hyperechoic relative to the spleen. No overt structural evidence of inflammatory, infiltrative, or regenerative pathology is evident. Vascular and biliary tracts are of normal volume with no evidence of congestion.



PATIENT

Spike Wabrick

SPECIES

Canine

BREED

Chihuahua

SEX

Male, neutered

AGE

5 Yrs.

WEIGHT

9.6 lbs.

INTERPRETED BY

Andrea Nicastro, DVM,
Diplomate ACVIM
(Small Animal Internal
Medicine)

IMAGING PERFORMED BY

Nicole Hession

HOSPITAL NAME

Atlantic Animal
Hospital Port Orange

REFERRING VET

Dr. DeBiasio

INVOICE 13380

DATE 11/25/25

The gall bladder lumen is moderately distended. The wall is thin and smooth. A moderate to large amount of aggregated, echogenic to mineralized suspended sludge in a partially stellate pattern is observed within the lumen. The cystic and common bile ducts are normal/not seen. The duodenal papilla is normal in size (0.22 cm in width).

Gastrointestinal

The gastric lumen is mildly to moderately distended with ingesta. The gastric wall and pylorus are normal in thickness with a normal layering pattern. The pyloric outflow tract is patent. The small intestinal lumen is segmentally dilated with chyme. The small intestinal wall is normal in thickness with a normal layering pattern and appropriate mural detail. Discreet masses are not identified. The ileocecolic junction and colonic wall are normal. The colonic lumen contains granular appearing fecal material. There is no obvious evidence of an obstructive pattern.

Pancreas

The right limb of the pancreas is visible with normal curvilinear peripheral contours. The parenchyma is largely hyperechoic relative to surrounding omental fat and heterogeneous in appearance. The pancreatic duct is visible but not overtly dilated. There is no evidence of peripancreatic inflammation or effusion.

Lymph nodes

The abdominal lymph nodes are normal/not visible.

Free Abdomen

There is no obvious evidence of free fluid.

ULTRASONOGRAPHIC FINDINGS

Primary Findings:

- The gallbladder changes are consistent with a developing mucocele.
- The diffuse hepatic changes are non-specific and could be consistent with vacuolar hepatopathy, regenerative nodular hyperplasia, and/or age-related remodeling. Inflammatory disease, infiltrative neoplasia and other hepatopathies are considered less likely.
- Bilateral adrenomegaly with a pinpoint hyperechoic focus in the caudal pole
- Tiny cystic calculus

Secondary Findings:

- The pancreatic changes are most consistent with age-related parenchymal remodeling, potentially secondary to a prior inflammatory episode, early fibrosis or chronic pancreatitis.
- Bilateral non-specific age-related renal changes with non-obstructive nephrocalcinosis and a right cortical cyst.
- Splenic dystrophic mineralization. This is typically a benign incidental finding often associated with endocrinopathies.

*Overall, today's ultrasound changes appear similar to the previous report.



PATIENT

Spike Wabrick

SPECIES

Canine

BREED

Chihuahua

SEX

Male, neutered

AGE

5 Yrs.

WEIGHT

9.6 lbs.

INTERPRETED BY

Andrea Nicastro, DVM,
Diplomate ACVIM
(Small Animal Internal
Medicine)

IMAGING PERFORMED BY

Nicole Hession

HOSPITAL NAME

Atlantic Animal
Hospital Port Orange

REFERRING VET

Dr. DeBiasio

INVOICE

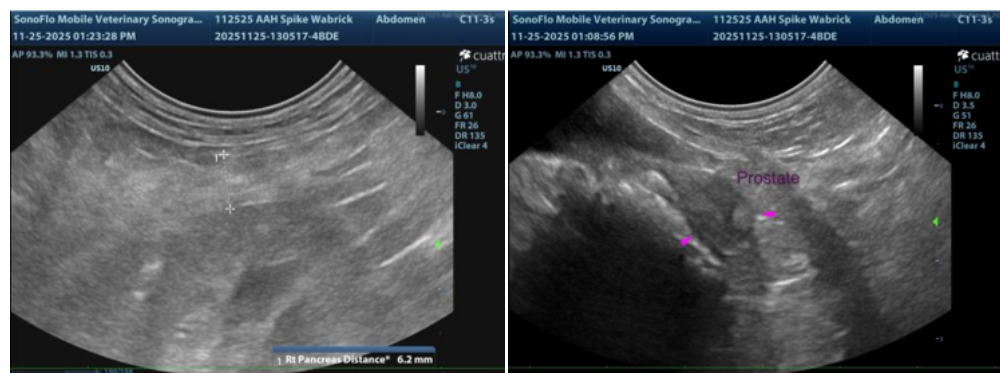
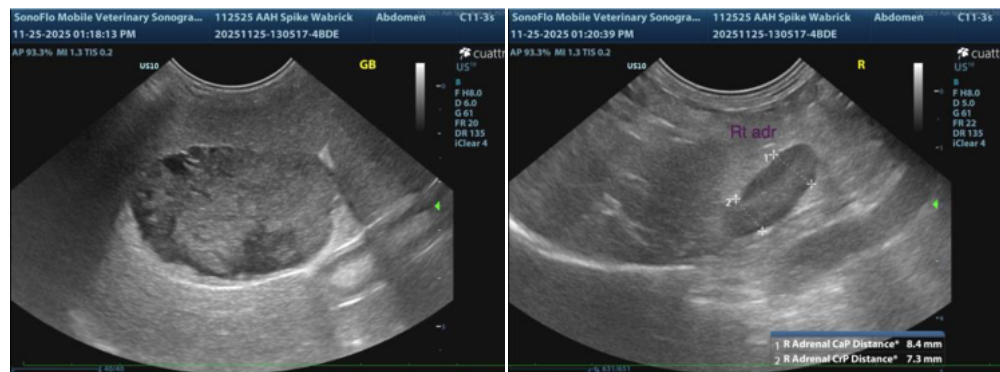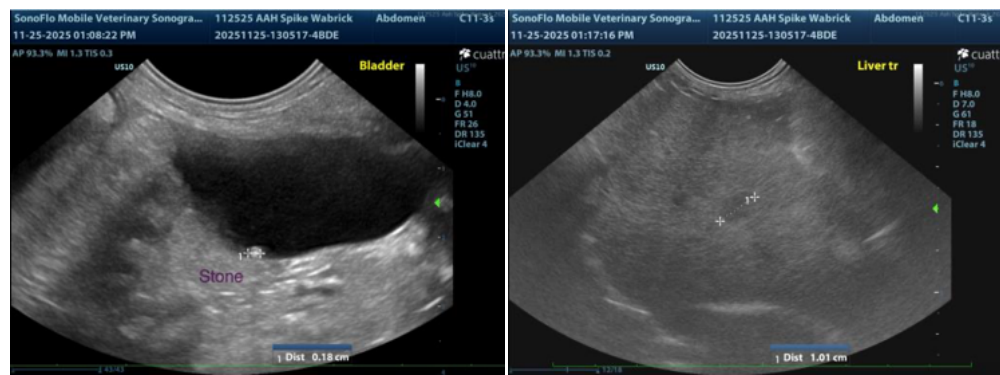
13380

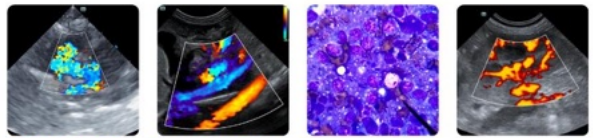
DATE

11/25/25

INTERPRETATION OF THE FINDINGS & FURTHER RECOMMENDATIONS

- Regarding the gallbladder changes, consider a prophylactic cholecystectomy with submission of the gallbladder for histopathology +/- bile cultures. Liver biopsies should also be obtained at the time of surgery. If surgery is not pursued, Ursodiol therapy should be re-initiated with close sonographic monitoring (i.e., every 4-6 weeks) to assess for progression of the mucocele. There is the risk of gallbladder rupture with subsequent bile peritonitis if the changes progress.
- Further recommendations should be based on the patient's clinical signs.
- Regarding the cystic calculus, consider cystotomy with stone removal, analysis and culture. Alternatively an attempt at medical dissolution can be considered.





PATIENT

Spike Wabrick

SPECIES

Canine

BREED

Chihuahua

SEX

Male, neutered

AGE

5 Yrs.

WEIGHT

9.6 lbs.

INTERPRETED BY

Andrea Nicastro, DVM,
Diplomate ACVIM
(Small Animal Internal
Medicine)

IMAGING PERFORMED BY

Nicole Hession

HOSPITAL NAME

Atlantic Animal
Hospital Port Orange

REFERRING VET

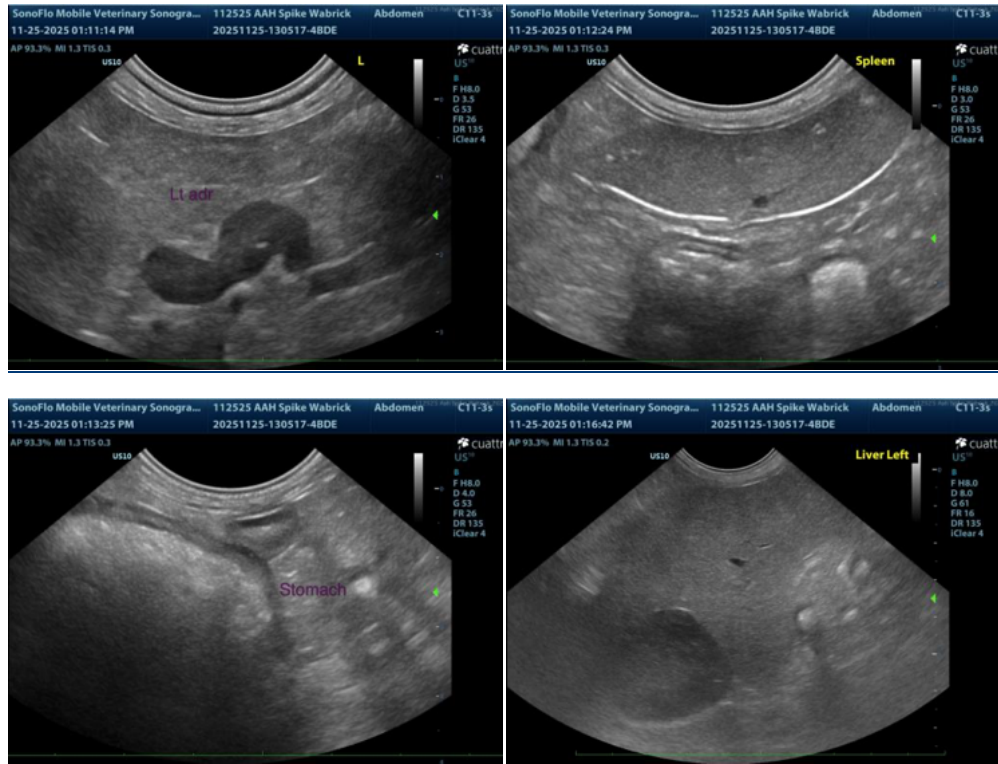
Dr. DeBiasio

INVOICE

13380

DATE

11/25/25



The information and recommendations provided are based on the images presented by the referring veterinarian/sonographer. No evaluation can be communicated regarding pathology that was not visible in the image/video clips provided.

Thank you for this referral. If the clinical or image interpretation does not parallel your findings or if I can be of any further assistance please contact me.

Andrea Nicastro, MPH, DVM, Diplomate DACVIM (Small Animal Internal Medicine)
info@SonoPath.com