



DATE PRESENTING CLINICAL SIGNS

11/24/25

Patient History: Vomiting multiple times daily for the past few weeks. Sometimes food, sometimes bile. No blood in vomitus. No diarrhea. Patient still eating/drinking. Past few days decreased activity levels but still BAR. No coughing/sneezing. O thinks patient is losing weight but has always been a petite cat.

PATIENT

Maxene Welzenbach

Current Medications: N/A.

Labwork Results: T4 normal, reported as: eosinophilia r/o hypersensitivity vs parasites vs endocrine vs other hypoalbuminemia r/o inflammatory vs IBD vs PLE vs PLN other

SPECIES

Date of Previous IntraPet Ultrasound: No previous.

Feline

Sedation: Not required to complete full diagnostic ultrasound.

Stat Report: Not requested.

BREED

Imaging Performed by: Stephanie Warga RDCS, RVT.

Domestic Shorthair

ULTRASONOGRAPHIC EXAMINATION OF THE ABDOMEN

SEX

Urinary System

Female, spayed

The urinary bladder wall is normal in thickness and the mucosal surface is smooth. The bladder is moderately distended. Luminal contents are anechoic. No cystic calculi are observed. The region of the trigone and the visible portion of the proximal urethra are normal.

AGE

4/16/2016

The left kidney is normal in size (3.45 cm in length) with a normal shape, architecture and smooth peripheral margins. There is a normal 1:3 cortex to medulla ratio with minimal to mild loss of corticomedullary distinction. There is no evidence of pyelectasia, nephroliths, infarcts or hydroureter. Renal vasculature is normal.

WEIGHT

10 lbs.

The right kidney is normal in size (3.65 cm in length) with a normal shape, architecture and smooth peripheral margins. There is a normal 1:3 cortex to medulla ratio with minimal to mild loss of corticomedullary distinction. There is no evidence of pyelectasia, nephroliths, infarcts or hydroureter. Renal vasculature is normal.

INTERPRETED BY

Adrenal Glands

The left adrenal gland is normal size (0.43 cm width). Normal shape and glandular echogenicity. The phrenicoabdominal vein and surrounding vasculature are normal.

The right adrenal gland is normal size (0.35 cm width). Normal shape and glandular echogenicity. The phrenicoabdominal vein and surrounding vasculature are normal.

Spleen

The spleen is normal in size (0.88 cm in width at the level of the hilus) with a normal capsular contour. There is appropriate echogenicity and echotexture. No focal lesions are observed. Splenic vasculature is normal.

Liver

The liver is subjectively normal in size with normal peripheral contours. The parenchyma is isoechoic relative to the spleen and homogeneous in appearance. Intrahepatic biliary stones are present. Vascular is of normal volume with no evidence of congestion.

The gall bladder lumen is moderately distended. The wall is normal in thickness. A bi-lobed confirmation is suspected. A small amount of gravity-dependent echogenic to mineralized debris/sand is observed within the lumen. The cystic and common bile ducts are tortuous and mildly dilated (up to 0.30 cm). A small amount of echogenic debris is observed within the lumen. The duodenal papilla is normal in size (0.23 cm in width).

INVOICE

13371

REFERRING VET

Dr. Pleasanton

HOSPITAL NAME

Warm and Fuzzy Vet

Andrea Nicastro, DVM,
Diplomate ACVIM
(Small Animal Internal
Medicine)

Gastrointestinal

The gastric lumen is not distended. The gastric wall and pylorus are normal in thickness with a normal layering pattern. The pyloric outflow tract is patent. The small intestinal lumen is not dilated. The small intestinal wall is diffusely thickened (up to 0.45 cm). There is disruption in the normal 1:3 muscularis: mucosal ratio with a >1:1 ratio in most segments. There is also a trend toward a loss of normal layering in some regions. Discreet masses are not identified. The ileocecolic junction and colonic wall are normal. There is no obvious evidence of an obstructive pattern.

Pancreas

The left limb of the pancreas is visible with normal curvilinear peripheral contours. The parenchyma is largely slightly hypoechoic relative to surrounding omental fat and slightly mottled in appearance. The pancreatic duct is visible but not overtly dilated. There is no evidence of peripancreatic inflammation or effusion.

Lymph nodes

A few prominent mesenteric lymph nodes are visualized, one measuring 2.75 x 0.45 cm.

Free Abdomen

There is no obvious evidence of free fluid.

ULTRASONOGRAPHIC FINDINGS

Primary Findings:

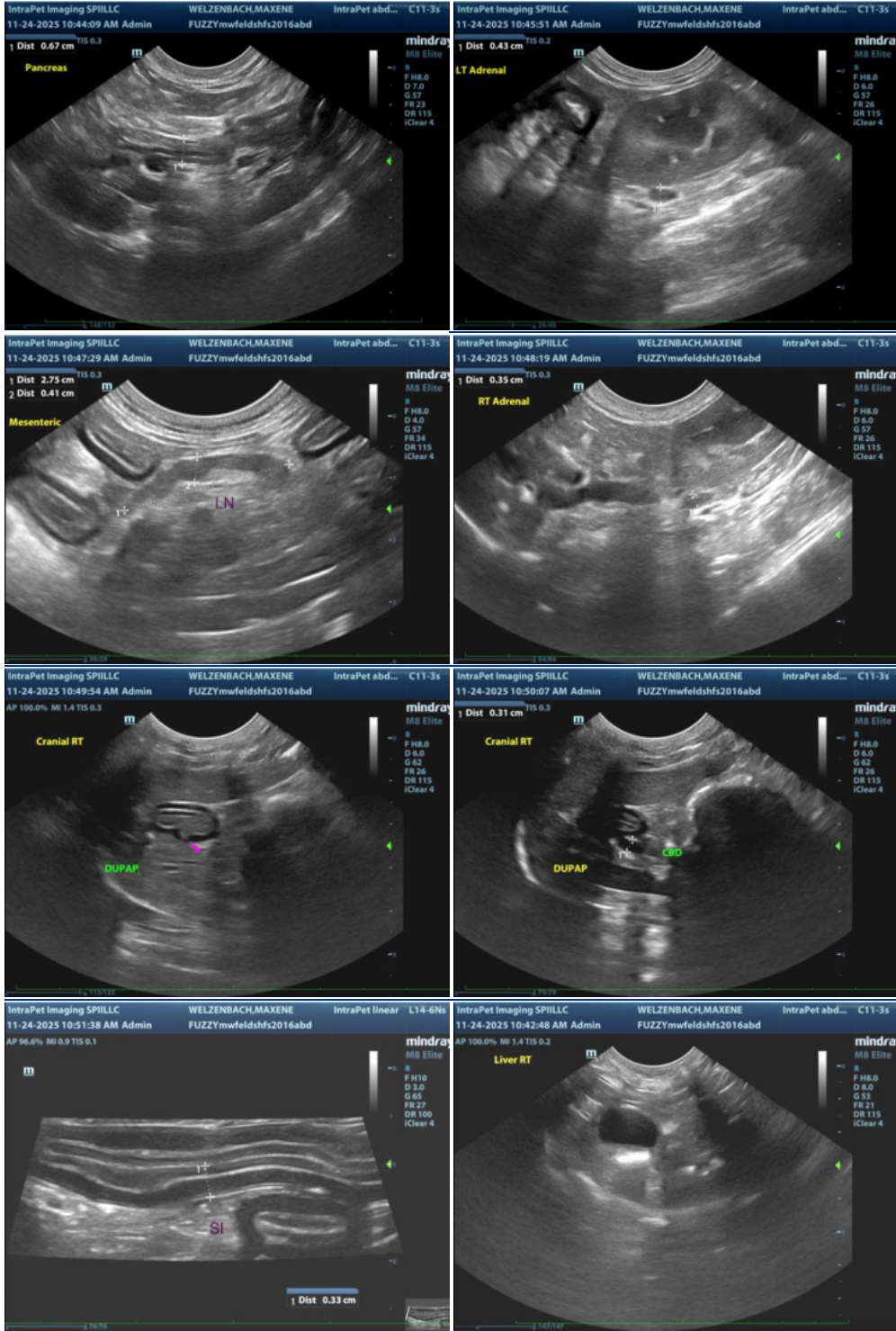
- The small intestinal wall changes could be consistent with emerging lymphoma or severe inflammatory bowel disease (i.e., lymphoplasmacytic, eosinophilic, other).
- The prominent abdominal lymph nodes could be consistent with reactive lymphadenitis, lymphoid hyperplasia, or emerging neoplasia (i.e., lymphoma).

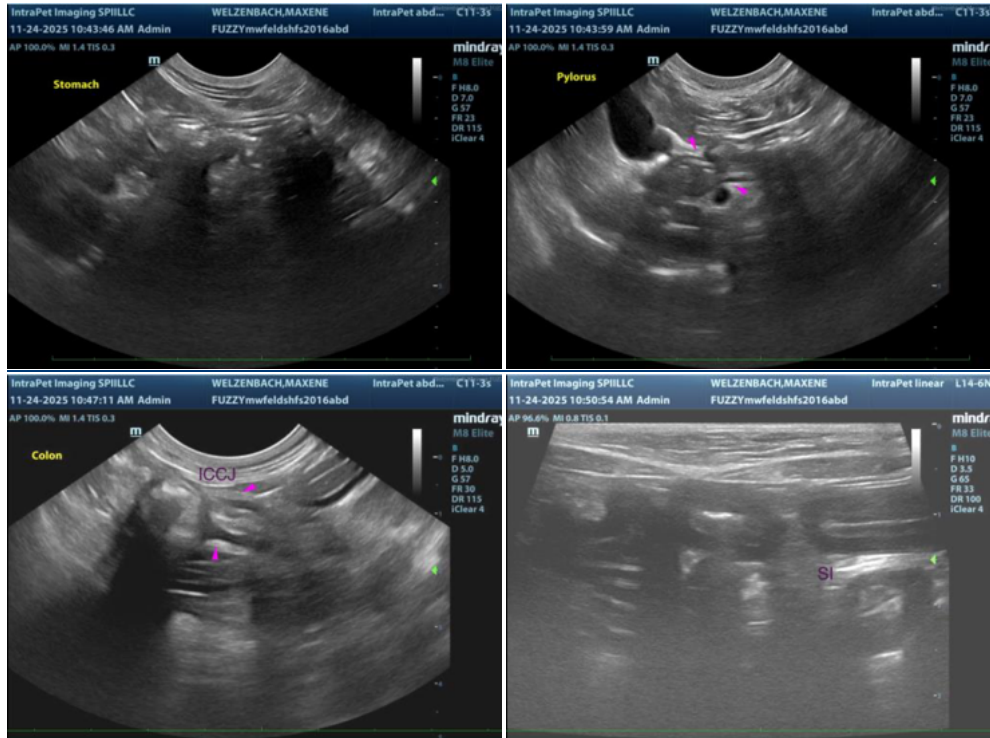
Secondary Findings:

- The pancreatic changes are most consistent with age-related parenchymal remodeling, potentially secondary to a prior inflammatory episode, early fibrosis or chronic pancreatitis.
- Intrahepatic biliary stones
- Gallbladder debris/sand, non-mucocele

INTERPRETATION OF THE FINDINGS & FURTHER RECOMMENDATIONS

A fecal evaluation for ova and Giardia is recommended to assess for internal parasites. A GI panel including serum cobalamin, folate, TLI and PLI is also recommended. Ultimately, GI biopsies would be necessary to get a definitive diagnosis. Surgical biopsies are preferred in that full thickness tissue sample can be obtained. Three-view thoracic radiographs are recommended prior to any anesthetic event.





The information and recommendations provided are based on the images presented by the referring veterinarian/sonographer. No evaluation can be communicated regarding pathology that was not visible in the image/video clips provided.

Thank you for this referral. If the clinical or image interpretation does not parallel your findings or if I can be of any further assistance please contact me.

Andrea Nicastro, MPH, DVM, Diplomate DACVIM (Small Animal Internal Medicine) info@SonoPath.com