

## PATIENT

Sable Allgood

## SPECIES

Canine

## BREED

Pomeranian

## SEX

Spayed Female

## AGE

14 years

## WEIGHT

11 lbs

## INTERPRETED BY

Andrea Nicastro,  
DVM, Diplomate  
ACVIM (Small Animal  
Internal Medicine)

## IMAGING PERFORMED BY

Loetitia Saint-Jacques,  
RVT LVT

## HOSPITAL NAME

Brighton Greens VH

## REFERRING VET

Dr Amber Murphy

## INVOICE

11906

## DATE

11.24.22

## PRESENTING CLINICAL SIGNS

History: Patient has increased liver enzymes and nRBCs on lab finding before dental. Would like to re-evaluate possible gall bladder mucocele before scheduling dental Denamarin and Ursodiol Meds

Abnormal PE/Chem/CBC/UA Results: BW: ALT 456, ALP 659, potassium 5.6 (<5.5), nRBCs 3, mild increase in eosinophils and monocytes, T4 < 0.5, UA USG 1.017, remainder NSF, previous lab work in 8/22: ALP 314, PSL 237, CPK 1306, pH 7.5

## ULTRASONOGRAPHIC EXAMINATION OF THE ABDOMEN

### Urinary System

The urinary bladder is moderately distended. In the region of the trigone/cystourethral junction, a 0.63 cm, irregular, focal mural thickening is visualized. The remaining urinary bladder wall is normal in thickness with a smooth mucosal surface. Luminal contents are anechoic. No cystic calculi are observed. The visible portion of the proximal urethra is normal.

The left kidney is normal size (3.76 cm in length) with a normal shape, smooth peripheral margins, and normal internal architecture. There is moderate loss of corticomedullary distinction. Several hyperechoic shadowing diverticular foci are observed. Pinpoint hyperechoic foci are observed within the cortex. A 0.38 cm cortical cyst is observed. Renal vasculature is normal.

The right kidney is normal size (3.99 cm in length); with a normal shape, smooth peripheral margins, and normal internal architecture. There is moderate loss of corticomedullary distinction. Several hyperechoic shadowing diverticular foci are observed. Pinpoint hyperechoic foci are observed within the cortex. A small cortical cyst is observed. Renal vasculature is normal.

### Adrenal Glands

The left adrenal gland is normal size (0.40 cm at cranial pole) (0.42 cm at caudal pole); normal shape; homogenous parenchyma. The glandular echogenicity and detail are unremarkable. Capsule, cortex, and medullary definition are normal. The phrenicoabdominal vein and surrounding vasculature are normal.

The right adrenal gland is normal size (0.74 cm at cranial pole) (0.44 cm at caudal pole) (2.07 cm in length); normal shape; homogenous parenchyma. The glandular echogenicity and detail are unremarkable. Capsule, cortex, and medullary definition are normal. The phrenicoabdominal vein and surrounding vasculature are normal.

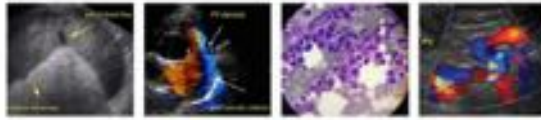
### Spleen

The spleen is normal in size (1.22 cm in width at the level of the hilus) with a normal capsular contour. There is appropriate echogenicity and echotexture. No focal lesions are observed. Splenic vasculature is normal.

### Liver

The liver is subjectively prominent in size with slightly swollen peripheral contours. The parenchyma is isoechoic relative to the spleen and heterogenous in appearance, with several ill-defined hypoechoic nodules/areas, the largest measuring 1.60 cm in diameter. Hepatic vasculature and intrahepatic biliary tracts are of normal volume with no evidence of congestion.

The gall bladder lumen is moderately distended. The wall is thin and smooth. A small to moderate amount of aggregated, echogenic, partially dependent to suspended debris/sludge is observed within the lumen. The cystic and common bile ducts are normal. The distal common bile duct measures 0.25 cm in diameter, where it enters into the duodenal papilla.



## PATIENT

Sable Allgood

## SPECIES

Canine

## BREED

Pomeranian

## SEX

Spayed Female

## AGE

14 years

## WEIGHT

11 lbs

## INTERPRETED BY

Andrea Nicastro,  
DVM, Diplomate  
ACVIM (Small Animal  
Internal Medicine)

## IMAGING PERFORMED BY

Loetitia Saint-Jacques,  
RVT LVT

## HOSPITAL NAME

Brighton Greens VH

## REFERRING VET

Dr Amber Murphy

## INVOICE

11906

## DATE

11.24.22

### **Gastrointestinal**

The stomach and intestine are free of stasis and exhibit normal peristaltic activity. The gastric lumen is not distended. The gastric wall and pylorus are normal in thickness with a normal layering pattern. The pyloric outflow tract is patent. The small intestinal lumen is not dilated. The small intestinal wall thickness is normal with a normal layering pattern and appropriate mural detail. Discreet masses are not identified. The colonic wall is normal. There is no evidence of an obstructive pattern.

### **Pancreas**

The right limb of the pancreas is visible with normal curvilinear peripheral contours. The parenchyma is largely hyperechoic relative to surrounding omental fat and slightly mottled in appearance. The pancreatic duct is visible but not overtly dilated. There is no evidence of peripancreatic inflammation or effusion.

### **Free Abdomen**

The peritoneal cavity is normal. There is no evidence of inflammation or effusion. The abdominal lymph nodes are normal/not visible.

### **Other**

A brief echocardiogram reveals no obvious evidence of pericardial.

## **ULTRASONOGRAPHIC FINDINGS**

### **Primary Findings**

- The gall bladder changes are similar to slightly improved compared to the previous sonogram. An early mucocele is suspected.
- Diffuse hepatopathy. The sonographic changes in conjunction with the patient's liver values are concerning for an underlying hepatopathy (i.e., inflammatory disease (i.e., bacterial cholangiohepatitis), chronic hepatitis), hepatotoxicosis (i.e., copper), Leptospirosis, or other hepatopathy.
- The urinary bladder wall lesion near the cystourethral junction appears slightly larger on today's scan, compared to the previous study. There is concern for the possibility of emerging neoplasia.

### **Secondary Findings**

- Age-related pancreatic remodeling with suspected fibrosis.
- Bilateral chronic age-related renal changes with dystrophic mineralization and cortical cysts

## **INTERPRETATION OF THE FINDINGS & FURTHER RECOMMENDATIONS**

- Regarding the hepatopathy, consider hepatic tissue sampling (i.e., fine-needle aspirate or biopsies (i.e., laparoscopic, or surgical)). If biopsies are pursued, copper quantitation along with aerobic and anaerobic bile cultures are recommended. If a more conservative approach is to be pursued, empirical treatment for bacterial cholangiohepatitis is recommended, including broad-spectrum antibiotics, hepatic antioxidants and symptomatic care, as needed.



**PATIENT**

Sable Allgood

- Also consider Leptospirosis testing (i.e., blood and urine PCR, serology), depending on the level of clinical suspicion for the disease.

**SPECIES**

Canine

- Regarding the urinary bladder lesion, consider a urine BRAF test to further evaluate for lower urinary tract neoplasia. Alternatively, if surgical liver biopsies are pursued, a biopsy of the bladder wall lesion can be considered.

**BREED**

Pomeranian

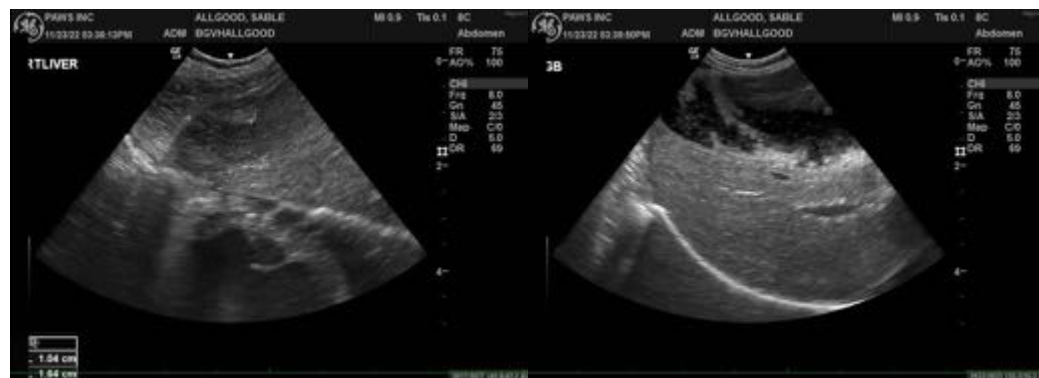
- If the patient is to undergo anesthesia, benzodiazepines should be avoided, and opioids used judiciously.

**SEX**

Spayed Female

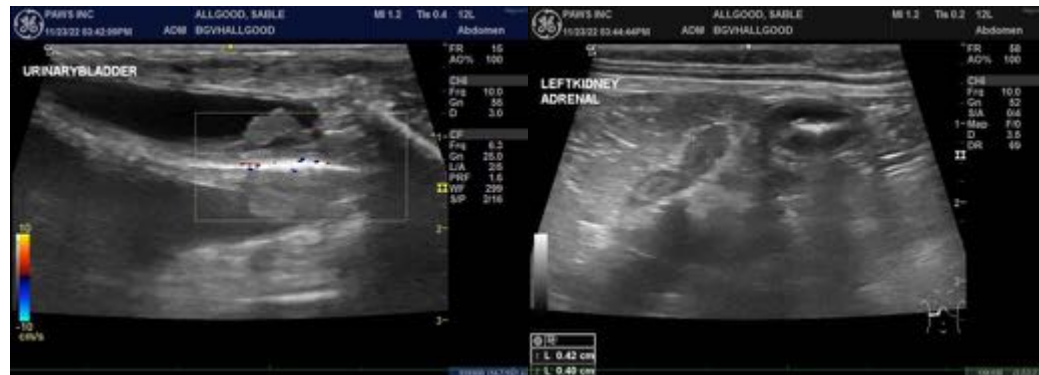**AGE**

14 years



**WEIGHT**

11 lbs



**INTERPRETED BY**

Andrea Nicastro,  
DVM, Diplomate  
ACVIM (Small Animal  
Internal Medicine)

**IMAGING**

**PERFORMED BY**

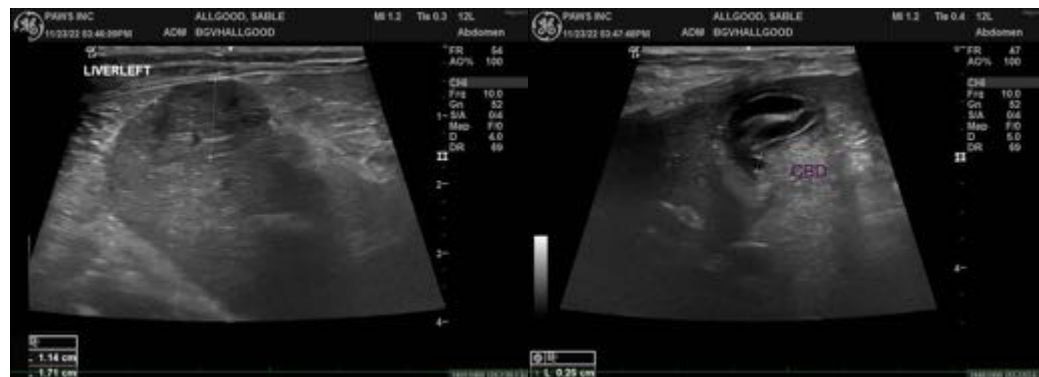
Loetitia Saint-Jacques,  
RVT LVT

**HOSPITAL NAME**

Brighton Greens VH

**REFERRING VET**

Dr Amber Murphy

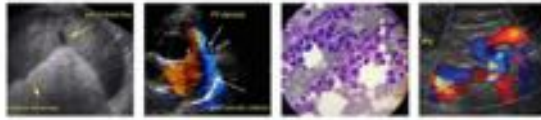


**INVOICE**

11906

**DATE**

11.24.22



**PATIENT**

Sable Allgood

**SPECIES**

Canine

**BREED**

Pomeranian

**SEX**

Spayed Female

**AGE**

14 years

**WEIGHT**

11 lbs

**INTERPRETED BY**

Andrea Nicastro,  
DVM, Diplomate  
ACVIM (Small Animal  
Internal Medicine)

**IMAGING  
PERFORMED BY**

Loetitia Saint-Jacques,  
RVT LVT

**HOSPITAL NAME**

Brighton Greens VH

**REFERRING VET**

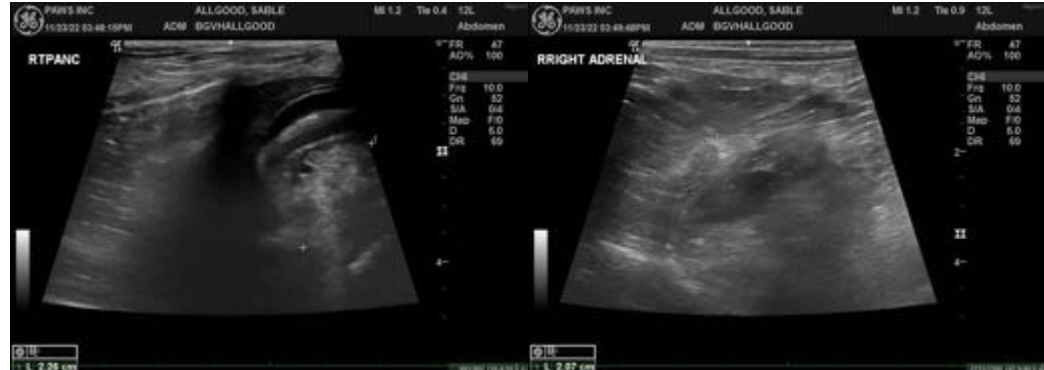Dr Amber Murphy

**INVOICE**

11906

**DATE**

11.24.22



The information and recommendations provided are based on the images presented by the referring veterinarian/sonographer. No evaluation can be communicated regarding pathology that was not visible in the image/video clips provided.

Thank you for this referral. If the clinical or image interpretation does not parallel your findings or if I can be of any further assistance, please contact me.

Andrea Nicastro, MPH, DVM, Diplomate DACVIM (Small Animal Internal Medicine)  
[info@SonoPath.com](mailto:info@SonoPath.com)