**PATIENT**

Jackson Converse

PRESENTING CLINICAL SIGNS

Abnormal PE/Chem/CBC/UA Results: See attached bloodwork
ALT 337

SPECIES

Feline

ULTRASONOGRAPHIC EXAMINATION OF THE ABDOMEN**BREED**

DMH

Urinary System

The urinary bladder, trigone, and pelvic urethra are normal in thickness and the mucosal surface is smooth. The bladder lumen is moderately distended with mostly anechoic urine. No masses, inflammatory changes or calculi are observed. Ureteral papillae and visualized portion of the proximal urethra, visible to a depth of 1-2 cm, are normal.

SEX

Neutered Male

The left kidney is normal size (3.93 cm in length); normal shape and architecture with smooth peripheral margins. There is a normal 1:3 cortex to medulla ratio with mild loss of corticomedullary distinction. There is no evidence of pyelectasia, nephroliths, infarcts or hydroureter.

AGE

11 years

The right kidney is normal size (4.28 cm in length); normal shape and architecture with smooth peripheral margins. There is a normal 1:3 cortex to medulla ratio with normal corticomedullary distinction. There is no evidence of pyelectasia, nephroliths, infarcts or hydroureter. Renal vasculature is normal.

WEIGHT

17.9 lbs

Adrenal Glands

The left adrenal gland is normal size (0.36 cm width). Normal shape and glandular echogenicity. The phrenicoabdominal vein and surrounding vasculature are normal.

The right adrenal gland is normal size (0.38 cm width). Normal shape and glandular echogenicity. The phrenicoabdominal vein and surrounding vasculature are normal.

INTERPRETED BY

Andrea Nicastro,
DVM, Diplomate
ACVIM (Small Animal
Internal Medicine)

Spleen

The spleen is normal in size (0.96 cm in width at the level of the hilus) with a normal capsular contour. There is appropriate echogenicity and echotexture. No focal lesions are observed. Splenic vasculature is normal.

IMAGING PERFORMED BY

Amy Mayhew LVT

Liver

The liver is subjectively normal in size with normal contours and structure. There is appropriate echogenicity and echotexture. No overt structural evidence of inflammatory, infiltrative, or regenerative pathology is evident. Vascular and biliary tracts are of normal volume with no evidence of congestion. No pathological hepatic lymphadenopathy observed.

HOSPITAL NAME

SVS Imaging Michigan

The gall bladder lumen is moderately distended. The wall is thin and smooth. Luminal contents are anechoic. The cystic and common bile ducts are normal/not seen.

Gastrointestinal

The stomach and intestine are free of stasis and exhibit normal peristaltic activity. The gastric lumen is not distended. The gastric wall and pylorus are normal in thickness with a normal layering pattern. The pyloric outflow tract is patent. The small intestinal lumen is not dilated. The small intestinal wall is normal to mildly thickened (up to 0.34 cm), with a normal layering pattern and appropriate mural detail. There is disruption in the normal 1:3 muscularis: mucosal ratio in some segments. Discreet masses are not identified. The ileocecal colic junction and colonic wall are normal. No obstructive disease is noted.

REFERRING VET

Pinecrest AH

INVOICE

11895

Pancreas

The region of the pancreas is isoechoic relative to surrounding omental fat. No obvious parenchymal abnormalities are observed. There is no evidence of regional inflammation or effusion.

DATE

11.25.22



PATIENT

Jackson Converse

Free Abdomen

There is no evidence of free fluid. One to two lymph nodes are visualized at the ileocecolic junction, the largest measuring 0.38 cm in length. Surrounding mesentery is mildly hyperechoic.

SPECIES

Feline

ULTRASONOGRAPHIC FINDINGS

Primary Findings

- The bowel pattern is suggestive of inflammatory bowel disease.
- The visible colic lymph nodes are most likely reactive.

BREED

DMH

*An obvious cause for the patient's elevated ALT is not definitively identified in this study. Considerations include inflammatory hepatopathy (i.e., bacterial cholangiohepatitis, lymphoplasmacytic hepatitis, emerging hepatic lipidosis, reactive hepatopathy, infiltrative neoplasia (less likely)), other.

SEX

Neutered Male

INTERPRETATION OF THE FINDINGS & FURTHER RECOMMENDATIONS

- Consider three-view thoracic radiographs to assess for occult esophageal disease.
- Also consider heartworm testing (i.e., antigen and antibody), as heartworm disease can be associated with chronic vomiting in cats.
- A malabsorption panel, including serum cobalamin and folate, TLI and PLI is recommended, along with a fecal evaluation for ova and Giardia.
- Consider transitioning to a hydrolyzed protein or limited antigen diet, if the patient will tolerate it. Also consider supplementation with a probiotic.
- Ultimately, GI biopsies may be necessary to get a definitive diagnosis. Hepatic tissue sampling (i.e., aspirate or biopsy) should also be considered to evaluate for an underlying hepatopathy.

AGE

11 years

WEIGHT

17.9 lbs

INTERPRETED BY

Andrea Nicastro, DVM, Diplomate ACVIM (Small Animal Internal Medicine)

IMAGING PERFORMED BY

Amy Mayhew LVT

HOSPITAL NAME

SVS Imaging Michigan

REFERRING VET

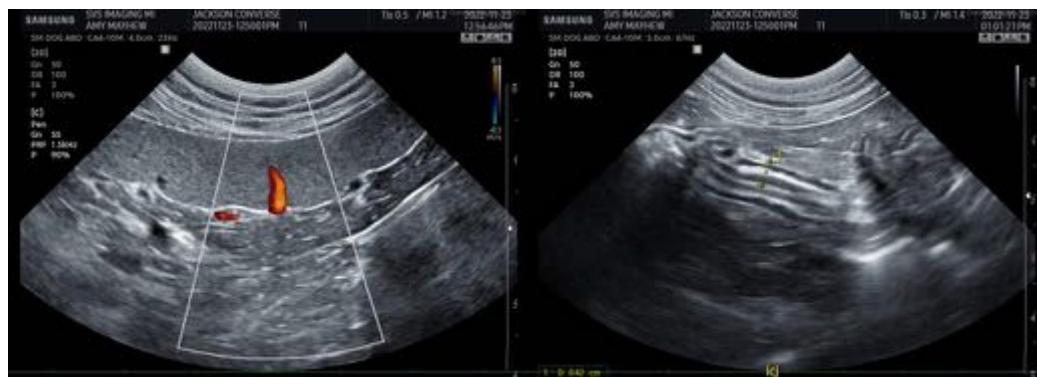Pinecrest AH

INVOICE

11895

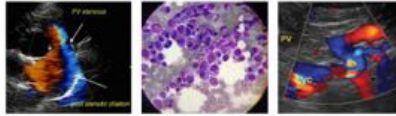
DATE

11.25.22



IMAGING PERFORMED BY

svsimagingqc.net 309-737-3070



Clinical Sonography & Telecytology

EDUCATIONAL TELECONSULTATION SERVICES™

1-800-838-4268 info@sonopath.com SonoPath.com

PATIENT

Jackson Converse

SPECIES

Feline

BREED

DMH

SEX

Neutered Male

AGE

11 years

WEIGHT

17.9 lbs

INTERPRETED BY

Andrea Nicastro,
DVM, Diplomate
ACVIM (Small Animal
Internal Medicine)

**IMAGING
PERFORMED BY**

Amy Mayhew LVT

HOSPITAL NAME

SVS Imaging Michigan

REFERRING VET

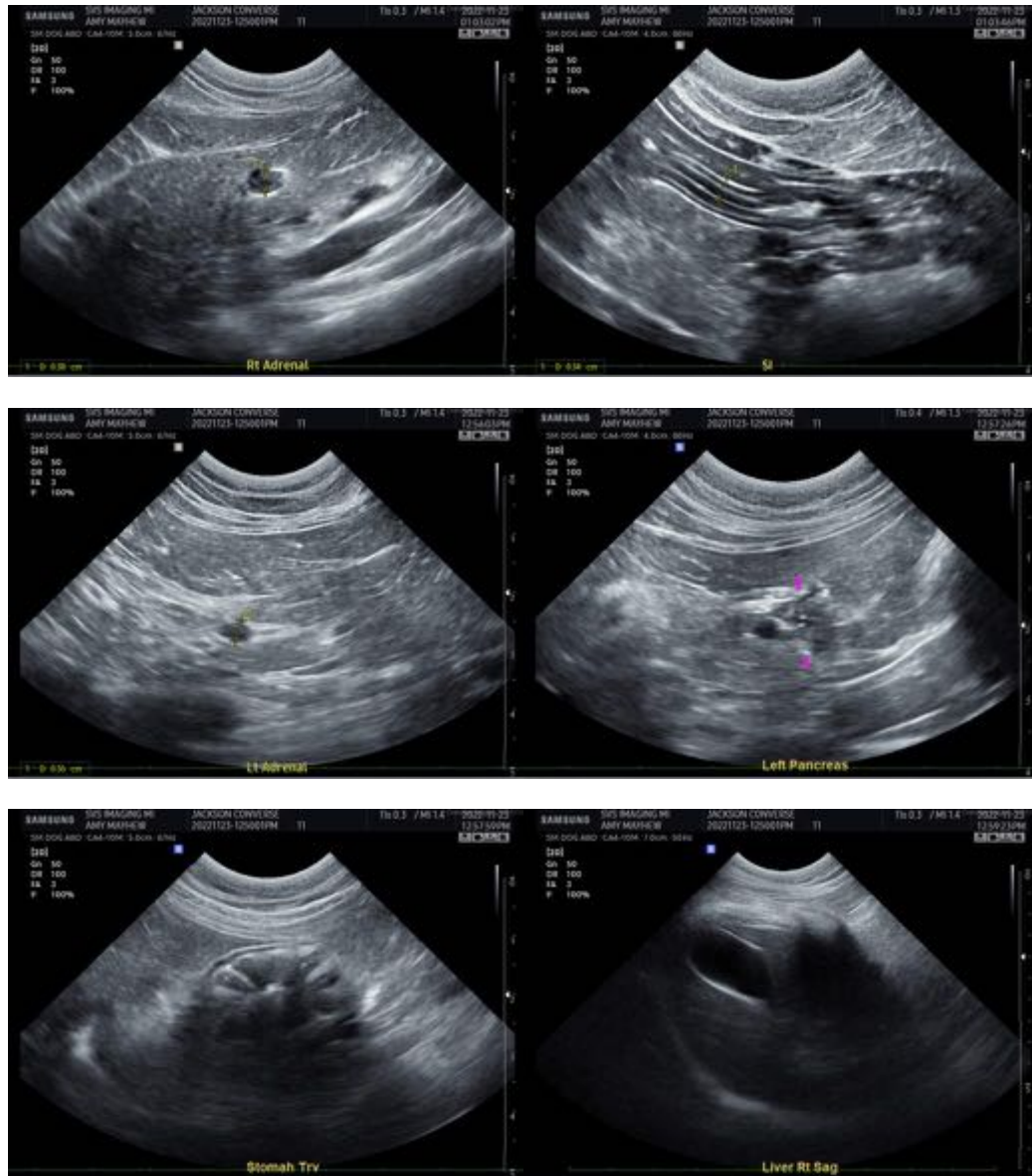
Pinecrest AH

INVOICE

11895

DATE

11.25.22



The information and recommendations provided are based on the images presented by the referring veterinarian/sonographer. No evaluation can be communicated regarding pathology that was not visible in the image/video clips provided.

Thank you for this referral. If the clinical or image interpretation does not parallel your findings or if I can be of any further assistance, please contact me.

Andrea Nicastro, MPH, DVM, Diplomate DACVIM (Small Animal Internal Medicine)
info@SonoPath.com