

**DATE PRESENTING CLINICAL SIGNS**

11.23.2022

Patient presented on 11/15 for vomiting and diarrhea. Has always had mixed bowel movements -- sometimes firm, usually half and half. Lately, stools have been starting firm then going to splattering liquid. Vomited three times this morning; was retching during bowels movements. Has been vomiting on and off for a few weeks. Indoor cat but will sometimes vomit up something tracked in from outside. An ultrasound in 2019 demonstrated mild intestinal thickening. On exam, she was under-weight with a BCS of 2/5. Copious exudate was present AU. Moderate dental tartar. Resistant to hip extension bilaterally.

PATIENT

Delilah Haymann

SPECIES

Feline

Current Medications: Had been on Royal Canin duck diet, probiotics long-term. On 11/15: Received 3 mg Cerenia injection on 11/15

BREED

Rx) Provable Kit -- 1 ml PO TID x 3 days; 1 cap on food SID

DSH

Rx) Gabapentin 100 mg/ml -- 1 ml PO the night before and again two hours prior to vet visits #4 syringes
 Lab Results: CBC: WNL. Chem: Decreased K+ 3.2 mmol/L, T4: 2.9 ug/dL
 Spec fPL: WNL. U/A: SG = 1.038.

SEX

Spayed Female

Date of Previous IntraPet Ultrasound: No previous.

Sedation: Not required to complete full diagnostic ultrasound.

Stat Report: Declined.

Imaging Performed By: Rachel Brillhart, RDMS.

AGE

11/3/2008

ULTRASONOGRAPHIC EXAMINATION OF THE ABDOMEN**WEIGHT**

6.6 lbs

Urinary System

The urinary bladder, trigone, and pelvic urethra are normal in thickness and the mucosal surface is smooth. The bladder is moderately distended. A scant amount of echogenic debris is suspended within the lumen. No masses, inflammatory changes or calculi are observed. The region of the trigone and visible portion of the proximal urethra are normal.

INTERPRETED BY

Andrea Nicastro,
 DMV, Diplomate
 DACVIM (Small
 Animal
 Internal Medicine)

The left kidney is normal size (3.33 cm in length); a normal shape, smooth peripheral margins, and normal internal architecture. There is mild to moderate loss of corticomedullary distinction. Several hyperechoic shadowing diverticular foci are observed. There is no evidence of pyelectasia, infarcts or hydronephrosis. Renal vasculature is normal.

HOSPITAL NAME

Paradise AH

The right kidney is normal size (3.47 cm in length); a normal shape, smooth peripheral margins, and normal internal architecture. There is mild to moderate loss of corticomedullary distinction. Several hyperechoic shadowing diverticular foci are observed. There is no evidence of pyelectasia, infarcts or hydronephrosis. Renal vasculature is normal.

REFERRING VET

Dr. Twardzik

Adrenal Glands

The left adrenal gland is normal size (0.25 cm width). Normal shape and glandular echogenicity. The phrenicoabdominal vein and surrounding vasculature are normal.

INVOICE

11898

What is thought to be the right adrenal gland is enlarged (1.16 cm length; 0.96 cm width), with a rounded shape and homogenous parenchyma. No distinct focal lesions are observed. Surrounding vasculature appears normal.

Spleen

The spleen is normal in size (0.66 cm in width at the level of the hilus) with a normal capsular contour. There is appropriate echogenicity and echotexture. No focal lesions are observed. Splenic vasculature is normal.

Liver

The liver is subjectively normal in size with normal contours and structure. There is appropriate echogenicity and echotexture. No overt structural evidence of inflammatory, infiltrative, or regenerative pathology is evident. Vascular and biliary tracts are of normal volume with no evidence of congestion. No pathological hepatic lymphadenopathy observed.

The gall bladder is of normal contours and contains some dependent echogenic debris. The wall is normal in thickness. No choleliths are observed. The cystic and common bile ducts are normal/not seen.

Gastrointestinal

The gastric lumen is not distended. The gastric wall and pylorus are normal in thickness with a normal layering pattern. The small intestinal lumen is not dilated. The small intestinal wall is normal to moderately thickened (up to 0.41 cm). There is disruption in the normal 1:3 muscularis: mucosal ratio in most segments. An approximately 2.00 to 2.50 cm irregular mass effect is observed at the ileocecolic junction. The mass is preferentially infiltrating the cecum. The wall in this region is hypoechoic with complete loss of the normal layering pattern. The mesentery effacing the serosal surface is hyperechoic. The remaining colonic wall is normal in thickness with a normal layering pattern. There is no obvious evidence of an obstructive pattern.

Pancreas

The left limb is prominent in size with minimal deviation from the normal peripheral contours. The parenchyma is slightly hypoechoic relative to surrounding omental fat and subtly mottled in appearance. The pancreatic duct is not overtly dilated. No distinct focal lesions are observed.

Free Abdomen

There is no obvious evidence of free fluid. Several, enlarged, irregular, hypoechoic to slightly cystic lymph nodes are observed at the ileocecolic junction and mesenteric roots. Surrounding mesentery is hyperechoic.

ULTRASONOGRAPHIC FINDINGS

Primary Findings

- Cecal/ileocecolic junction mass effect. Neoplasia (i.e., lymphoma, adenocarcinoma) is suspected, with a lower possibility of a severe inflammatory process. Adjacent peritonitis is present.
- The lymphadenopathy may be secondary to infiltrative neoplasia or reactive change.

Secondary Findings

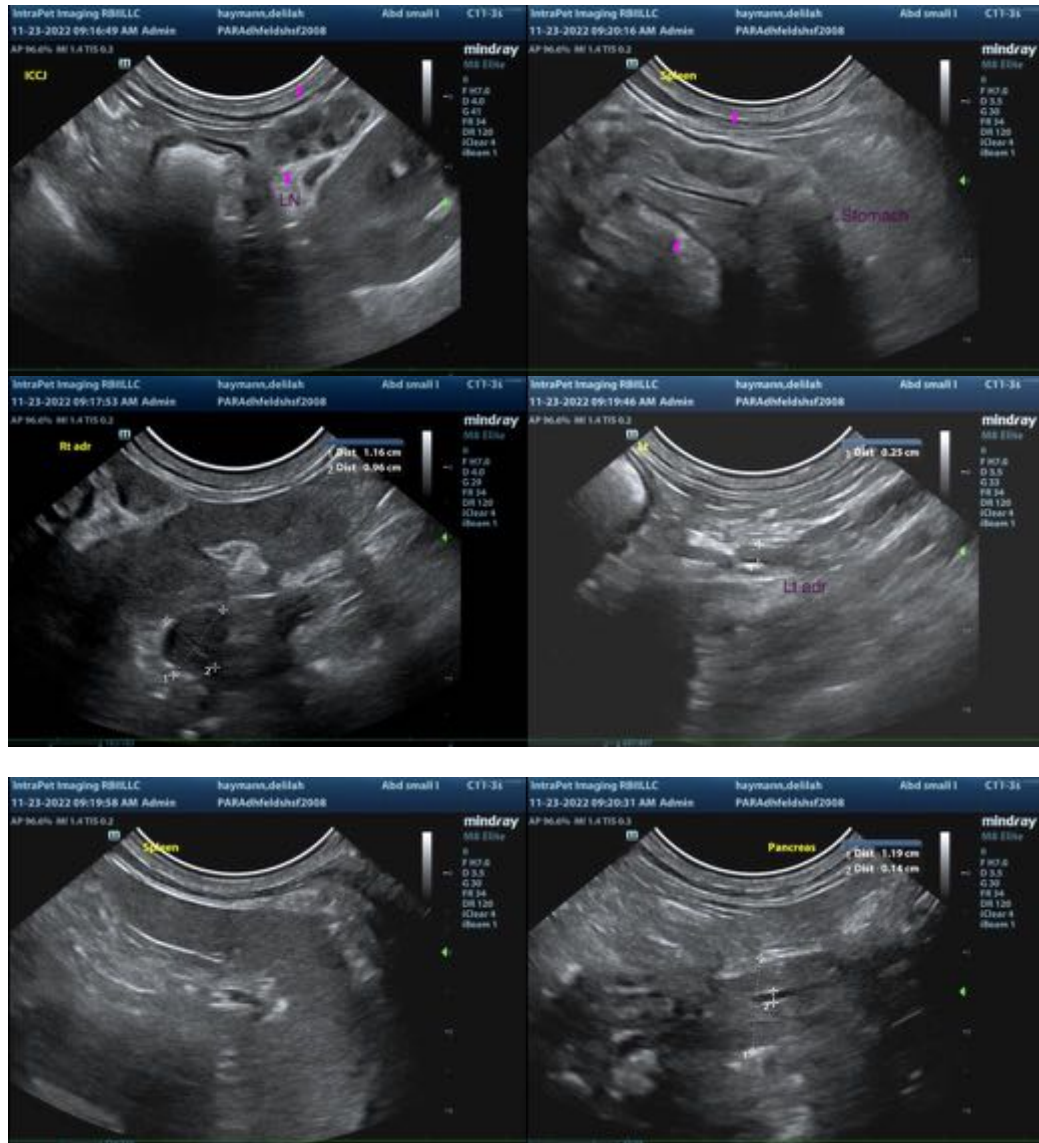
- Bilateral degenerative renal changes with dystrophic mineralization
- The pancreatic changes are suggestive of age-related remodeling +/- mild chronic pancreatitis.
- The suspected right adrenomegaly may be secondary to hyperplasia, emerging neoplasia, or stress.

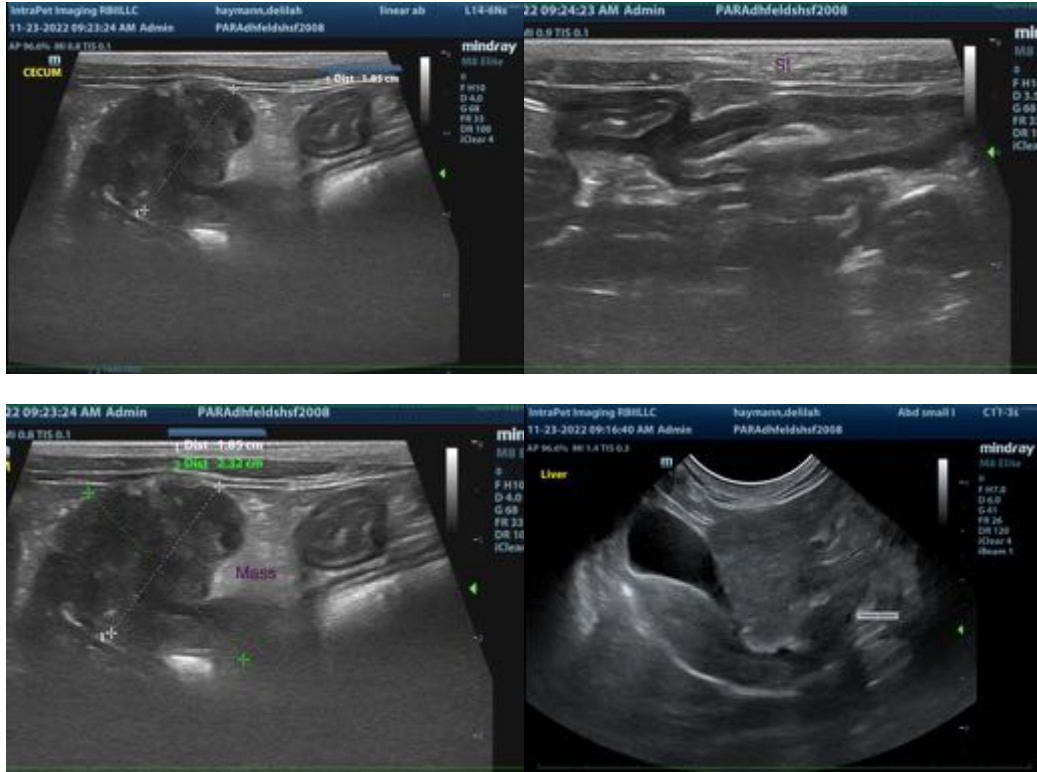INTERPRETATION OF THE FINDINGS & FURTHER RECOMMENDATIONS

- Three-view thoracic radiographs are recommended to assess for pulmonary metastases.
- Fine-needle aspirates of the bowel mass +/- enlarged abdominal lymph nodes is recommended if clotting status is appropriate. A 25-gauge needle should be used. If cytology results are

inconclusive, more advanced testing (i.e., flow cytometry, PARR or biopsy) may be necessary to get a definitive diagnosis.

- A GI panel including serum cobalamin and folate, TLI and PLI is also recommended to assess for maldigestion/malabsorption.





The information and recommendations provided are based on the images presented by the referring veterinarian/sonographer. No evaluation can be communicated regarding pathology that was not visible in the image/video clips provided.

Thank you for this referral. If the clinical or image interpretation does not parallel your findings or if I can be of any further assistance, please contact me.

Andrea Nicastro, DVM, Diplomate DACVIM (Small Animal Internal Medicine)
info@SonoPath.com