



PATIENT PRESENTING CLINICAL SIGNS

Shotzie Helias
History: Pet has a 7 day history of anorexia, hematochezia and vomiting.
Abnormal PE/Chem/CBC/UA Results: CBC/Chem/electrolytes: no significant findings.

SPECIES ULTRASONOGRAPHIC EXAMINATION OF THE ABDOMEN

Canine
Urinary System

The urinary bladder and visible portion of the pelvic urethra are normal for the degree of luminal distension. The urine is anechoic with no evidence of debris. Cystic calculi and discrete masses are not observed. The region of the trigone and the visible portion of the proximal urethra are normal.

BREED

Terrier

The left kidney is normal size (6.08 cm in length); normal shape and architecture with smooth peripheral margins. There is a normal 1:3 cortex to medulla ratio with minimal to mild loss of corticomedullary distinction. There is no evidence of pyelectasia, nephroliths, infarcts or hydroureter. Renal vasculature is normal.

SEX

Female, spayed

The right kidney is normal size (5.90 cm in length); normal shape and architecture with smooth peripheral margins. There is a normal 1:3 cortex to medulla ratio with minimal loss corticomedullary distinction. There is no evidence of pyelectasia, nephroliths, infarcts or hydroureter. Renal vasculature is normal.

AGE

10 Yrs.

Adrenal Glands

WEIGHT

54 lbs.

The left adrenal gland is normal size (0.46 cm at cranial pole) (0.55 cm at caudal pole) (2.26 cm in length); normal shape; homogenous parenchyma. The glandular echogenicity and detail are unremarkable. Capsule, cortex, and medullary definition are normal. The phrenicoabdominal vein and surrounding vasculature are normal.

INTERPRETED BY

Andrea Nicastro, DVM,
Diplomate ACVIM
(*Small Animal Internal
Medicine*)

The right adrenal gland is normal size (0.79 cm at cranial pole) (0.61 cm at caudal pole) (1.97 cm in length); normal shape; homogenous parenchyma. The glandular echogenicity and detail are unremarkable. Capsule, cortex, and medullary definition are normal. The phrenicoabdominal vein and surrounding vasculature are normal.

Spleen

IMAGING PERFORMED BY

Dr. Sheldon

The spleen is subjectively normal in size with a normal capsular contour. There is appropriate echogenicity and echotexture. No focal lesions are observed. Splenic vasculature is normal.

Liver

HOSPITAL NAME

Advanced PetCare of
Oakland

The liver is subjectively normal in size with normal contours and structure. There is appropriate echogenicity and echotexture. No overt structural evidence of inflammatory, infiltrative or regenerative pathology is evident. Vascular and biliary tracts are of normal volume with no evidence of congestion. No pathological hepatic lymphadenopathy observed. The gallbladder is of normal contours and contains some dependent echogenic debris. The wall is normal in thickness. No choleliths are observed. The cystic and common bile ducts are normal.

REFERRING VET

Dr. Sheldon

Gastrointestinal

INVOICE

14240

The gastric lumen is mildly distended with ingesta. The gastric wall is normal in thickness with a normal layering pattern. The small intestinal lumen is segmentally dilated with chyme. A 5-6 cm segment of small intestine is thickened (up to 0.47 cm) with loss of the normal layering pattern. The mesentery effacing the serosal surface in this region is hyperechoic. The remaining small intestinal segments are

DATE

11/21/22



PATIENT

normal in thickness with a normal layering pattern and appropriate mural detail. The colonic wall is normal. No obvious obstructive disease is noted.

Shotzie Helias

Pancreas

SPECIES

The region of the pancreas is isoechoic relative to surrounding omental fat. No obvious parenchymal abnormalities are observed. There is no evidence of regional inflammation or effusion.

Canine

BREED

Free Abdomen

Terrier

There is no evidence of free fluid. A 1.73 cm left medial iliac lymph node is visualized. The node is normal in shape and echogenicity. A 1.83 cm cranial abdominal lymph node is also visualized.

SEX

ULTRASONOGRAPHIC FINDINGS

Female, spayed

Primary Findings:

AGE

- The thickened small intestinal segment with loss of layering is most concerning for infiltrative neoplasia (i.e., lymphoma, adenocarcinoma) with a lower possibility of a severe inflammatory process. Adjacent peritonitis is present.
- The prominent abdominal lymph nodes are most consistent with reactive lymphadenitis or lymphoid hyperplasia. Neoplastic infiltration is considered less likely.

10 Yrs.

WEIGHT

54 lbs.

Secondary Findings:

- Minor, bilateral age-related renal changes.

INTERPRETED BY

INTERPRETATION OF THE FINDINGS & FURTHER RECOMMENDATIONS

Andrea Nicastro, DVM,
Diplomate ACVIM
(Small Animal Internal
Medicine)

- Three-view thoracic radiographs are recommended to assess for pulmonary metastases.
- A fine needle aspirate of the bowel wall can be considered (if clotting status is appropriate and if the segment is accessible). If results are inconclusive or if the bowel segment is not accessible, consider surgical biopsies to get a definitive diagnosis.
- Also consider a GI panel including serum cobalamin, folate, TLI and PLI to assess for maldigestion/malabsorption.

IMAGING PERFORMED BY

Dr. Sheldon

HOSPITAL NAME

Advanced PetCare of
Oakland

REFERRING VET

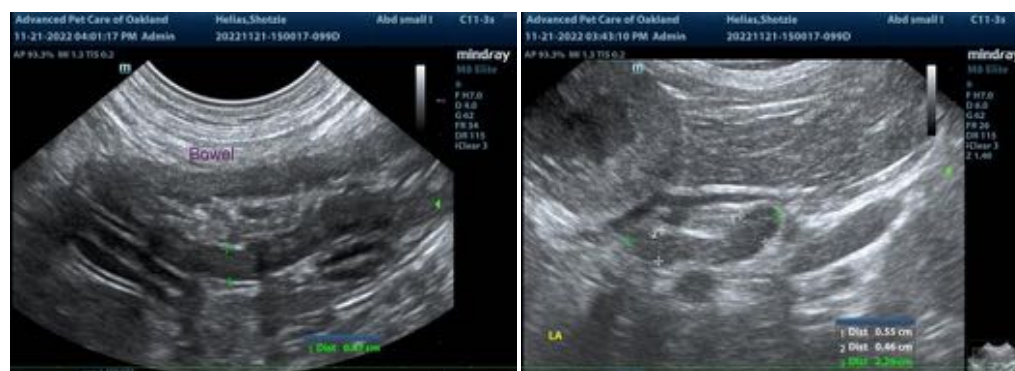
Dr. Sheldon

INVOICE

14240

DATE

11/21/22





PATIENT

Shotzie Helias

SPECIES

Canine

BREED

Terrier

SEX

Female, spayed

AGE

10 Yrs.

WEIGHT

54 lbs.

INTERPRETED BY

Andrea Nicastro, DVM,
Diplomate ACVIM
(Small Animal Internal
Medicine)

**IMAGING
PERFORMED BY**

Dr. Sheldon

HOSPITAL NAME

Advanced PetCare of
Oakland

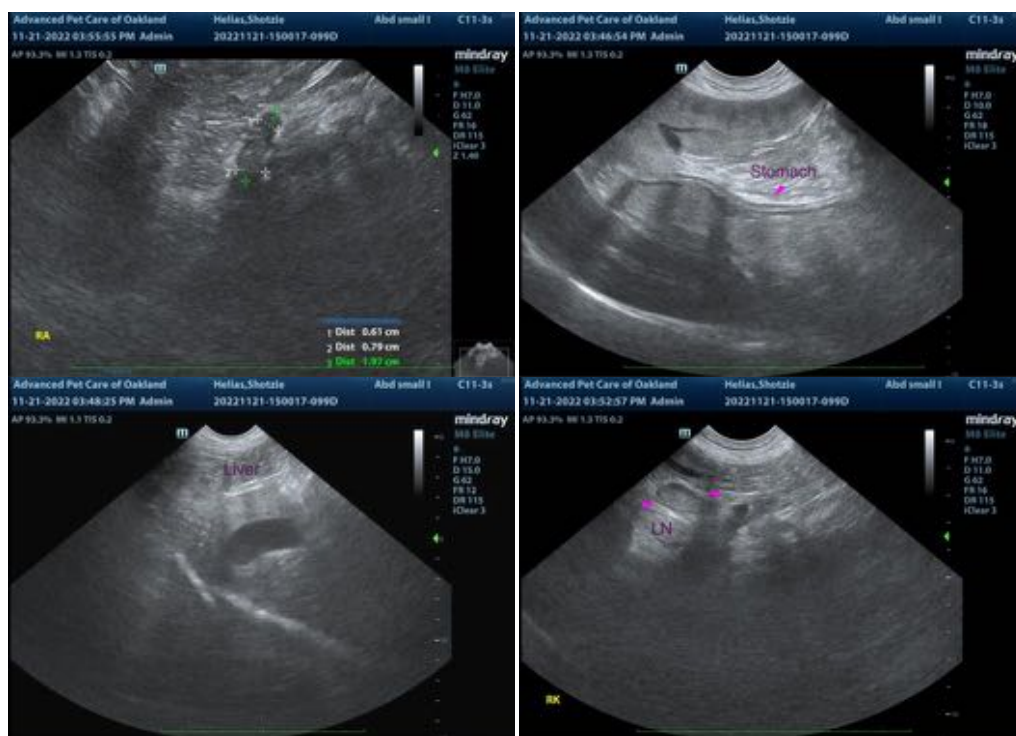
REFERRING VET

Dr. Sheldon

INVOICE

14240

DATE
11/21/22



The information and recommendations provided are based on the images presented by the referring veterinarian/sonographer. No evaluation can be communicated regarding pathology that was not visible in the image/video clips provided.

Thank you for this referral. If the clinical or image interpretation does not parallel your findings or if I can be of any further assistance please contact me.

Andrea Nicastro, MPH, DVM, Diplomate DACVIM (Small Animal Internal Medicine)
info@SonoPath.com